

Content available at: <https://www.ipinnovative.com/open-access-journals>

Indian Journal of Obstetrics and Gynecology Research

Journal homepage: www.ijogr.org

Original Research Article

Cervical fibroid: A diagnostic dilemma and operative challenge – one year study

Sonia Dahiya^{1*}, Pushpa Dahiya², Kirti Saini², Shevata Jain², Vandana Bhuria²,
Krishna Dahiya²¹Dept. of Obstetrics and Gynaecology, Post Graduate Institute of Sciences University of Health Sciences, Rohtak, Haryana, India²Dept. of Obstetrics and Gynaecology, Pandit Bhagwat Dayal Sharma, PGIMS, University of Health Sciences, Rohtak, Haryana, India

ARTICLE INFO

Article history:

Received 01-04-2024

Accepted 27-05-2024

Available online 20-08-2024

Keywords:

Cervical fibroid

Leiomyoma

Intracapsular myomectomy

Morcellation

Leiomyosarcoma

ABSTRACT

Background: Cervical fibroids are very rare, with varying clinical presentations, and account for only 1–2% of cases. Cervical fibroids are enigmatic as they present with varying symptoms and simulate several clinical entities, for instance, a large cervical polyp, incarcerated procidentia, chronic uterine inversion, and the Ca cervix.

Materials and Methods: A two-year retrospective analysis of women diagnosed with cervical leiomyoma was conducted at Obstetrics and Gynaecology department, PGIMS Rohtak (a tertiary care institute in Northern India). A total of 24 cases diagnosed with cervical fibroid (CF) were studied.

Results: 75% of the females had vaginal bleeding, 44.6% had heavy menstrual bleeding, 33.3% had irregular bleeding, and one had postmenopausal bleeding. 41.6% had urinary symptoms; 1.5% complained of vaginal discharge; difficulty in stools (16.6%); and leiomyosarcoma (8.3%). We cannot find a clear demarcation of presenting symptoms between anterior and posterior fibroid. It was discovered that the development of malignancy and bladder and intestinal problems was linked to an increase in CF mass, while severe anaemia and vaginal bleeding were not.

Conclusion: A cervical fibroid is mostly benign, can be present at extremes of age, and its atypical presenting symptoms pose difficulty in diagnosis. Vaginal bleeding and retention of urine are the most common symptoms. Central and supravaginal fibroids are difficult to operate. Proper pre-operative delineation of altered anatomical structure are essential for choosing the correct modality of treatment. In large cervical fibroids, suspected malignancy before surgery and hidden cervical malignancy can coexist.

This is an Open Access (OA) journal, and articles are distributed under the terms of the [Creative Commons Attribution-NonCommercial-ShareAlike 4.0 License](https://creativecommons.org/licenses/by-nc-sa/4.0/), which allows others to remix, tweak, and build upon the work non-commercially, as long as appropriate credit is given and the new creations are licensed under the identical terms.

For reprints contact: reprint@ipinnovative.com

1. Introduction

Uterine fibroids are the most common benign smooth muscle tumour in women of the reproductive age group. Despite having a fairly high frequency of 70%, uterine fibroid only impacts 20–40% of females symptomatically.¹ Ninety-five percent of leiomyomas are found in the uterine corpus; just one to two percent are seen in the cervical

region.² These tumours are estrogen-dependent.³ The cervical fibroid can arise either from the supravaginal or infravaginal portion of the cervix. It may originate from the anterior, posterior, central, or lateral regions.³ Cervical fibroid is classified as type 8 in the FIGO classification of uterine fibroid.⁴ Cervical fibroid may be present with varied symptoms like irregular vaginal bleeding, heavy menstrual bleeding, dysmenorrhea, chronic pelvic pain, and pressure effects caused disturbance in bladder and bowel habits. Cervical leiomyoma can change the shape

* Corresponding author.

E-mail address: soniadahiya2000@gmail.com (S. Dahiya).

of the cervix and cause its lengthening and effacement. It can also cause the uterus to push upwards or the bladder to be drawn up when its size increases, which causes urinary tract infections.⁵ Cervical fibroid may have an impact on a woman's obstetric outcomes because it can result in abortion, infertility, early discomfort, more surgical intervention, and a protracted postpartum recovery. Sometimes it is difficult to reach the diagnosis of cervical fibroid as it mimics various other gynaecological conditions or because of some atypical presentation like polypoidal vaginal mass, incarcerated procidentia, chronic uterine inversion, uterocervical descent, ovarian mass, acute urinary retention, or cervical carcinoma. This study aims to find out how common cervical fibroids are among different ages, where they start, the most common symptom that led women to the hospital, as well as any site-specific symptoms. It also wants to find out if there is a link between size and symptoms, surgical problems, and the development of cancer. How do we differentiate it from the other gynaecological entities mentioned above? What are modalities that help in diagnosis and rule out malignancies?

2. Materials and Methods

A two-year retrospective study was conducted on women with cervical leiomyomas who were admitted to the obstetrics and gynaecology department at PGIMS Rohtak, Haryana. The institute is the pioneer medical tertiary care teaching institute and referral centre of North India, has been established for more than 50 years, and attracts patients from adjoining states. It conducts around 10,000 deliveries annually, with the care of 26 consultants in obstetrics and gynaecology (eight are senior consultants with experience spanning more than 25 years). A retrospective record was analysis of the inpatient surgical registry of from January 2021 to January 2023. All cases were clinically identified with cervical fibroid, initially admitted different and varied symptoms. Some of them admitted in emergency and others were from gynaecology OPD. All cases undergone preoperative routine investigations such as complete blood count, ABO Rh, TSH, LFT, RFT, chest x-ray, ECG and specific investigation also done like USG, MRI. Pre-anaesthetic checkup was done. The women with severe anaemia were transfused with PCV in preoperative period. Later on all cases were operated as elective cases and proven histopathologically as cervical fibroid. Approval was taken from the institution's scientific and ethical committee (UHRSR/RPAC/2024/398).

3. Results

According to the distribution of age (Table 1), 8 (33.3%) women were between 31 and 40 years old, 10 (41.6%) were between 41 and 50 years old, 4 (16.6%) were above 50 years old, one patient was less than 20 years old and one between

21-30 years. So despite presenting in reproductive age, a cervical fibroid can present in extreme age. Four patients were nulliparous; the others (83.3%) were multiparous (Table 1). The most common presenting symptom (Table 1) was vaginal bleeding. 18 (75%) presented with vaginal bleeding. Ten (41.6%) women reported heavy menstrual bleeding with severe anaemia, four (33.33%) complained of irregular bleeding, and two had postmenopausal bleeding mimicking cervical carcinoma (Figure 3). Acute retention of urine was the most common cause of emergency admission in 8 (33.3%), and 10 presented with pain in the abdomen. Other symptoms were 2 (8.33%) with difficulty in passing stool, 2 (8.3%) with foul-smelling discharge and 4 (16.6%) with abdominal mass (Figure 2). With vaginal bleeding as the most common symptom, 50% of females had severe anaemia that required multiple transfusions. An initial investigation included a complete blood count, coagulation profile, renal function test, and viral marker in addition to ultrasonography. After the buildup of the women, further pre-operative investigations were done. In some patients, an MRI was also done for better visualisation of the lateral and posterior areas of the pelvis. MRI offers 100% specificity and 86–92% sensitivity, and it had an accuracy of 97% in the evaluation of probable fibroid.⁶ After a proper workup, women were taken up for surgery.

Table 1: Distribution of women according to age, parity and presenting complaints

Age (years)	No of women	Percentage
Less than 20	1	4.16%
21-30	1	4.16%
31-40	8	33.3%
41-50	10	33.3%
>50	4	16.6%
Parity		
Nulliparous	4	16.65
Multiparous	20	83.3%
Presenting symptoms		
Heavy menstrual bleeding	10	41.6%
Irregular bleeding	8	33.3%
Postmenopausal bleeding	2	8.3%
Acute retention of urine	8	33.3%
Pain in abdomen	10	41.6%
Difficulty in passing stool	2	8.3%
Foul-smelling discharge	2	8.3%
Abdominal mass	4	16.6%
Severe anaemia	12	50%

According to the site of origin (Table 2), 6 (25%) were found originating from the anterior lip of the cervix; out of 6 anterior fibroids, two presented with acute retention of urine and four with vaginal bleeding. Ten (41.6%) were found to be arising from the posterior; six had presented with abnormal vaginal bleeding, two with retention of urine, and two with difficulty in passing stools. Six of them arose from the supravaginal portion of the cervix; one was

huge fibroid presented with abnormal vaginal bleeding and urinary retention later on diagnosed with leiomyosarcoma (Figure 1), the two were degenerated fibroid with foul-smelling discharge, and the one presented as a 24 week's abdominal mass with abnormal vaginal bleeding. Others were presented with vaginal bleeding. Vaginal bleeding is related to all kinds of CF, and retention of urine is also present in the anterior, posterior, and supravaginal fibroids. Four groups were formed based on the size distribution (Table 3) of cervical fibroids (CF): 4 had size 5×5cm, 8 (33.3%) CF had a size between 5-10cm×5-10cm, 10 (41.6%) were between 10-15cm×10-15cm, and two (8.3%) had >15cm×15cm. It was discovered that the development of malignancy and bladder and intestinal problems was linked to an increase in CF mass, while severe anaemia and vaginal bleeding were not. Surgery performed was vaginal myomectomy (Table 4) (Figure 3) in 12 (50%) of cases, and abdominal hysterectomy was done in 8 (33.3%) with indication postmenopausal bleeding, heavy menstrual bleeding, retention of urine with huge fibroid. Examination under anaesthesia and proceed with Laparoscopic myomectomy was performed in two cases to preserve fertility nulliparous woman (Table 4). But laparoscopic power morcellation for myomectomy or hysterectomy should be performed with a tissue containment system only. Morcellation was done only after ruling out the malignancy, as there is a potential risk of spreading malignant cells.⁷ Laparotomy with myomectomy 2, one unmarried female with 24 week size mass, second was huge mass with retention of urine.

Complications encountered during surgery were distorted pelvic anatomy, difficulty in tracing the ureter, trouble in ligation of the uterine artery and mackenrodt's ligament, and chances of injury to neighbouring structures like the bladder, ureter, and rectum. It was found that doing an intracapsular myomectomy before a hysterectomy made the procedure safer and easier.

4. Discussion

Cervical fibroids are rare entities mainly involved in the reproductive age group as they are estrogen-dependent.⁸ The use of hormonal replacement medication, early menarche, late menopause, hyper-estrogenic states, high blood pressure, poor vitamin D levels, obesity, and a family history of fibroids were risk factors.⁹ These are rare, as there is a paucity of smooth muscles in the cervix. Unlike uterine myomas, cervical leiomyomas are solitary.¹⁰ The translocation of chromosomes 12 and 14, deletion of 7q, and trisomy of 12 are the genetic elements involved.¹¹ Most of the women in the present study were between 35 and 50 years of age, which, in accordance with a review of 187 patients, found the average age to be 39.4 years.¹² Cervical fibroid presents mainly with chronic pelvic pain, menstrual irregularities, and dyspareunia. Anterior cervical

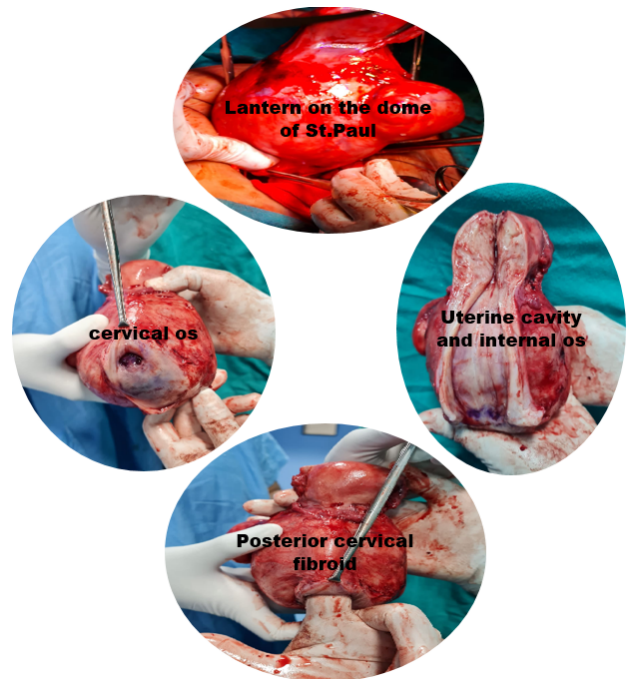


Figure 1: 48yr old woman presented with acute urinary retention with AUB, on HPE leiomyosarcoma was diagnosed

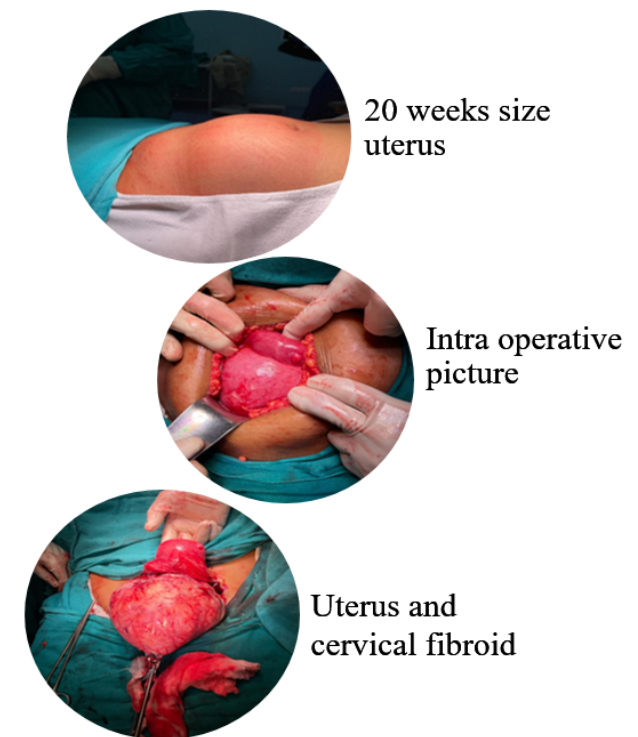


Figure 2: Unmarried 32 years resented with an abdominal mass with urinary retention, p/a 22-week size

Table 2: Distribution according to site of origin and relation of site of origin to symptoms

S. No.	Site of origin	No. of women's	Symptoms	No. of women
1.	anterior	6 (25%)	AUB	6 (25%)
2.	Posterior	10 (41.6%)	Acute retention of urine	4 (16.6%)
			Postmenopausal bleeding	2 (8.3%)
			AUB	6 (25%)
3.	Central	2 (8.3%)	Urinary retention	2(16.6%)
			Difficulty in the passage of stool	2 (8.3%)
4.	Supravaginal	6 (25%)	AUB	2 (8.3%)
			Abdominal mass leiomyosarcoma	4 (25%) - 41

Table 3: Relation of size of cervical fibroid and related symptoms

S. No.	Size	No. of women	Symptoms	No. of women
1.	>5cm×5cm	4	AUB + moderate anaemia	4 (16.6)
2.	5-10cm ×5-10	8(33.4%)	AUB + Severe anaemia	6 (25%)
			Urinary retention	2 (8.3%)
			Difficulty in bladder and bowel	2 (8.3%)
3	10-15cm × 10-15cm	10 (41.66%)	AUB + severe anaemia	8 (38.4%)
			Postmenopausal bleeding urinary retention	2 (8.3%) 4 (16.6%)
4.	>15cm × 15cm	2 (4.76%)	1. Abdominal mass +urinary retention + 2. Abdominal mass +urinary retention + leiomyosarcoma	1 1

Table 4: Types of procedures for cervical fibroid

Name of operation	No of women	Percentage
Laparoscopic myomectomy	2	8.3%
Abdominal Hysterectomy	8	33.3%
Vaginal myomectomy	12	50%
Examination under anaesthesia and proceed with Laparoscopic myomectomy	2	8.3%

fibroids cause urinary retention, and urinary tract infection, whereas rectal symptoms and tenesmus are more common with posterior cervical fibroids. Lateral cervical fibroids are mainly present with vascular obstructions like haemorrhoids and oedema of the legs.^{3,4} In the index study, we cannot find a clear demarcation of presenting symptoms between anterior and posterior fibroid. A review of the literature on cervical fibroid showed that 44% of women presented with AUB, 11% had urinary complaints, 20% had pressure symptoms, and 4% had severe anaemia. This is in contrast to the index study, where 75% of the females had irregular vaginal bleeding associated with heavy menstrual bleeding, 41.6% had urinary symptoms, 50% had severe anaemia, and 16.6% complained of vaginal discharge. It is in contrast to the thought that cervical fibroids are asymptomatic, causing nonspecific symptoms, and less likely to cause vaginal bleeding compared with uterine fibroids.⁵ In two of our cases, the central cervical fibroid “the lantern on the top

of St. Paul’s” was seen because the central cervical fibroid expands the cervix in all directions and the pelvic cavity is filled by the tumour. Elevated on the top of this fibroid uterus was seen looking for a lantern on top of St. Paul. The central fibroid with the appearance of “the lantern on the top of St. Paul’s” was reported by many authors.^{4,8,10,13} Two of our cases presented with a 15×10cm shaggy mass that appeared like cervical carcinoma with complaints of postmenopausal bleeding. Similar cases were reported with postmenopausal bleeding with vaginal mass.^{3,5} In the present study, a nulliparous woman presented with an abdominal mass of size 22 weeks, acute retention of urine masquerading like an ovarian mass (Figure 2), A similar case was reported by Neeru Goel et al., a cervical fibroid misreading ovarian tumour with a huge mass occupying the whole hypogastrium and pain in the abdomen for 6 months.¹⁴ Other differential diagnoses involved cervical polyp, pedunculated submucous fibroid, cervical cancer,

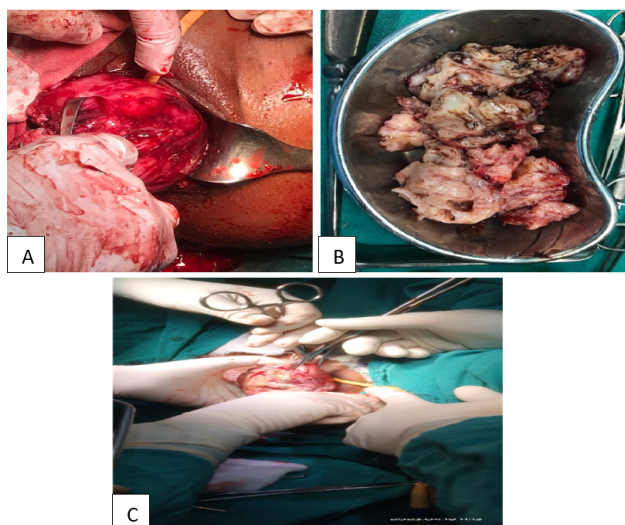


Figure 3: A): Unmarried girl, AUB + urinary retention; B): Removed in piecemeal; C): Postmenopausal bleeding with foul-smelling discharge mimicking cervical carcinoma

chronic uterine inversion, and lymphoma of the cervix. These can be differentiated by abdominal and bimanual examination of the patient, as dimpling of the fundus seen in inversion and also sounding are not possible. While ultrasonography is recommended for a preliminary examination, magnetic resonance imaging (MRI) offers superior visualisation of adjacent tissues and the lateral and posterior regions of the pelvis.^{15,16} It supports both the process of making a diagnosis and selecting a course of treatment. Tumour size, site extensions, and desire for fertility are the factors that come into play while selecting a strategy or modality.

Surgery is a mainstay treatment modality for cervical fibroid. Pre-operatively, GnRH analogues can be given to reduce size and reduce blood loss.³ Adequate blood and blood products should be arranged. Additional consent for the neighbouring structure injury is to be obtained, and proper counselling is to be done regarding the risks and benefits of the procedure to be done. The procedure chosen also depends on the surgeon's choice. Vasopressin can also be used to reduce blood loss. According to Ferrari et al, 23% GnRh was used preoperative and diluted vasopressin/epinephrine was injected in 72% of women intraoperatively. 33% of women in the present study received vasopressin. A vaginal hysterectomy is an ideal approach for small prolapsing fibroid or fibroid with stalk, done in 50% of women in the index study (Table 4). However, abdominal myomectomy can be done laparoscopic or abdominal route is the fertility-preserving procedure of choice for cervical fibroids that are intracervical or deep-rooted within the cervix. The lateral cervical fibroid grows into the broad ligament,

expands it, and increases the chances of injury to the ureter. As cervical fibroids are intracapsular and the ureter and uterine artery are extracapsular, this knowledge makes surgeons do safer procedures despite dangerous ones. So it is safe to do an intracapsular myomectomy (enucleation) before proceeding to hysterectomy.^{13,15} Preoperative stenting and intraoperative delineation of the ureter could be done to prevent ureteric injury. In laparoscopic myomectomy, according to the U.S. Food and Drug Administration 2020 recommendation and ACOG, morcellation is contraindicated if malignancy is not ruled out as there is a potential risk of malignancy spread.⁷ It is not done after the age of 50 and in postmenopausal women. The transvaginal approach for hysterectomy, unless laparoscopically assisted, is considered to be largely inaccessible. Hysterectomy can be done in patients with a completed family, perimenopausal or menopausal women, large-size fibroid, and very severe symptoms.

Interventional radiology techniques can also be used for cervical fibroids, like uterine artery embolization and cervicovaginal artery embolization. It is done in a desire to preserve the uterus and one who can't undergo surgery due to any other morbidity. Its limitations are that it is not cost-effective, may affect future fertility, and there is a paucity of medical literature in this field.^{12,17}

Operative difficulties seen during surgeries are due to distorted pelvic anatomy, poor access, restricted access to the operative field, injury to neighbouring structures like the bladder, rectum, vessels, and ureters, difficulty in identifying the correct cleavage plane, and more chances of blood loss.^{5,12} The occurrence of leiomyosarcoma is rare, only 0.1-0.3%, and very difficult to diagnose preoperatively. In the index study, a 47-year-old woman was admitted with an abdominal mass of 20×15 cm, menorrhagia, and retention of urine, followed by abdominal hysterectomy, and was diagnosed with leiomyosarcoma in the postoperative period. Some serum markers, such as CA-125, LDH, CRP, and D-dimer, may suggest uterine sarcoma but lack specificity. MRI has good tissue resolution, but fibroids with haemorrhage have similar signal intensities. PET-CT has the highest accuracy but is expensive. However, it is important to rule out malignancy in large cervical fibroids.^{12,18}

5. Conclusion

Cervical fibroid is mostly benign, can be present at extremes of age, and its atypical presenting symptoms pose difficulty in diagnosis. Vaginal bleeding and retention of urine are the most common symptoms. Central and supravaginal fibroids are difficult to operate. We cannot find a clear demarcation of presenting symptoms between the anterior and posterior fibroids. Preoperative clinical evaluation, radiological imaging, and proper intraoperative delineation of pelvic anatomy can help in their successful management and anticipating intraoperative complications.

Intracapsular enucleation is the best approach to preventing ureteric injury. Its management is still a challenge for gynaecologists, as they are difficult to operate due to their proximity to the pelvic structure. In large cervical fibroids, always suspect malignancy before moving to surgery, and hidden cervical malignancy can coexist.

6. Authorship Confirmation/Contribution Statement

1. Dr Sonia Dahiya: conceptualization, data curation, scrub data, and maintain research. Formal analysis, methodology, software, visualization, Writing: original draft; writing: review and editing.
2. Dr Pushpa Dahiya: Conceptualization, Supervision, and Validation
3. Dr Kirti Saini: Software (lead); writing; reviewing; and editing (support).
4. Dr. Shaveta Jain: Supervision,
5. Dr. Vandana: Methodology (supporting)
6. Dr. Krishna Dahiya: Supervision

7. Sources of Funding

The research, writing, and publication of this work were all done without any financial assistance from the authors.

8. Conflict of Interest

Acknowledgments

The author is thankful to the Obstetrics and Gynaecology Department, PGIMS, University of Health Science, Rohtak.


References

1. Williams ARW. Uterine fibroids – what’s new? *Version 1 F1000Res*. 2017;6:2109.
2. Vitale SG, Sapia F, Rapisarda AMC, Valenti G, Santangelo F, Rossetti D, et al. Hysteroscopic morcellation of submucous myomas: A systematic review. *Biomed Res Int*. 2017;2017:6848250. doi:10.1155/2017/6848250.
3. Mendiratta S, Dath S, Mittal R, Dath S, Sharma M, Sahai RN. Cervical fibroid: a uncommon presentation. *Int J Reprod Contracept Obstet Gynecol*. 2017;6(9):4161–3.
4. Laughlin-Tommaso SK, Hesley GK, Hopkins MR, Brandt KR, Zhu Y, Stewart EA. Clinical limitations of the International Federation of Gynecology and Obstetrics (FIGO) classification of uterine fibroids. *Int J Gynaecol Obstet*. 2017;139(2):143–8.
5. Zemni I, Aloui M, Saadallah F, Mansouri H. A huge prolapsed cervical leiomyoma: A case report. *Int J Surg Case Rep*. 2023;106:108139. doi:10.1016/j.ijscr.2023.108139.
6. Aluwee S, Kato H, Zhou X, Hara T, Fujita H, Kanematsu M, et al. Magnetic resonance imaging of uterine fibroids: a preliminary investigation into the usefulness of 3D-rendered images for surgical planning. *Springerplus*. 2015;4:384.
7. Oh HK, Park SN, Kim BR. Laparoscopic uncontained power morcellation-induced dissemination of ovarian endodermal sinus tumors: A case report. *World J Clin Cases*. 2021;9(13):3212–8.
8. Borahay MA, Asoglu MR, Mas A, Adam S, Kilic GS. Estrogen Receptors and Signaling in Fibroids: Role in Pathobiology and Therapeutic Implications. *Reprod Sci*. 2017;24(9):1235–44.
9. Yang Q, Ciebiera M, Bariani MV. Comprehensive Review of Uterine Fibroids: Developmental Origin, Pathogenesis, and Treatment. *Endocr Rev*. 2022;13(4):678–719.
10. Wagey FMM, Lengkong R, Wagey FW, Tendean HMM, Wantania JJE, Suparman E, et al. Vaginal myomectomy and Total vaginal hysterectomy on large prolapsed cervical myoma: a case report. *J Med Cases*. 2021;12(7):288–90.
11. Medikare V, Kandukuri LR, Ananthapur V, Deenadayal M, Nallari P. The genetic bases of uterine fibroids; a review. *J Reprod Infertil*. 2011;12(3):181–91.
12. Ferrari F, Forte S, Valenti G, Ardighieri L, Barra F, Esposito V, et al. Current Treatment Options for Cervical Leiomyomas: A Systematic Review of Literature. *Medicina (Kaunas)*. 2021;57(2):92.
13. Acharya N, Singhal S, Agrawal M, Singh N, Verma N. Lantern on Dome of St. Paul’s Cathedral - An Apt Metaphor for a Challenging Leiomyoma. *J Midlife Health*. 2020;11(3):181–4.
14. Goel N, Seth S. An unusual case of cervical fibroid masquerading as ovarian tumor. *J Midlife Health*. 2016;7(3):144–6.
15. Stamatopoulos CP, Mikos T, Grimbizis GF, Dimitriadis AS, Efstratiou I, Stamatopoulos P, et al. Value of magnetic resonance imaging in diagnosis of adenomyosis and myomas of the uterus. *J Minim Invasive Gynecol*. 2012;19(5):620–6.
16. Gupta A, Gupta P, Manaktala U. Varied Clinical Presentations, the Role of Magnetic Resonance Imaging in the Diagnosis, and Successful Management of Cervical Leiomyomas: A Case-Series and Review of Literature. *Cureus*. 2018;10(5):e2653.
17. Bruijn AMD, Adriaansens SJH, Smink M. Uterine Artery Embolization in Women with Symptomatic Cervical Leiomyomata: Efficacy and Safety. *Cardiovasc Intervent Radiol*. 2019;42(3):371–80.
18. Liu J, Wang Z. Advances in the Preoperative Identification of Uterine Sarcoma. *Cancers (Basel)*. 2022;14(14):3517.

Author biography

Sonia Dahiya, Associate Professor  <https://orcid.org/0000-0001-5946-3219>

Pushpa Dahiya, Senior Professor and HOD

Kirti Saini, Junior Resident  <https://orcid.org/0009-0008-1878-2801>

Shevata Jain, Professor  <https://orcid.org/0000-0002-6466-2762>

Vandana Bhuria, Professor  <https://orcid.org/0000-0001-9560-4744>

Krishna Dahiya, Professor

Cite this article: Dahiya S, Dahiya P, Saini K, Jain S, Bhuria V, Dahiya K. Cervical fibroid: A diagnostic dilemma and operative challenge – one year study. *Indian J Obstet Gynecol Res* 2024;11(3):409–414.