

Content available at: <https://www.ipinnovative.com/open-access-journals>

Indian Journal of Obstetrics and Gynecology Research

Journal homepage: [www.ijogr.org](http://www.ijogr.org)

## Case Report

# A case of missed mixed germ cell tumor of ovary in pregnancy

Janice A Pais<sup>1,\*</sup>, Venita Roshal Fernandes<sup>1</sup>, Sujaya V Rao<sup>1</sup>

<sup>1</sup>Dept. of Obstetrics & Gynaecology, Father Muller Medical College, Mangalore, Karnataka, India



### ARTICLE INFO

#### Article history:

Received 16-10-2022

Accepted 21-12-2022

Available online 18-05-2023

#### Keywords:

Germ cell tumor

Yolk sac tumor

Dysgerminoma

Pregnancy with ovarian tumor

### ABSTRACT

**Introduction:** Ovarian germ cell tumor accounts for 18-26% of all ovarian cancers complicating pregnancy. This is a rare case of mixed germ cell tumor of ovary, misdiagnosed antenatally as uterine fibroid.

**Case Report:** A 34-year-old primigravida at 37 weeks + 5 days POG came in latent labor. Term scan showed fibroid of 11x 9cms in posterior wall in lower uterine segment with central cystic area. She underwent emergency LSCS and delivered a male baby weighing 2.005 kg. On exteriorization of uterus, a 10 x 8 cm necrotic mass was present posterior to uterus in rectovaginal space measuring 10 x 8 cm. It was concluded as FIGO Stage IC1 ovarian carcinoma.

Histopathology of the mass showed mixed germ cell tumor: 60% yolk sac tumor and 40% dysgerminoma. MRI done after 2 weeks showed a lesion of 10.4 x 9.5 x 7.3 cm in rectovaginal pouch compressing and displacing the rectum posteriorly and to the left side, also displacing uterus and bladder anteriorly. Left ovary normal, Right ovary not visualized. Hence, she received 4 cycles of chemo comprising cisplatin and etoposide.

After chemo, PET scan showed a lesion of 6.7x 6.2 x 4.2 cm in the rectovaginal area just right to the midline with right ovary not being visualized separately. Hence, she underwent laparoscopic right oophorectomy. Histopathology showed extensive regressive changes with occasional scattered atypical cells with no conclusive evidence of residual tumor. Follow up serum LDH and AFP are within normal limits and advised to follow up once in 3 months to look for any recurrences.

**Conclusion:** Any mass during pregnancy even if found to be benign, should be further evaluated and monitored regularly to reduce the morbidity /mortality to the mother.

This is an Open Access (OA) journal, and articles are distributed under the terms of the [Creative Commons Attribution-NonCommercial-ShareAlike 4.0 License](https://creativecommons.org/licenses/by-nc-sa/4.0/), which allows others to remix, tweak, and build upon the work non-commercially, as long as appropriate credit is given and the new creations are licensed under the identical terms.

For reprints contact: [reprint@ipinnovative.com](mailto:reprint@ipinnovative.com)

## 1. Introduction

Incidence of malignant adnexal masses during pregnancy is 1-8%.<sup>1</sup> Ovarian germ cell tumor accounts for 18-26% of all ovarian cancers complicating pregnancy.<sup>2</sup> Most common component of a mixed germ cell tumor is dysgerminoma followed by endodermal sinus tumor.<sup>3</sup>

We present a rare case of mixed germ cell tumor of ovary, misdiagnosed antenatally as uterine fibroid.

\* Corresponding author.

E-mail address: [paisjanice8464@gmail.com](mailto:paisjanice8464@gmail.com) (J. A. Pais).

## 2. Case Report

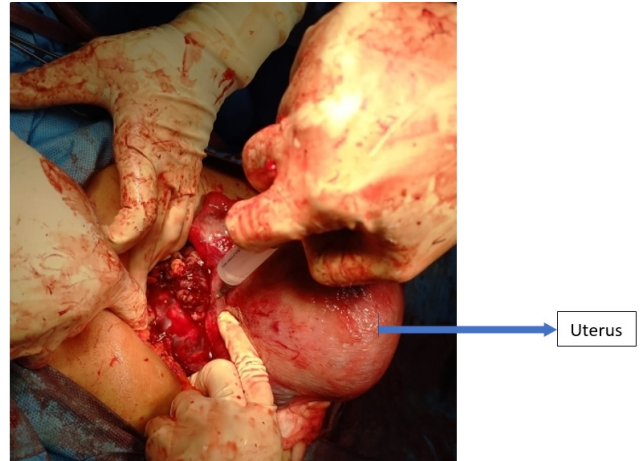
Mrs. X, 34 year old primigravida at 37 weeks gestation presented with lower abdominal pain. Examination showed uterine contractions with breech presentation in labor. Early trimester scans were normal. Growth scan at 33 weeks of gestation showed fibroid in lower uterine segment, and posterior wall of cervix stretched over fibroid. Term obstetric scan at 37 weeks showed fibroid of 11x 9 cms in posterior wall of the lower uterine segment with central cystic area. She underwent an emergency LSCS in view of breech in labor and delivered a male baby weighing 2.005 kg. Intraoperatively on exteriorization of uterus, a 10 x 8

cm necrotic, non-encapsulated mass was seen posterior to uterus in rectovaginal space (as shown in Figures 1 and 2) and mass was sent for histopathology. Frozen section and staging laparotomy could not be done during caesarean section since it was an emergency LSCS done at midnight and diagnosis was not certain. Histopathology of the mass showed mixed germ cell tumor with 60% being yolk sac tumor component (Figure 3) and 40% being dysgerminoma (Figure 4). It was concluded as FIGO Stage IC1 ovarian carcinoma.

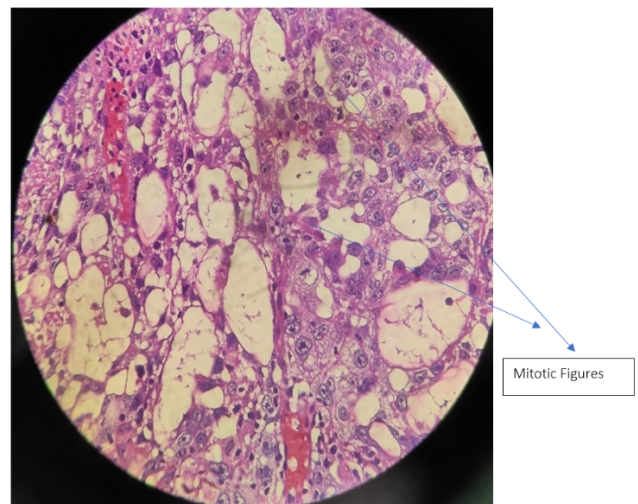
MRI done after 2 weeks showed a lesion of 10.4 x 9.5 x 7.3cm in rectovaginal pouch compressing and displacing the rectum posteriorly and to the left side, also displacing uterus and bladder anteriorly with left ovary normal and right ovary not being visualized. Chest MDCT revealed no metastasis. She received 4 cycles of chemotherapy comprising cisplatin and etoposide over 3 months. Serum AFP and Serum LDH levels were done monthly.(Table 1)

After completion of chemotherapy, PET scan was done which showed a lesion of 6.7x 6.2 x 4.2cm in the rectovaginal area just right to the midline with right ovary not being visualized separately. Hence, she underwent laparoscopic right oophorectomy with right external iliac lymphadenectomy. Histopathology showed extensive regressive changes with occasional scattered atypical cells with no conclusive evidence of residual tumor. Follow up serum LDH and AFP are within normal limits.

She is now on regular follow up with serum LDH and serum AFP once in 3 months to look for any recurrences.



**Fig. 2:** Intraoperative mass found behind the uterus during caesarean section



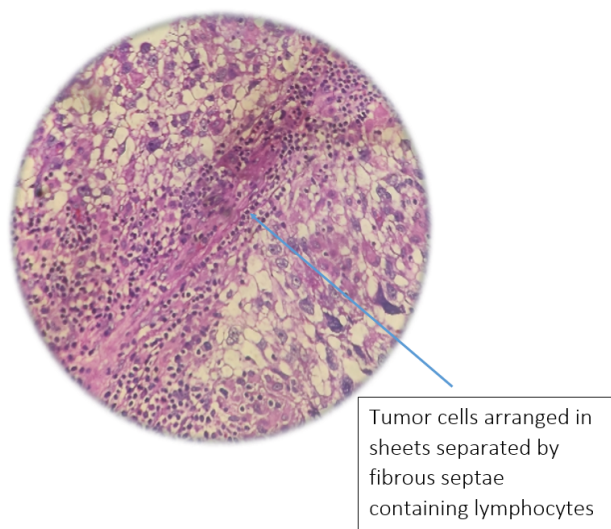
**Fig. 3:** Yolk sac component (Individual tumor cells are large, uniform, polygonal with distinct cell membranes and clear to eosinophilic cytoplasm)



**Fig. 1:** Retroperitoneal mass during caesarean section

**Table 1:** Tumor marker levels

Tumor markers	Pre-chemotherapy	Post chemotherapy
LDH (U/L)	612	501
AFP (ng/ml)	2033	60.75
BETA HCG (mIU/ml)	0.994	
CA125	Normal	



**Fig. 4:** Dysgerminoma component

### 3. Discussion

Most adnexal masses during pregnancy are detected in the first trimester by antenatal ultrasonography and resolve spontaneously. Careful evaluation of persisting adnexal masses is required to have definitive diagnosis.<sup>3</sup>

This is a rare case of mixed germ cell tumor of ovary, misdiagnosed antenatally as uterine fibroid.

Ultrasonography is the preferred imaging technique and MRI can be used for further evaluation.<sup>4</sup>

International ovarian tumor analysis (IOTA) simple rules can be used when malignancy is suspected in an adnexal mass in pregnancy.<sup>5</sup>

CA125 has limited utility during pregnancy as it rises in other benign conditions and is physiologically higher during the first trimester, but can be used as a baseline for follow up in suspected ovarian malignancy. AFP, Beta HCG and LDH are too normally elevated in pregnancy.<sup>6</sup>

Germ cell tumors are usually present at an early stage during pregnancy. Laparotomy is preferably planned for 2nd trimester beyond 14-16 weeks gestation. Unilateral salpingo-oophorectomy and surgical limited staging is appropriate.<sup>3</sup> If pelvic peritoneum and POD cannot be reliably examined during surgery because of enlarged uterus, restaging surgery should be planned post-partum.<sup>7</sup>

Studies have also found laparoscopy to be safer in management of adnexal mass during pregnancy.<sup>8,9</sup>

Any adnexal mass during pregnancy even if found to be benign, should be further evaluated with MRI and tumor

markers and monitored regularly to reduce the morbidity and mortality to the mother.

### 4. Source of Funding

None.

### 5. Conflict of Interest

None.

### References

1. Sunder A, Darwish B, Darwish A, Nagaraj V, Dayoub NM. Adnexal Masses In Pregnancy: An overview. *Ginekologia i Położnictwo*. 2022;17(1):1–7.
2. Kodama M, Grubbs BH, Blake EA, Cahoon SS, Murakami R, Kimura T, et al. Feto-maternal outcomes of pregnancy complicated by ovarian malignant germ cell tumor: a systematic review of literature. *Eur J Obstet Gynecol Reprod Biol*. 2014;181:145–56.
3. Berek JA. Berek and Hacker's. and others, editor. Philadelphia(USA): Wolters Kluwer Health; 2021.
4. Tumor marker levels during the chemo cycles. Available from: [https://www.uptodate.com/contents/adnexal-mass-in-pregnancy?search=ovarian%20cancer%20in%20pregnancy&source=search\\_result&selectedTitle=2~150&usage\\_type=default&display\\_rank=2](https://www.uptodate.com/contents/adnexal-mass-in-pregnancy?search=ovarian%20cancer%20in%20pregnancy&source=search_result&selectedTitle=2~150&usage_type=default&display_rank=2).
5. Auekitrungrueng R, Tinnangwattana D, Tantipalakovorn C, Charoenratana C, Lerthiranwong T, Wanapirak C, et al. Comparison of the diagnostic accuracy of International Ovarian Tumor Analysis simple rules and the risk of malignancy index to discriminate between benign and malignant adnexal masses. *Int J Gynaecol Obstet*. 2019;146(3):364–9.
6. Sarandakou A, Protonotariou E, Rizos D. Tumor markers in biological fluids associated with pregnancy. *Crit Rev Clin Lab Sci*. 2007;44(2):151–78.
7. Ishioka SI, Hayashi T, Endo T, Baba T, Honma H, Saito T. Advanced epithelial ovarian carcinoma during pregnancy. *Int J Clin Oncol*. 2007;12(5):375–8.
8. Moore RD, Smith WG. Laparoscopic management of adnexal masses in pregnant women. *J Reprod Med*. 1999;44(2):97–100.
9. Chen L, Ding J, Hua K. Comparative analysis of laparoscopy versus laparotomy in the management of ovarian cyst during pregnancy. *J Obstet Gynaecol Res*. 2014;40(3):763–9.

### Author biography

**Janice A Pais**, Post Graduate <https://orcid.org/0000-0003-1783-141X>

**Venita Roshal Fernandes**, Senior Resident <https://orcid.org/0000-0002-4245-8357>

**Sujaya V Rao**, Professor <https://orcid.org/0000-0002-2310-5396>

**Cite this article:** Pais JA, Fernandes VR, Rao SV. A case of missed mixed germ cell tumor of ovary in pregnancy. *Indian J Obstet Gynecol Res* 2023;10(2):214-216.