

Content available at: <https://www.ipinnovative.com/open-access-journals>

Indian Journal of Obstetrics and Gynecology Research

Journal homepage: [www.ijogr.org](http://www.ijogr.org)

## Case Report

# Low-grade endometrial stromal sarcoma: differential with uterine leiomyoma: A rare case report

Kafil Akhtar<sup>1,\*</sup>, Saba Shakil<sup>1</sup>, Mazhar Fahim<sup>1</sup>, Mohammad Adil<sup>1</sup>

<sup>1</sup>Dept. of Pathology, Jawaharlal Nehru Medical College, Faculty of Medicine, Aligarh Muslim University, Aligarh, Uttar Pradesh, India



## ARTICLE INFO

### Article history:

Received 07-07-2022

Accepted 21-12-2022

Available online 18-05-2023

### Keywords:

Endometrial stromal tumor

Sarcoma

Uterine leiomyoma

Immunohistochemistry

## ABSTRACT

Endometrial stromal tumors are extremely rare uterine malignancy, mainly among young females. Herein, we report a case of low-grade endometrial stromal tumor in a 19-year-old women who presented with the non-specific symptoms of lower abdominal pain, swelling and vaginal bleeding similar to the uterine leiomyoma. Ultrasound finding showed bulky uterus with multiple fibroid and degenerative changes. Contrast enhanced computed tomography (CECT) displayed diffusely enlarged uterus with heterogenous enhancement of the solid cystic mass with normal bilateral tubes and ovary. Considering the patient in the reproductive age group and her fertility status, she was operated with surgical subtotal hysterectomy. Histopathological examination and immunohistochemistry confirmed the diagnosis of Low-Grade Endometrial Stromal Sarcoma (LG-ESS). Patient was closely followed up for recurrence. Endometrial Stromal Sarcoma (ESS) should be included in the differential diagnosis of uterine leiomyoma to avoid recurrence of the lesion.

This is an Open Access (OA) journal, and articles are distributed under the terms of the [Creative Commons Attribution-NonCommercial-ShareAlike 4.0 License](https://creativecommons.org/licenses/by-nc-sa/4.0/), which allows others to remix, tweak, and build upon the work non-commercially, as long as appropriate credit is given and the new creations are licensed under the identical terms.

For reprints contact: [reprint@ipinnovative.com](mailto:reprint@ipinnovative.com)

## 1. Introduction

Endometrial stromal tumors (ESTs) are rare uterine mesenchymal tumors, accounting around 20% of all uterine sarcomas.<sup>1</sup> Mostly they are composed of cells that resemble proliferative-type endometrial stromal cells.<sup>2</sup> According to the latest WHO 2020 classification, ESTs have been divided into 4 categories: Endometrial Stromal Nodule (ESN), Low-Grade Endometrial Stromal Sarcoma (LG-ESS), High Grade Endometrial Stromal Sarcoma (HG-ESS) and Undifferentiated Uterine Sarcoma (USS).<sup>3</sup>

ESTs usually affects younger female as compared with other uterine tumors.<sup>3</sup> They typically occur in the reproductive or postmenopausal age groups and the mean age is 42-58 years.<sup>3</sup> They have a non-specific presentation (vaginal bleeding, enlarged uterus, and pelvic pain/pressure)

or are an incidental finding.<sup>4</sup>

## 2. Case Report

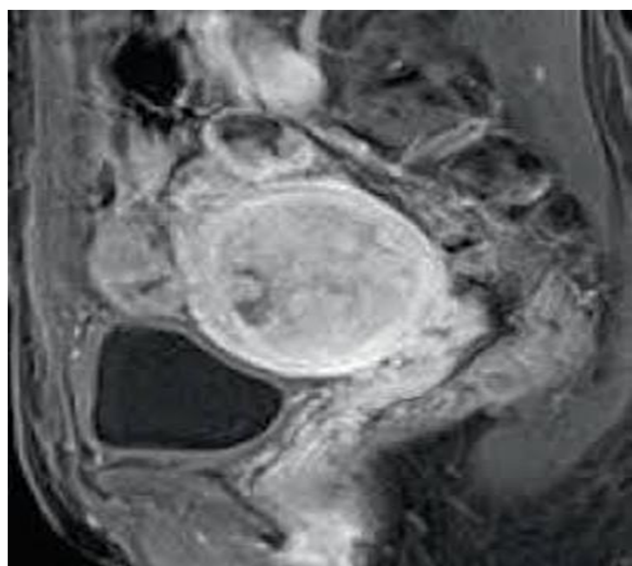
A 19-year old unmarried female patient presented to the Obstetrics & Gynecology OPD with the history of lower abdominal pain, swelling and excessive vaginal bleeding. On physical examination, she was found to have pallor and lower abdominal mass. Uterus was enlarged to 26 week size and soft in consistency. Vitals were stable and her past history was unremarkable.

Laboratory investigations showed hemoglobin 7 gm/dl. Other test findings such as total leukocyte count, differential leukocyte count and platelet count were within normal limit. Tumor markers and hormone levels were also within normal limit. Patient was referred to the radiology department with a probable diagnosis of Leiomyoma.

\* Corresponding author.

E-mail address: [drkafilakhtar@gmail.com](mailto:drkafilakhtar@gmail.com) (K. Akhtar).

Colposcopy displayed normal findings. Chest X-ray showed no active pleuro-parenchymal pathology. Pelvic Ultrasound showed bulky uterus with multiple hyperechoic solid mass (fibroid) with degenerative changes. Bilateral adnexa were normal and no free fluid in the pouch of Douglas. Contrast-enhanced computed tomography (CECT) of the abdomino-pelvic region revealed an enlarged uterus, measuring 15x14x10.5cm with well-defined uterine border and heterogenous enhancement of the solid cystic mass with normal bilateral tubes and ovary (Figure 1).

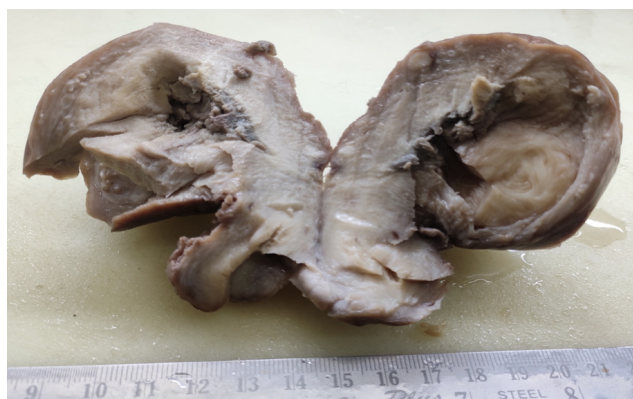

**Fig. 1:** Contrast-enhanced computed tomography (CECT) of the abdomino-pelvic region revealed an enlarged uterus, measuring 15x14x10.5cm with well-defined uterine border and heterogenous enhancement of the solid cystic mass

A provisional diagnosis of uterine leiomyoma was made based on clinical history and imaging. Two unit of blood was transfused preoperatively. As patient was young and unmarried and to conserve her fertility, she was operated with surgical subtotal hysterectomy without salpingectomy, with sparing of cervix, both tubes and ovaries to conserve her reproductive status considering her young age. Pelvic lymph nodes were not enlarged. Post operative period was uneventful.

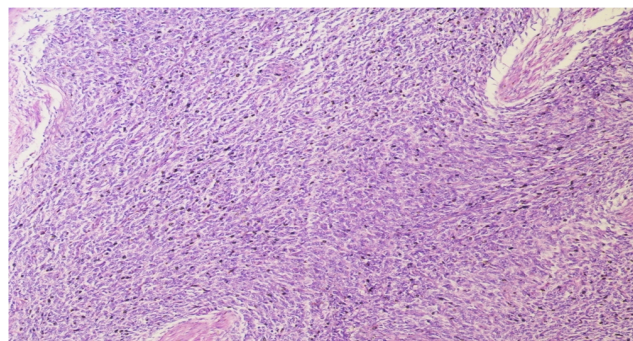
Gross specimen of uterus measured 14x14x10cm, with bosselated and nodular outer surface. Cut section revealed solid to cystic, necrotic and haemorrhagic areas. (Figure 2).

Hematoxylin and eosin (H&E) stained section showed irregular cellular islands, composed of monotonous oval to spindle cells with minimal cytologic atypia, vesicular to fine granular chromatin and scant cytoplasm. Delicate capillary network was seen in the stroma. Foci of mitotic activity, focal necrosis and myometrial invasion by tumor cells were also seen. There was no evidence of lymphovascular invasion. No infiltration of tumor cells were seen in the

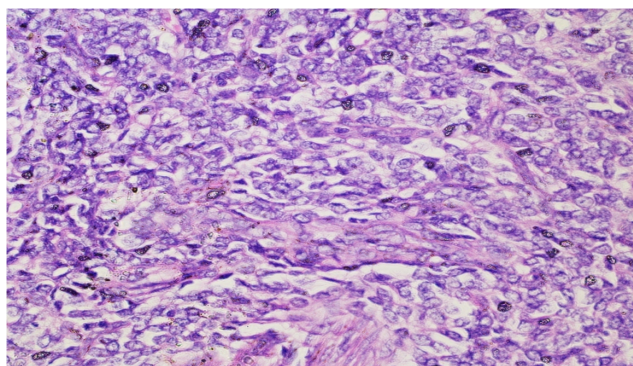


**Fig. 2:** Cut section of the uterus revealed solid to cystic, necrotic and haemorrhagic areas

adjacent adipose tissue (Figures 3 and 4).



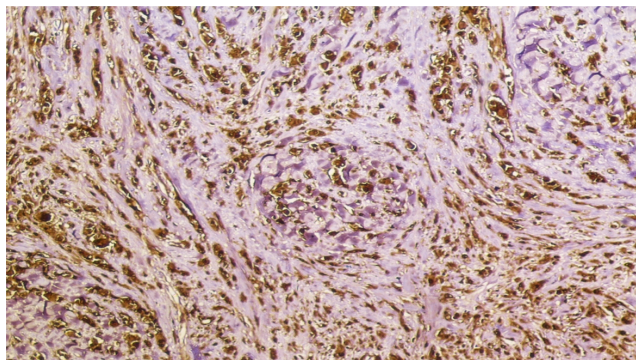
**Fig. 3:** Section shows irregular cellular islands, composed of monotonous oval to spindle cells with minimal cytologic atypia. Delicate capillary network was seen in the stroma. Hematoxylin and Eosin x 10X



**Fig. 4:** Section shows irregular cellular islands, composed of monotonous oval to spindle cells with minimal cytologic atypia, vesicular to fine granular chromatin and scant cytoplasm with delicate capillary network. Hematoxylin and Eosin x 40X

Additional immunohistochemistry studies revealed positive diffuse cytoplasmic staining for vimentin (Figure 5)

and strong membranous positivity for CD10 in tumor cells.



**Fig. 5:** Immunohistochemistry studies revealed positive diffuse cytoplasmic staining for vimentin. IHC Vimentin x40X

The tumor cells stained negative for estrogen receptors (ER) or progesterone receptors (PR). A diagnosis of Low-Grade Endometrial Stromal Sarcoma (LG-ESS) was made based on these pathological findings. The patient was thoroughly examined for tumor invasion and distant metastasis. On Magnetic Resonance Imaging (MRI), there was no evidence of residual tumor in the uterus and Positron Emission Tomography (PET) and Computed Tomography (CT) scan also showed no lymph node metastasis or distant metastasis.

Considering the risk of postoperative recurrence, she was given hormonal therapy with injection leuprolide acetate, subcutaneously every 28 days for 6 months and high-dose progesterone therapy for 1 year. Thereafter, she was followed annually. 3 years have elapsed since the surgery with no evidence of recurrence till date.

### 3. Discussion

Endometrial Stromal Sarcoma (ESS) is a rare diagnosis in a patient presenting as uterine leiomyoma with non-specific symptoms. It is an uncommon and highly malignant subset of neoplasm arising from the endometrial stroma.<sup>4</sup> Tumor in this group infiltrate the stroma with a wide range of atypia and numerous mitoses. They can be subdivided into Low-grade ESS and High grade ESS based on cell morphology and mitotic count.<sup>5</sup> Irregular or excessive uterine bleeding is one of the commonest reason for adolescents and young female to present at hospitals.<sup>5</sup> In this report, we discussed a case of LG-ESS in a 19-year old young female who presented with lower abdominal pain, swelling and excessive vaginal bleeding similar to the presenting features of uterine leiomyoma. Low-grade ESS patients are usually younger with a mean age of 52 years as compared to the other uterine sarcomas.<sup>6</sup>

Often they have indolent clinical behaviour and show late recurrence.<sup>7</sup> ESS has malignant potential and can metastasize to the vagina, fallopian tubes, ovaries, bladder

and ureters.<sup>4</sup> Distant metastasis to lung, heart, and other sites has also been reported.<sup>8,9</sup>

They are difficult to diagnose preoperatively and around 75.0% cases are misdiagnosed as benign uterine fibroid.<sup>4</sup> Ultrasound and CT imaging in our case was not supportive as the findings were suggestive of uterine leiomyoma. Previously reported cases also revealed that LG-ESS is difficult to distinguish from uterine leiomyoma and endometrial polyp.<sup>10</sup> Sometimes, it is only diagnosed after histopathological examination and immunohistochemistry.<sup>11</sup> Macroscopically, LG-ESS may show well defined or ill defined border with myometrial or parametrial involvement. Areas of cystic degeneration, necrosis and hemorrhage can also be seen.<sup>12</sup> Microscopically, LG-ESS shows typical involvement of the endometrial stromal cells and infiltration into the myometrium with frequent lymphovascular invasion.<sup>13</sup> Standard treatment for LG-ESS is total hysterectomy and bilateral salpingo-oophorectomy. Subtotal hysterectomy without salpingectomy was performed in our case, with sparing of cervix, both tubes and ovaries to conserve her reproductive status considering her young age. Ovarian preservation or fertility preservation may be considered in younger patients, as was employed in our case.<sup>7</sup>

Patient with LG-ESS has good prognosis in the early stages (5-year survival rate, 100%) and usually do not require adjuvant therapy after surgical resection.<sup>14</sup> Postoperative high-dose progesterone therapy helps in reducing the risk of recurrence and hence, used as an adjuvant therapy.<sup>15</sup>

### 4. Conclusions

Endometrial Stromal Sarcoma (ESS) is very rare in a 19-year-old. It is important to diagnose it early and treat accordingly to conserve the fertility status of the patient. Furthermore, this case report highlights a very rare presentation of ESS, which should be included in the differential diagnosis of uterine leiomyoma, though rare.

### 5. Source of Funding

None.

### 6. Conflict of Interest

None.

### References

1. Amant F, Tuyaerts S. Endometrial stromal sarcomas: a revision of their potential as targets for immunotherapy. *Vaccines (Basel)*. 2018;6(3):56.
2. Akaev I, Yeoh CC, Rahimi S. Update on Endometrial Stromal Tumors of the uterus. *Diagnostics (Basel)*. 2021;11(3):429.
3. Puliyath G, Nair MK. Endometrial stromal sarcoma: A review of the literature. *Indian J Med Paediatr Oncol*. 2012;33(1):1–6.

4. Jain R, Batra S, Ahmad A, Elahi AA, Gupta M, Saith P. Low Grade Endometrial Stromal Sarcoma: A Case Report. *Iran J Med Sci.* 2015;40(1):81–4.
5. Christopher MF. Tumors of the Female Genital Tract-Diagnostic Histopathology of Tumors. 3rd ed. Churchill Livingstone: Elsevier Publishers; 2007. p. 667–8.
6. Chan JK, Kavar NM, Shin JY, Osann K, Chen LM, Powell CB, et al. Endometrial Stromal Sarcoma: a population-based analysis. *Br J Cancer.* 2008;99(8):1210–5.
7. Amant F, Coosemans A, Debiec-Rychter M, Timmerman D, Vergote I. Clinical management of uterine sarcomas. *Lancet Oncol.* 2009;10(12):1188–98.
8. Matsuura Y, Yasungag K, Kuroki H, Inagaki H, Kshimura M. Low-grade endometrial stromal sarcoma recurring with multiple bone and lung metastases: report of a case. *Gynecol Oncol.* 2004;92(3):995–8.
9. Aubry MC, Myers JL, Colby TV, Leslie KO, Tazelaar HD. Endometrial Stromal Sarcoma Metastatic to the lung: A detailed analysis of 16 patients. *Am J Surg Pathol.* 2002;26(4):440–9.
10. Matsukawa H, Ota N, Nishioka K, Noguchi T, Iwahashi N, Mabuchi Y, et al. Low-grade endometrial stroma sarcoma in a young women diagnosed after resection of endometrial polyp-like lesions: A case report. *Mol Clin Oncol.* 2021;15(5):236.
11. Hoang L, Chiang S, Lee CH. Endometrial stromal sarcomas and related neoplasms: New developments and diagnostic considerations. *Pathology.* 2018;50(2):162–77.
12. Park GE, Rha SE, Oh SN, Lee A, Lee KH, Kim MR, et al. Ultrasonographic findings of low-grade endometrial stromal sarcoma of the uterus with a focus on cystic degeneration. *Ultrasonography.* 2016;35(2):124–154.
13. Rh A, Rouzbahman M. Endometrial stromal tumors revisited: an update based on the 2014 WHO classification. *J Clin Pathol.* 2015;68:325–357.
14. Kaler AK, Jena M, Gandhi N, Shantha B. Endometrial stromal sarcoma of the uterus: a rare entity. *Int J Health Sci and Res.* 2012;2(6):119–22.
15. Hussein GE, Bareedy NA, Mourad WA, Mohamed G, Shoukri M, Subhi J, et al. Prognostic factors and treatment modalities in uterine sarcoma. *Am J Clin Oncol.* 2002;25(3):256–60.

### Author biography

**Kafil Akhtar**, Professor  <https://orcid.org/0000-0002-3482-1195>

**Saba Shakil**, Resident

**Mazhar Fahim**, Junior Resident

**Mohammad Adil**, Resident

**Cite this article:** Akhtar K, Shakil S, Fahim M, Adil M. Low-grade endometrial stromal sarcoma: differential with uterine leiomyoma: A rare case report. *Indian J Obstet Gynecol Res* 2023;10(2):217-220.