



## Case Report

# Spontaneous uterine rupture due to cornual placenta percreta in unscarred uterus: A rare & challenging case

Shelley Moudgil<sup>1</sup>, Monica Karpa<sup>1</sup>, Kamal Singh<sup>1,\*</sup>, Anu Devi<sup>1</sup>, Aahwani Verma<sup>1</sup>

<sup>1</sup>Dept. of Obstetrics & Gynaecology, Dr. Rajendra Prasad Government Medical College Kangra, Tanda, Himachal Pradesh, India



### ARTICLE INFO

#### Article history:

Received 08-10-2019

Accepted 13-01-2020

Available online 21-02-2020

#### Keywords:

Placenta percreta

Unscarred uterus

Peripartum hysterectomy

### ABSTRACT

Spontaneous uterine rupture in unscarred uterus is a rare and catastrophic complication of pregnancy which can occur at any stage. The placental implantation at cornual end leading to placenta percreta, least common type of placenta accreta syndrome which causes uterine rupture in this case. Placenta accreta is defined as the abnormal attachment or invasion of the whole placenta or parts of it to the underlying musculature. It is a rare clinical condition with incidence ranging from 1: 500 to 1: 93000 deliveries. It is potentially life-threatening for both the mother and the fetus. Adherent placenta accounts for 7-10% of maternal mortality cases worldwide. Prenatal diagnosis seems to be a key factor in optimizing maternal outcome. Both ultrasonography & MRI have good sensitivity for prenatal diagnosis of placenta accreta. In this report we present the case of a G3P1011 with no known risk factors for adherent placenta who was diagnosed to have uterine rupture due to placenta percreta at cornual end leading to haemorrhagic shock. There was gross haemoperitoneum with evidence of uterine rupture on exploration which further proceeded with caesarean section & peripartum hysterectomy. Her postoperative period was uneventful. This case report emphasizes the importance of keeping spontaneous uterine rupture due to placenta percreta in the differential diagnosis of pregnant patient presenting with pain abdomen, hypovolumic shock and intrauterine death even in unscarred uterus.

© 2020 Published by Innovative Publication. This is an open access article under the CC BY-NC-ND license (<https://creativecommons.org/licenses/by/4.0/>)

## 1. Introduction

Placenta accreta is defined as the abnormal attachment or invasion of the whole placenta or parts of it to the underlying musculature. Histopathologically placenta accreta is characterized by a partial or complete absence of decidua basalis resulting in placental villi being attached to or invading the myometrium. It is a rare catastrophic condition with incidence ranging from 1: 500 to 1: 93000 deliveries.<sup>1</sup> Although known from ancient time but the 1st case in modern literature comes from Plater in 1588. The incidence had increased 10 fold in last 50 years parallel to the increased in caesarean rate. The incidence was estimated in 1980 to be one in 2500 deliveries; in 2012 as high as one in 533(ACOG).

It may be classified according to its penetration into uterine layers: placenta accreta (reaching myometrium without penetration: 78-80%), increta (penetrates the myometrium: 15%) and percreta (reaches the uterine serosa, can penetrate it and invade the neighbouring organs: 5 to 7%).<sup>2</sup> Of these varieties, placenta percreta is by far the most severe but the least common one. Adherent placenta accounts for 7-10% of maternal mortality cases worldwide.<sup>3</sup>

The exact etiology of placenta accreta not known but women who are considered at risk of a re those with placenta previa, previous caesarean delivery, advancing maternal age ( $\geq 35$  yrs), second-trimester serum levels of AFP and free  $\beta$ -hCG greater than 2.5 multiples of median, previous uterine surgery, previous uterine curettage, previous myomectomy, UAE, thermal ablation, previous trophoblastic disease, uterine anomalies, smoking, multiparity and high gravidity.<sup>4</sup>

\* Corresponding author.

E-mail address: [singh.kamal396@gmail.com](mailto:singh.kamal396@gmail.com) (K. Singh).

Adherent placenta mostly diagnosed at the time of delivery, however may be diagnosed in antenatal period by USG, colour Doppler and MRI in patients who are at high risk for abnormal placentation. The cornerstone treatment of placenta accreta is surgery but individualisation of patients is to be done.

Here we present a case of 25 years old patient with no risk factors & diagnosed spontaneous uterine rupture with placenta percreta attached at cornual end intraoperatively. This case report aims to contribute the insight and knowledge of this rare complication of pregnancy.

## 2. Case Report

A 25 years old G3P1011 patient was referred to our hospital at POG 31 weeks + 1 day with chief complaints of severe pain abdomen since last 12-14 hours. Her antenatal period was uneventful prior to admission. She had previously normal vaginal delivery and one spontaneous abortion without any history of uterine curettage. Her past medical and surgical history was not significant. On examination, there was significant pallor (clinically 5-6 gm/dl), Pulse rate was 126 bpm, Respiratory rate was 20 breaths/min & B.P. was 80/50 mmHg. On per abdomen examination, a abdomen was distended, with rebound tenderness and evidence of free fluid in abdomen. Height of uterus, uterine tenderness and presentation could not be ascertain. Fetal heart sounds not audible. On per speculum examination os closed, cervical length 3cm, without any leakage or bleeding.

Baseline investigations & sample for blood grouping and cross match was sent & meanwhile patient was resuscitated. There after USG was done showing gross ascites with free fluid in morrison's pouch, spleno-renal pouch, POD. There was evidence of discontinuity in the right anterolateral wall of uterus & underlying placenta suggestive of uterine rupture with intrauterine fetal death (Figure 1). Patient was taken up for emergency exploratory laparotomy proceed under general anesthesia.

On exploration, there was approximately 2.5 litres of blood in peritoneal cavity with evidence of discontinuity of uterine wall and tearing of overlying vessels over right cornua. A dead pre-term male baby was extracted out by LSCS, weighing 1.7 Kg without any gross anomaly. Uterus was exteriorized. The fundal and right cornua of the uterus appeared to be bulging, spongy & haemorrhagic (Figures 2 and 3). Placenta appeared to be invading upto serosa with uterine laceration and there was active bleeding (ooze) from vessel crossing over site of placenta favouring the diagnosis of placenta percreta. Decision for peripartum hysterectomy was taken. On cut section, placenta was morbidly adherent (Figure 4) on right fundo-cornual end reaching upto the serosa with uterine laceration. Total estimated blood loss was around 3 litres. Intra-operatively three units of whole blood was given. One unit of whole blood, two units of FFP's & one unit of PC was given in

post-operative period. Post-operative period was uneventful & patient was discharged on day 10 after suture removal. Histopathological examination confirmed the diagnosis of placenta percreta.

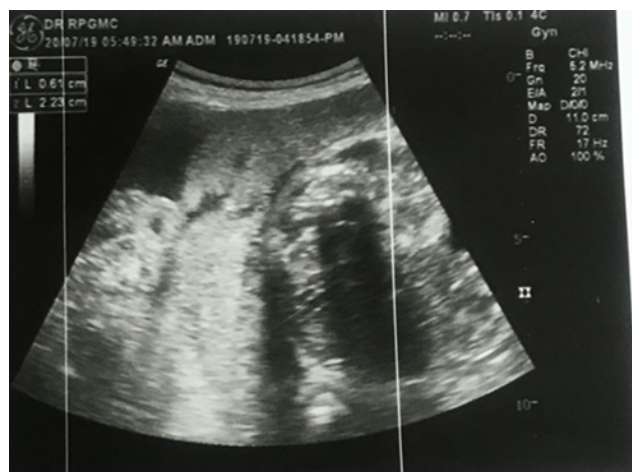

Fig. 1: USG showing discontinuity of uterine wall

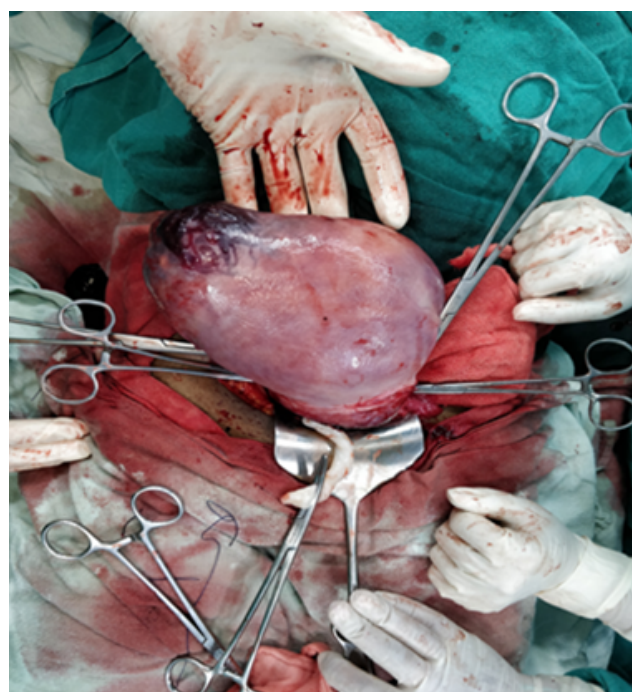
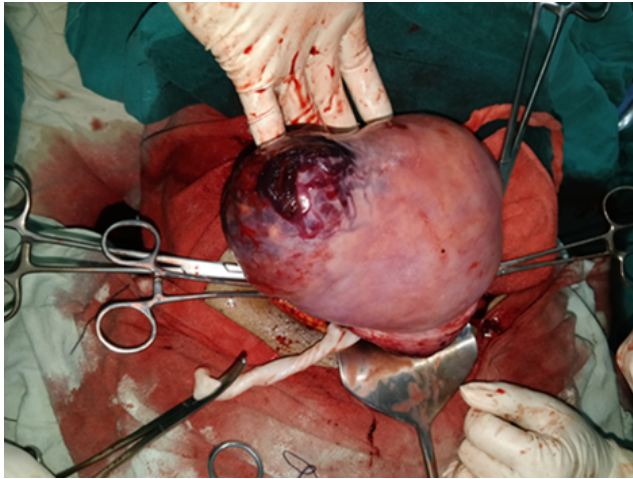


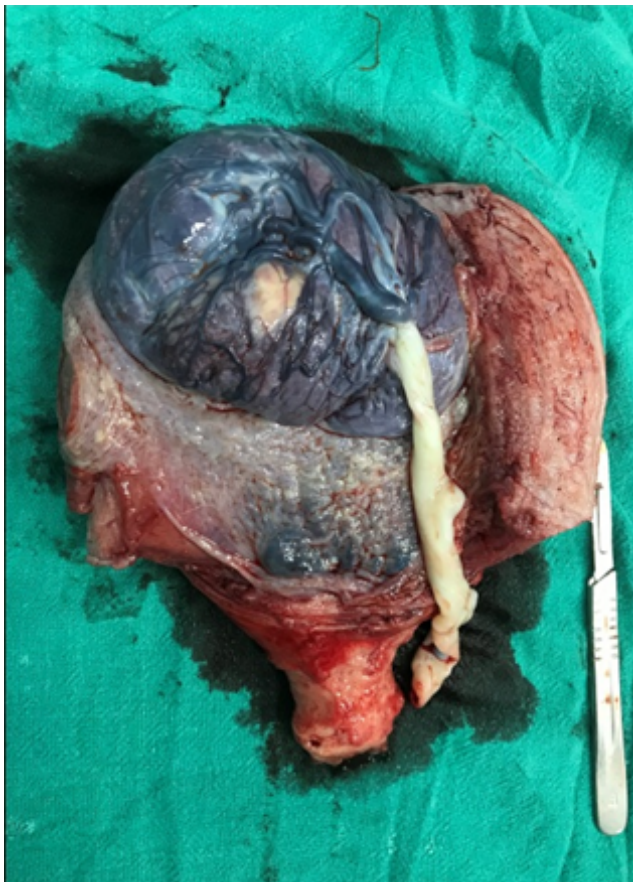Fig. 2: Uterus with placenta in situ showing bulging of rt cornual end

## 3. Discussion

Spontaneous uterine rupture in unscarred uterus is a rare and unexpected complication of pregnancy which had catastrophic effect on mother as well on fetus. The reported incidence of uterine rupture without previous surgery is



**Fig. 3:** Rt cornual end bulged with uterine laceration



**Fig. 4:** Cut section of uterus showing adherent placenta at fundocornual end

1: 8000 to 1:15,000 deliveries. The major risk factors for spontaneous uterine rupture are congenital uterine anomalies, intrauterine infection, placenta percreta or cornal pregnancy.

In our patient, there was no attributable risk factor leading to uterine rupture, however, cornual attached placenta percreta most likely cause of spontaneous rupture in unscarred uterus leading to caesarean hysterectomy. The possible mechanism may be myometrial weakness by previous pregnancy and abnormal implantation in this pregnancy. Adherent placenta is becoming an increasingly common indication for peripartum hysterectomy, rising from 5.4% to 46.5%.<sup>5</sup> The incidence is rising primarily because of the rise in caesarean delivery rates. Placenta percreta is the most extreme form of placenta accreta with a 5 – 7 % incidence among all placenta accrete cases.<sup>2</sup>

Pathologically, there is a defect of deciduas basalis and absence of Nitabuch's fibrinoid layer which results in penetration of villi into the myometrium (increta) or up to the serosa (percreta).

Placenta accreta or percreta is usually diagnosed intraoperatively during caesarean section done for placenta previa. Placenta percreta may clinically present as acute abdomen pain or hemorrhagic shock as in our case or in vaginal delivery as non separation of placenta, heavy vaginal bleeding and shock.

The management of placenta accreta is either caesarean hysterectomy or conservative treatment, i.e. leaving the placenta in the uterine cavity and this decision is made intraoperatively based on the damage to the uterus, hemodynamic stability and desire for future child bearing. Caesarean hysterectomy is probably the preferable treatment and conservative management should only be used in highly selected cases and in places where such facilities are available.

A very few case reports regarding different modalities of treatment in adherent placenta are available in literature. A case of Placenta percreta in primigravida was reported by Rajkumar B et al.<sup>5</sup> that has ended in delivery of a healthy infant followed caesarean hysterectomy. Another case of placenta increta in primipara has been reported by Arnadottir BT et al.<sup>6</sup> that has ended in delivery of a healthy infant with successful conservative management with methotrexate. One case was reported by Sahu et al.<sup>7</sup> where spontaneous rupture of uterus in a primigravida occurred at 26 weeks of Gestation with Placenta Previa and Percreta. Wedge resection of the ruptured uterine wall along with placental tissue was done and closed with hemostatic sutures in two layers, and the remnant adherent placenta was left in situ. Kinoshita et al.<sup>8</sup> from Japan, reported one case of spontaneous rupture of uterus due to placenta percreta in a primi gravida without a background of any risk factor similar to the our case in its occurrence.

#### 4. Conclusion

Early diagnosis and prompt surgical treatment of uterine rupture and placenta percreta can reduce the maternal mortality risk. A multidisciplinary approach by a team of experienced obstetricians, anesthesiologists, neonatologists and urologists, as well as a blood bank helps in achieving the best outcome. This case report suggests that as obstetricians, we must have a high index of suspicion of uterine rupture in pregnant women with unusual symptoms with or without high risk factors.

#### 5. Source of funding

None.

#### 6. Conflict of interest

None.

#### References

1. Behera C, Krishna K, Kumar R, Gupta S. Sudden Death due to Uterine Rupture in a Primigravida with Placenta Accreta in Unscarred Uterus: An Autopsy Report. *J Indian Acad Forensic Med.* 2015;37(1).
2. Martínez-Garza PA, Robles-Landa LPA, Roca-Cabrera M, Visag-Castillo VJ, Reyes-Espejel L, et al. Spontaneous uterine rupture: report of two cases. *Cir Cir.* 2012;80:81–85.
3. Chandharan E, Rao S, Belli AM, Arulkumar S. The Triple-P procedure as a conservative surgical alternative to peripartum hysterectomy for placenta percreta. *Int J Gynaecol Obstet.* 2012;117(2):191–194.
4. Jacques SM, Qureshi F, Trent VS, Ramirez NC. Placenta accreta Mild cases diagnosed by placental examination. *Int J Gynecol Pathol.* 1996;15:28–33.
5. Rajkumar B, Kumar N, Srinivasan S. Placenta percreta in primigravida, an unsuspected situation. *Int J Reprod Contracept Obstet Gynecol.* 2014;3:239–241.
6. Arnadóttir BT, Hardardóttir H, Marvinsdóttir B. Case report seventeen year old primipara with placenta increta treated with methotrexate. *Laeknabladid.* 2008;94(7-8):549–552.
7. Sahu RR, Raut VS, Sewlikar V, Jain N. Spontaneous Rupture of Uterus in a Primigravida at 26 weeks of Gestation with Placenta Previa and Percreta. *J Obstet Gynecol India.* 2016;66(S2):S717–S719.
8. Kinoshita T, Ogawa K, Yasumizu T, Kato J. Spontaneous rupture of the uterus due to placenta percreta at 25-weeks of gestation: a case report. *J Obstet Gynaecol Res.* 1996;22(2):125–128.

#### Author biography

**Shelley Moudgil** Junior Resident

**Monica Karpa** Junior Resident

**Kamal Singh** Lecturer

**Anu Devi** Senior Resident

**Aahwani Verma** Junior Resident

**Cite this article:** Moudgil S, Karpa M, Singh K, Devi A, Verma A. Spontaneous uterine rupture due to cornual placenta percreta in unscarred uterus: A rare & challenging case. *Indian J Obstet Gynecol Res* 2020;7(1):122-125.