



## Case Report

# Diffuse cavernous hemangioma of the uterus mimicking adenomyosis- A rare case report

Saloni Naresh Shah<sup>1,\*</sup>, N Geetha<sup>1</sup>

<sup>1</sup>Dept. of Histopathology & Cytology, Apollo Hospitals, Chennai, Tamil Nadu, India



### ARTICLE INFO

#### Article history:

Received 08-01-2020

Accepted 05-03-2020

Available online 15-06-2020

#### Keywords:

Adenomyosis

Hemangioma

Myometrium

Uterus

### ABSTRACT

Vascular mesenchymal neoplasms of the female genital tract are extremely rare, of which cavernous hemangiomas of the uterine myometrium are uncommon. Only 60 cases have been documented in the world literature and we believe this is the fifth case to be reported in the Indian population. Here, we report a histologically diagnosed case of diffuse cavernous hemangioma of the uterine myometrium in a 40 year old lady, with a provisional diagnosis of adenomyosis. Pathological examination is the mainstay for the diagnosis of this condition.

© 2020 Published by Innovative Publication. This is an open access article under the CC BY-NC license (<https://creativecommons.org/licenses/by-nc/4.0/>)

## 1. Introduction

Vascular tumors of the female genital tract are quite rare and include capillary and cavernous hemangiomas, lymphangiomas, arteriovenous malformations, hemangioendotheliomas and angiosarcomas. These can be single or multifocal.<sup>1</sup> They occur in vagina, vulva, cervix, ovaries, fallopian tubes, placenta and rarely in the uterus.<sup>2</sup> Uterine serosa, myometrium and/or endometrium can harbor these lesions, in diffuse or in localized forms. These are incidental findings if small in size, and, when larger may mimic gynaecological neoplasms/conditions.

Cavernous hemangiomas are uncommon benign mesenchymal neoplasm of the uterus. Less than sixty cases have been reported in the literature. In pregnancy, they are incidentally detected during antenatal screening, can present with abnormal bleeding, fetal demise, postpartum hemorrhage and disseminated intravascular coagulation.<sup>3</sup> They occur in localized form as endometrial polyp/ serosal nodules or can diffusely involve the myometrium. Very few cases of uterine hemangiomas have been reported in perimenopausal and post menopausal women,<sup>1</sup> with wide

range of age distribution between 14 to 81 years. Presenting complaints are menorrhagia, dysmenorrhea, unrelenting pelvic pain and infertility. Hemangiomas of the uterus being a rare entity are not clinically suspected thus exposing the women to unnecessary investigations and unwarranted radical surgeries. Conservative treatment must be offered in women of child bearing age although hysterectomy is the choice of treatment if the above fails.<sup>4</sup>

In this article, we present a histologically diagnosed, rare case of diffuse cavernous hemangioma of the uterine myometrium in a 40 year old non pregnant lady, who underwent hysterectomy for a provisional diagnosis of adenomyosis.

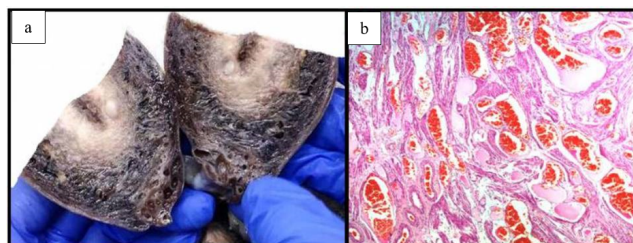
## 2. Case Report

A 40 year old non gravid lady presented to the gynaecology out-patient department with a history of prolonged painful bleeding and chronic pelvic pain. A provisional diagnosis of adenomyosis was made. We were unable to get any other antenatal, post natal and menstrual history nor did we have any investigations as the specimen was received from a remote rural health centre and the patient was lost to follow-up. Uterus with both fallopian tubes and ovaries were

\* Corresponding author.

E-mail address: [saloni.1008@gmail.com](mailto:saloni.1008@gmail.com) (S. N. Shah).

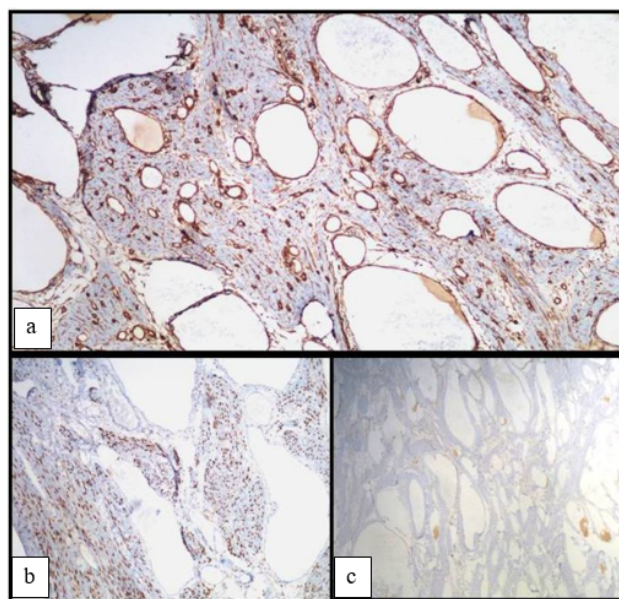
received in the histopathology laboratory in 10% formalin. The uterus measured 12 x 7 x 4 cms. Grossly, the serosa was congested. On sectioning, the endometrium was 3mm thick. The outer half of the myometrium showed diffuse brownish discoloration with a conglomerate of small blood filled hemorrhagic cystic spaces [Figure 1(a)]. An intramural firm and whorled nodule measuring 6mm was also seen. Cervix, bilateral ovaries and fallopian tubes showed no specific findings. Microscopy revealed non secretory endometrium. Myometrium showed variably dilated, irregular, blood vessels lined by a single layer of endothelial cells filled with erythrocytes and occasional fibrin thrombi, favoring a diagnosis of cavernous hemangioma [Figure 1(b)]. No features suggesting malignancy were present. A leiomyoma was also seen. The differentials to be excluded were adenomatoid tumor, lymphangioma and arteriovenous malformations. Presence of red blood cells within these spaces excluded lymphangioma. Immunohistochemistry was done as an ancillary test to confirm the diagnosis. The endothelial lining of these spaces were immunopositive for CD34 [Figure 1(a)]. Calretinin and progesterone receptor (PR) negativity ruled out the possibility of adenomatoid tumor [Figure 2(b)] and adenomyosis [Figure 2(c)], respectively. A diagnosis of diffuse uterine hemangioma was made.



**Fig. 1: a):** Gross photograph showing diffuse blood filled cavitory spaces in the myometrium in the outer half along with a small leiomyoma; **b):** Photomicrograph showing varying sized dilated blood filled spaces of a hemangioma in the myometrium (H&E, 400X)

### 3. Discussion

The first case of uterine hemangioma was described in a young lady on post mortem examination, following a twin delivery in 1897.<sup>2</sup> Since then less than sixty cases have been reported in the world literature and to the best of our knowledge, this is the fifth case to be reported from India. They can occur in adolescents, in child bearing age group, perimenopausal and post menopausal women though most of them are incidentally detected during pregnancy and must be suspected when there is refractory uterine bleeding during delivery. In non-pregnant women, hemangiomas are usually localized to the uterus and the presenting complaints



**Fig. 2: a):** CD34 positivity in endothelial lining of the cavernous spaces (Immunohistochemistry, 400x); **b):** Calretinin negativity in endothelial lining of the cavernous spaces (Immunohistochemistry, 400x); **c):** PR negativity in endothelial lining of the cavernous spaces (Immunohistochemistry, 400x)

are excessive bleeding, dysmenorrhea, anemia or infertility rarely. There are only two published case reports and one retrospective case series describing these lesions in non-pregnant females.<sup>1,2</sup> One was a 14 year old child, the second one was an 81 year old postmenopausal lady and the other women were in the fourth decade of life.<sup>1</sup> Our patient is a 40 year old perimenopausal woman.

Hemangiomas are of two types- capillary and cavernous types. Capillary hemangiomas present as endometrial polyp, are nodular and localized. Cavernous hemangiomas are usually diffuse with dilated blood filled spaces. They are either limited to the female genital tract or occur in multiple extrapelvic and pelvic organs when associated with hereditary diseases. The acquired hemangiomas are attributed to physical injuries caused by hypoxia, pregnancy, previous surgeries or curettage and to hyperestrogenic states like oral contraceptive pills, hormonal therapy, endometrial carcinomas, ectera. Hypothetical theories such as embryonic sequestration of the mesodermal rests in congenital forms and the influence of excessive estrogen on vasculogenesis and proliferation of endothelial growth factors in acquired states have been proposed thus explaining the pathogenesis of hemangiomas.<sup>2</sup>

Histopathological examination is the mainstay for diagnosing this entity. Clinical/ vaginal examination are almost never contributory. The diagnostic modalities like endometrial curettings, ultrasonography, magnetic resonance imaging or hysteroscopy are uninformative.

This is due to low index of clinical suspicion for hemangiomas because of its rarity and also possibly due to the similar clinical scenario as with other gynaecological conditions. Uterine hemangiomas should be suspected in patients with congenital hemangiomatosis syndromes and in those with presence of hemangiomas at other sites when a lady presents with antenatal complications such as fetal growth retardation or excessive bleeding. A combination of ultrasound and colour doppler, followed by MRI confirms the presence of a vascular lesion<sup>3</sup> Hemangiomas have to be distinguished from arteriovenous(AV) malformations, adenomatoid tumors and lymphangiomas which is possible only by histology. Immunohistochemistry may be done to support the diagnosis. Cavernous hemangiomas show irregular, dilated, varying sized blood filled spaces lined by endothelial cells within the myometrium. As opposed to this the dilated vessels in lymphangioma are smaller and do not contain erythrocytes. AV malformation demonstrates both arterial and venous channels with fistula formation gradually replacing the myometrium. Immunopositivity for CD34, CD31 and von-Willebrand factor and negative calretinin stain rules out the possibility of adenomatoid tumor and supports the diagnosis of hemangioma.<sup>2</sup> Conservative treatments such as knife excision, cryotherapy, radiotherapy, uterine artery embolization, laser ablation and local excision have been described. However, hemangiomas are almost always refractory to the above lines of treatment and hence hysterectomy is the treatment of choice.<sup>4</sup>

#### 4. Conclusion

We report a rare case of diffuse cavernous uterine hemangioma in a perimenopausal lady to emphasize on the importance of histological examination while making a

diagnosis and also to familiarize the practicing pathologists and the clinicians with this entity so that high index of suspicion can avoid misdiagnosis and prevent unwarranted treatments.

#### 5. Source of Funding

None.

#### 6. Conflict of Interest

None.

#### References

1. Jung HR, Cho CH, Kwon SH, Kwon SY. Cavernous hemangioma of the uterus in a postmenopausal woman - a case report. *Korean J Pathol.* 2011;45(5):520–2.
2. Chou WY, Chang HW. Uterine hemangioma: A rare pathologic entity. *Arch Pathol Lab Med.* 2012;136:567–71.
3. Ac E, Özsürmeli M, Yüksel A, Kalelioğlu J, Has R, Bakar N. Antenatal sonographic diagnosis of diffuse cavernous hemangioma of the uterus. *Marmara Med.* 2014;27:134–7.
4. Mahapatra S, Das BP, Kar A, Das R, Hazra K, Sethy S. Cavernous Hemangioma of Uterine Cervix in Pregnancy Mimicking Cervical Fibroid. *J Obstet Gynecol India.* 2013;63(4):288–90.

#### Author biography

Saloni Naresh Shah Consultant

N Geetha Senior Consultant

**Cite this article:** Shah SN, Geetha N. Diffuse cavernous hemangioma of the uterus mimicking adenomyosis- A rare case report. *Indian J Obstet Gynecol Res* 2020;7(2):283-285.