

Content available at: <https://www.ipinnovative.com/open-access-journals>

Indian Journal of Obstetrics and Gynecology Research

Journal homepage: www.ijogr.org

Case Report

Cervical ectopic pregnancy – Successful management by combined systemic methotrexate, bilateral uterine embolization and suction evacuation

Paridhi Gupta^{1,*}, Indu Chawla¹, Kanika Kumari¹

¹Dept. of Obstetrics and Gynaecology, AVBIMS & Dr. RML Hospital, New Delhi, India



ARTICLE INFO

Article history:

Received 26-11-2021

Accepted 13-12-2021

Available online 14-02-2022

Keywords:

Cervical ectopic pregnancy

Systemic methotrexate

Balloon tamponade

Bilateral uterine artery embolization

ABSTRACT

Case: A 31-year female, G4P2L2A1 with two previous cesarean deliveries and one dilatation and curettage, was diagnosed with cervical ectopic pregnancy of 8 weeks and two days without any cardiac activity. She had a complaint of slight pain in the abdomen without any bleeding per vagina. She was initially managed with multi-dose systemic methotrexate therapy. The value of beta-HCG decreased by about 70%. She then underwent bilateral uterine artery embolization followed by ultrasound-guided suction evacuation with descending cervical artery ligation with cervical balloon tamponade. The patient was asymptomatic throughout her hospital stay. Her beta-HCG value dropped to 10 IU/ml and usg showed empty endocervical canal on weekly follow-up.

Conclusion: Conservation methods like systemic methotrexate or potassium chloride, along with minimally invasive techniques like bilateral uterine artery embolization, are among the most effective and safe fertility-sparing modalities in managing cervical ectopic pregnancy. Proper case selection and availability of required infrastructure at tertiary care centers are mandatory.

This is an Open Access (OA) journal, and articles are distributed under the terms of the [Creative Commons Attribution-NonCommercial-ShareAlike 4.0 License](https://creativecommons.org/licenses/by-nc-sa/4.0/), which allows others to remix, tweak, and build upon the work non-commercially, as long as appropriate credit is given and the new creations are licensed under the identical terms.

For reprints contact: reprint@ipinnovative.com

1. Introduction

Cervical ectopic pregnancy is rare among other ectopic pregnancies. It accounts for about less than 1% of total ectopic pregnancies. It is associated with high morbidity and mortality. Early recognition and timely intervention both are indispensable parts of its management. Uncontrolled bleeding is one of the most dreadful complications of cervical ectopic pregnancy, leading to hysterectomy. Bilateral uterine artery embolization is one of the advanced techniques to prevent such complications and preserve fertility. Besides, factors like beta-HCG value, type of ectopic pregnancy, presence of cardiac activity, gestational age, size of g-sac, etc., also play a major role in deciding the mode of treatment.

2. Case Report

Mrs. X, 31 years old, G4P2L2A1 with previous two cesarean deliveries, came to GOPD with two months of amenorrhea and slight pain abdomen for MTP. On ultrasound, she was diagnosed with cervical ectopic pregnancy of 8 weeks two days without any cardiac activity (Figure 1).

There was no bleeding per vagina or spotting per vagina. Her menstrual cycles were regular. She had one spontaneous abortion nine years back, for which dilatation and curettage were done, followed by two cesarean deliveries. Her last cesarean was done four years back. On examination, her B.P. was 100/60 mmHg, and her pulse rate was 88 bpm. Pallor was absent. On abdomen examination, no tenderness or guarding/ rigidity were elicited. On vaginal examination, the uterus was eight weeks size, mobile, cervical motion tenderness was present, and bilateral fornices were free and

* Corresponding author.

E-mail address: paridhi.gupta257@gmail.com (P. Gupta).

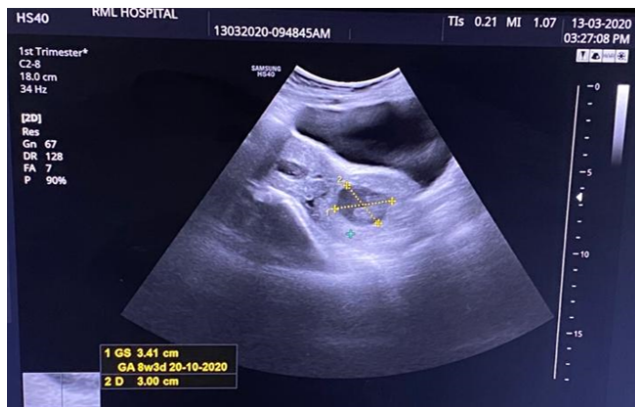

Fig. 1: Transvaginal ultrasonography image showing gestational sac of 8 weeks 3 days in the endocervical cavity

non-tender.

She was admitted and planned for medical management with a multi-dose methotrexate regimen since her vitals were stable and cardiac activity was absent on ultrasound. Injection methotrexate was given on day 1, 3, 5, and 7. Injection folinic acid was given on day 2, 4, 6, and 8. B-Hcg monitoring was done (Table 1).

Table 1: Decreasing trend of b-HCG while on systemic methotrexate treatment

Methotrexate injection	1 st Day	3 rd Day	5 rd Day	7 th Day
B-HCG (mIU/ml)	47800	32886	21610	14759

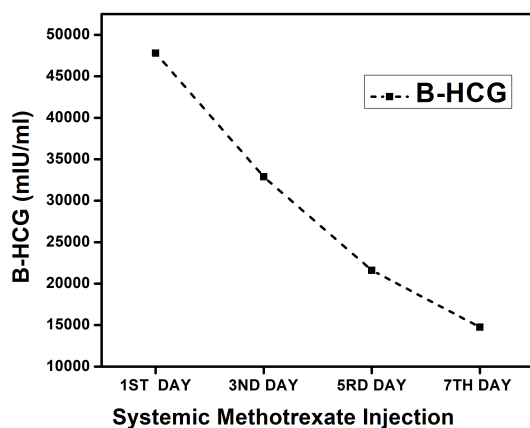


Fig. 2: Showing decreasing trend of b-HCG

The value of B-HCG showed a decreasing trend. The value decreased by almost 70% but was always more than 10,000mIU/ml. The decision for USG guided surgical evacuation after UAE was taken.

Bilateral uterine artery embolization was performed to prevent undue hemorrhage during surgical evacuation. The patient then underwent ultrasound-guided suction evacuation with descending cervical artery ligation with cervical balloon tamponade under general anesthesia. At the end of the procedure, the endocervical canal was empty as confirmed on ultrasound, no active bleeding was present, and the patient was hemodynamically stable.

In her post-operative period, balloon tamponade was removed after 24 hours. There was no episode of bleeding. She remained asymptomatic throughout her hospital stay. She was discharged after seven days of observation. B-HCG decreased to below 10 mIU/ml on her weekly follow-up.

3. Discussion

The incidence of cervical ectopic pregnancy is less than 1% and varies from 1/1000 to 1/50,000.¹ Cervical ectopic pregnancy implies the presence of a gestational sac within the endocervical canal and an empty endometrial cavity. Various risk factors like intrauterine manipulations like prior dilatation and curettage, previous cesarean deliveries, intrauterine devices, hysteroscopic intervention, uterine surgeries and IVF conception predispose to cervical ectopic pregnancy. Signs of cervical pregnancy on ultrasound include the barrel-shaped cervix, absence of 'sliding sign', blood flow around the gestational sac on color doppler. Transvaginal ultrasound is the most sensitive modality of choice. MRI can be used to know the depth of invasion when it is not evident on ultrasound. The literature is very scarce about definite management of cervical ectopic pregnancy. It depends upon numerous variables like patient age, parity, gestational age, complaints of the patient, history of previous surgeries, b-HCG value, and presence of cardiac activity. Gestational age of more than 12 weeks, absence of cardiac activity, low b-HCG values are associated with more successful outcomes with conservative management. The various methods described in the literature are systemic methotrexate, local (intra-amniotic or intra-fetal) injection of potassium chloride or methotrexate, dilatation and endocervical curettage, and aspiration, hysteroscopic cervical resection.

Dilatation and curettage require other adjuvant methods like balloon tamponade, uterine artery embolization, and uterine artery ligation to control uncontrolled bleeding, which is the most dreadful complication, sometimes requiring emergency hysterectomy.

Uterine artery embolization is a minimally invasive day care procedure performed by an interventional radiologist under fluoroscopic guidance. In this procedure, polyvinyl foam particles of size 300-750 micrometers obstruct bilateral uterine arteries. The total procedure takes 30-60 minutes. Most commonly used for symptomatic fibroids or adenomyosis. It can be used in cervical ectopic pregnancy before dilatation and curettage to minimize blood loss.

Complications like groin hematoma, post embolization syndrome, non-target embolization, vaginal discharge, and amenorrhea.

In 2016, Kaur R. reported a case of 27-year-old primigravida at six weeks gestation who presented with vaginal bleeding and was diagnosed with cervical pregnancy. Angiographic UAE was performed under local anesthesia to block the blood supply of the cervix via cervical branches of the uterine artery. This was followed by vacuum evacuation with curettage two hours later. She resumed her menstrual cycle two months later.²

In 2018, Keitaroh Takeda et al. reported a case of 44 years old female diagnosed with cervical ectopic pregnancy treated successfully with bilateral uterine artery embolization along with systemic methotrexate.³

In another case reported by C. Mininni et al., a 43-year-old nulliparous woman who presented with vaginal bleeding and a b-HCG value of 85,220 mIU/mL at nine weeks gestation located with endocervical canal was initially treated with intramuscular methotrexate and intra-amniotic potassium chloride, but three months later has to be treated with UAE due to massive vaginal bleeding. Her b-HCG decreased immediately. The cervical mass gradually shrank and disappeared a month after UAE. This approach preserved her fertility.⁴

4. Conclusion

Massive hemorrhage being the most dreadful complication of cervical ectopic pregnancy may necessitate hysterectomy in a young patient who wants to preserve fertility. Bilateral UAE followed by immediate evacuation is one of the most feasible options. It may be combined with systemic methotrexate. The modern era should consider new modes of management which are less invasive and includes fewer complications. BUAE is one such intervention that must be considered in the case of CEP whenever it is available.

5. Financial Disclosure

No fund, grant, or other support was received.

6. Conflict of Interest

The authors have no conflict of interest to declare that is relevant to the content of this article.

7. Informed Consent

The patient's informed consent for publication of this report was obtained.

Acknowledgments

The authors would like to thank our patient for giving consent in presenting her case.

References

1. Ozcivit IB, Cepni I, Hamzaoglu K, Erenel H, Madazlı R. Conservative management of 11 weeks old cervical ectopic pregnancy with transvaginal ultrasound-guided combined methotrexate injection: Case Report and Literature Review. *Int J Surg Case Rep.* 2020;67:215–218.
2. Kaur R, Singh R. Effective Management of Early Cervical Pregnancy with Bilateral Uterine Artery Embolization Followed by Immediate Evacuation and Curettage: A Case Report. *J Obstet Gynaecol India.* 2017;67:66–69.
3. Takeda K, Mackay J, Watts S. Case Report Successful Management of Cervical Ectopic Pregnancy with Bilateral Uterine Artery Embolization and Methotrexate. *Case Rep Emerg Med. Internet].* 2018;2018:1–4.
4. Mininni C, Garibaldi S, Fornari L, Domenici L, Cattani R, Bottone P. Effective combined treatment in ectopic cervical pregnancy preserving fertility: a case report and literature review. *Eur Rev Med Pharmacol Sci.* 2021;25(12):4190–7.

Author biography

Paridhi Gupta, Senior Resident  <https://orcid.org/0000-0001-9486-3832>

Indu Chawla, HOU (Head of Unit)

Kanika Kumari, Assistant Professor

Cite this article: Gupta P, Chawla I, Kumari K. Cervical ectopic pregnancy – Successful management by combined systemic methotrexate, bilateral uterine embolization and suction evacuation. *Indian J Obstet Gynecol Res* 2022;9(1):118-120.