

Content available at: <https://www.ipinnovative.com/open-access-journals>

Indian Journal of Obstetrics and Gynecology Research

Journal homepage: [www.ijogr.org](http://www.ijogr.org)

## Case Series

# A case series on abnormal placenta accreta spectrum in a rural tertiary care centre

C Jahnvi<sup>1,\*</sup>, Gomathy E<sup>1</sup>

<sup>1</sup>Dept. of Obstetrics and Gynecology, Sri Devaraj Urs Medical College, Karnataka, Kolar, India



## ARTICLE INFO

### Article history:

Received 16-11-2021

Accepted 11-12-2021

Available online 14-02-2022

### Keywords:

Massive obstetric haemorrhage

Defective decidualisation

Placenta accreta spectrum

Peripartum hysterectomy

## ABSTRACT

Placenta accreta spectrum (PAS) is a potentially life-threatening obstetric condition that requires a multidisciplinary approach to management. The main complication of PAS is due to its massive obstetric haemorrhage which leads to maternal morbidity and mortality. The incidence of placenta accreta spectrum increases day by day due to an alarming increase in caesarean section rates. Depending on the range of invasiveness, The Placenta accreta spectrum is classified as placenta accreta, placenta increta and placenta percreta. The etiology of placenta accreta spectrum is that a defect of the endometrial–myometrial interface leading to failure of normal decidualization in the area of a uterine scar, which allows abnormally deep placental anchoring villi and trophoblast infiltration. In recent times, prenatal ultrasound scanning with gray scale imaging and color Doppler imaging seems to be an excellent tool for screening of PAS.

We report here a series of 5 cases of Placenta Accreta who reported to hospital as Bleeding P/v or USG scan report showing Abnormal Placental invasion or Placental Position. Patients reported were posted for Emergency LSCS under definitive indications but underwent Peripartum hysterectomy. The Ultrasound findings were subsequently confirmed at surgery and proven on histopathological examination. Peripartum hysterectomy remains the life saving procedure over conservative methods for PPH secondary to Abnormal Placental invasion.

This is an Open Access (OA) journal, and articles are distributed under the terms of the [Creative Commons Attribution-NonCommercial-ShareAlike 4.0 License](https://creativecommons.org/licenses/by-nc-sa/4.0/), which allows others to remix, tweak, and build upon the work non-commercially, as long as appropriate credit is given and the new creations are licensed under the identical terms.

For reprints contact: [reprint@ipinnovative.com](mailto:reprint@ipinnovative.com)

## 1. Introduction

In 1937, the first case series on placenta accreta was published.<sup>1</sup> They defined placenta accreta as “abnormal adherence of the after birth in part or whole to the underlying uterine wall”.<sup>2</sup> The main problem of PAS is because of the massive bleeding due to adherence of placenta to uterine wall. Researchers have classified this kind of abnormal adherence of placenta into three categories depending on the degree of invasiveness of the placenta in the myometrium. Placenta accreta (Placental villi adhere to the superficial myometrium without interposing decidua), placenta increta (the placental villi penetrate into the myometrium), and placenta percreta (placental

villi penetrates through the entire uterine wall till the surrounding organs).<sup>3</sup> The most accepted theory is that prior uterine surgery involving the endometrial-myometrial interface leading to defective decidualization in an area of uterine scar, allowing the anchoring villi of the placenta to adhere to the myometrium abnormally and further trophoblast invasion. Over the past 40 years, the incidence of placenta accreta increased about four fold from 0.08% to 0.3%<sup>4</sup> because of the increase in Cesarean section rate.

We report here a series of 5 cases of Placenta Accreta who reported to hospital as Bleeding P/v or USG scan report showing Abnormal Placental invasion or Placental Position. Patients reported were posted for Emergency LSCS under definitive indications but underwent Peripartum hysterectomy. The Ultrasound findings were subsequently confirmed at surgery and proven on histopathological

\* Corresponding author.

E-mail address: [drcjahnvi@gmail.com](mailto:drcjahnvi@gmail.com) (C. Jahnvi).

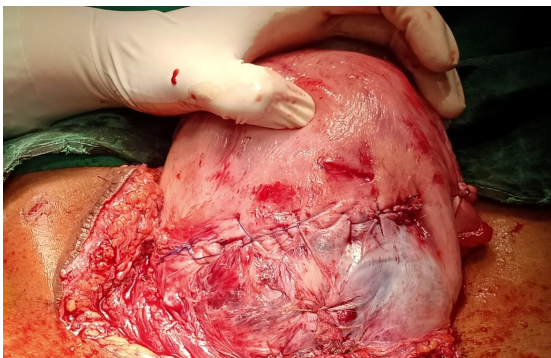
examination.

## 2. Objective

To analyse the best and successful approach for management of Abnormal placenta accreta spectrum

### 2.1. Case 1

1. A 32-year old G3P2L2 with h/o 37 weeks of gestation age and previous 2 LSCS came with scan report showing Grade IV placenta previa, completely covering the os for safe confinement. Routine investigations were done and Hb was found to be 9gm%.
2. 2 pints FFPs and 2 pints PRBC transfusions were done pre-operatively and patient underwent emergency LSCS in view of previous 2 LSCS with Complete placenta previa. Intraoperatively 2 pint PRBC and 2 pint FFP's were transfused. After delivery of baby, placenta was removed and uterus was sutured. Patient was shifted to ICU I/v/o hypotension and severe blood loss. Within 2 hrs patient developed hypotensive shock and was started on Iontropes. Patient underwent repeat emergency exploratory laprotomy with peripartum subtotal hysterectomy with bilateral internal iliac artery ligation. Post operatively 1 pint PRBC, 4 pints FFP, 4 pints platelets and 3 hemocele transfusions were done and patient recovered drastically. Post operative period was uneventful and patient recovered and was fit for discharge within 7 days of the procedure.
3. HPR Report of the dissected specimen showed features of Placenta increta.



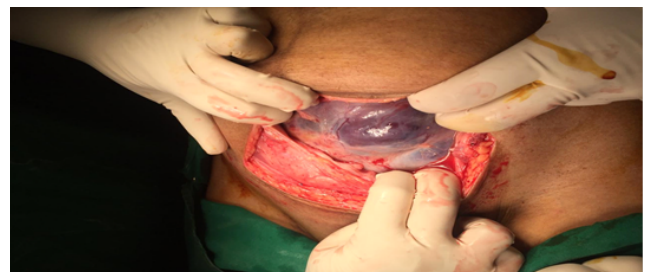**Fig. 1:** Intra operative picture after placental extraction and uterine closure

### 2.2. Case 2

1. A 22-year old, G2P1L1 with h/o 36 weeks and 6 day gestational age and Previous 1 LSCS, With scan

report showing complete placenta previa with placenta percreta and placental vessels extending till the bladder wall, came with complaints of bleeding P/v and pain abdomen.

2. P/A uterus was corresponding to 36 weeks with breech presentation.
3. P/S examination showed active bleeding through the os.
4. On admission routine investigations were done and hb was found to be 8.8gm%.
5. Patient had an emergency LSCS i/v/o Complete placenta previa with placenta percreta.
6. Per operatively, placenta was extending upto the uterine serosa.
7. Incision was given 2 finger width above the upper margin of the placenta.
8. Placenta swept through.
9. After baby extraction, placenta was left in situ and peripartum hysterectomy was done in view of profuse bleeding. 3 Pint PRBC and 1 pint FFP was transfused intra operatively.
10. Patient was shifted to postoperative ward for monitoring and Post operatively 3 pint PRBC, 2 pint FFP and 4 Pint platelet was transfused.
11. HPR Report of the dissected specimen showed features of Placenta Percreta.



**Fig. 2:** Intra operative picture

### 2.3. Case 3

1. A 23-year old, G3P2L2 with H/o 33weeks 5 days gestational age, with previous 2 LSCS was referred from a private hospital in view of Bleeding P/V. Routine investigations showed Hb 11.1gm%
2. Usg scan at 21 weeks showed complete placenta previa.
3. P/A : Uterus was 30 weeks size, Relaxed and FHR was present.
4. P/S: Active bleeding was present
5. Preoperatively 1 pint PRBC and 2 pints FFP's were transfused. She under went Emergency LSCS i/v/o Previous 2 LSCS with Placenta previa Per Operatively, LUS was not well formed and placenta was completely

covering the os. placenta was swept through, After baby extraction, placenta was extracted in piece meal, placenta could not be extracted in toto.

6. Uterine preservation with placental extraction was tried with uterine artery and Bilateral internal iliac artery ligation. Intraoperatively 2 pints prbcs and 2 ffp's were transfused.
7. Due to failure of conservative methods, Peripartum hysterectomy was done as the final resort. Postoperatively 2 prbs, 4 ffp's and 4 platelets were transfused.
8. Patient recovered and became fit for discharge within 7 days of procedure.
9. HPR Report of the dissected specimen showed features of Placenta accreta.

#### 2.4. Case 4

1. A 33-year old, G3P2L2 with 33weeks and 1 day gestational age previous 2 LSCS with gestation diabetes mellitus with Complete placenta previa, came with complaints of bleeding P/V since 3 hours. On admission hb was 12gm%.
2. Patient was taken for emergency LSCS i/v/o complete placenta previa and placenta accreta.
3. Per operatively, LUS was thinned out and Placenta was anterior covering the cervical os completely. Placenta was seen through the serosal layer. Incision was taken above the placental insertion. After baby extraction, Peripartum hysterectomy with the placenta left in situ. Intraoperatively 3 pints PRBC's and 4 pints FFP's were transfused. Postoperative period was uneventful and patient was fit for discharge after 5 days of procedure.
4. HPR Report of the dissected specimen showed features of Placenta percreta.

#### 2.5. Case 5

1. A 35-year old, P4L3A1D1 with h/o previous 2 LSCS was referred from Govt PHC i/v/o Retained placenta after vaginal delivery.
2. Patient gives H/o missed abortion at 20 weeks and expulsion of conceptus 5 hours back.
3. Per Abdomen, Uterus was atonic.
4. On per speculum examination, Active bleeding was present.
5. On per vaginal examination, Placental bits were seen and was removed in piece meal as much as possible.
6. Routine investigations were done and hb was 7 gm%.
7. On failure of uterotonics and Medical management of post partum Haemorrhage, patient was taken for Manual removal of placenta under General anesthesia. Pre-operatively 2 pint prbc and 4 pints ffp's were transfused. Placenta was adherent to lower uterine segment and partially invading bladder

serosa. Placenta was partially removed in piece meal as much as possible. On failure of conservative methods and constrictive sutures, Peripartum subtotal hysterectomy was done followed by methotrexate therapy. Postoperatively patient was stable and patient became fit for discharge after 12 days of procedure.

8. HPR of dissected specimen showed features of placenta percreta.

### 3. Discussion

In our study, in a rural medical college with limited facilities, all the cases were managed on emergency basis.

Cahill et al. in 2018, suggested Multi Disiplinary Team comprising of obstetrician, anaesthetist, radiologist, intensivist and blood bank is an absolute requirement in patients with PAS.<sup>5</sup> In our study, we followed a multidisciplinary for all the cases who presented with emergency complications.

The occurrence of invasive PAS (increta and percreta) may be due to uterine scar cracking partially or completely, which thereby allows the deeper invasion of placental villi(myometrium, serosa, and even beyond).<sup>6</sup> Almost all cases in our case series had previous 1 LSCS or 2 LSCS. A study conducted by Silver RM et al, concluded incidence of placenta accreta spectrum with previous 0,1,2,3,4,5 caesarean sections are 0.24%, 0.31%, 0.57%, 2.31%, 2.33% and 6.74% respectively and the incidence of abnormal placentation with placenta previa with previous 0,1,2,3,4,5 lscs are 3%, 11%, 40%, 61%, 67% and 61 % respectively.<sup>5</sup> The incidence of placenta accreta spectrum disorder with previous LSCS and placenta previa ranges from 0.24% to 0.57%. In our study most patients with placenta previa had abnormal placentation.

Ultrasound signs of PAS can be detected as early as 11-14 weeks<sup>7,8</sup> In PAS serial follow-up scans are recommended starting from 28 weeks to predict degree and extent of invasion<sup>8</sup> The ideal timing for such evaluation of PAS is between 18 and 24 weeks of gestation.<sup>9</sup> In this case series, PAS is detected in second or third trimester as most cases are referred and due to the presence of placenta previa and none of these patients in our study were booked in our hospital. Prenatal screening PAS is extremely important for preventing adverse outcomes. It consists of 3 vital steps 1. Identification of high risk women from a risk population, Acurate diagnosis for analysing the degree and extent of invasion and Planned management.<sup>9</sup>

The optimal time for delivery in PAS according to ACOG is 34 weeks to 35+6 weeks for scheduled c-section and hysterectomy in a stable patient. According to RCOG, delivery between 35 weeks to 36 + 6 weeks provides the best fetal outcome. SOGC suggests the optimal delivery timing is between 34 weeks to 36 weeks for an healthy mother. FIGO recommends termination of pregnancy at 37 weeks to reduce poor neonatal outcome.<sup>10</sup> Since all cases in our

case series were unbooked, and came with complaints of bleeding p/v or after 37 weeks, we didn't have the liberty of planned management.

Many consider the caesarean-hysterectomy as the gold standard for the delivery of women with PAS.<sup>11,12</sup> All patients in our study had caesarean hysterectomy and had successful recovery. A largest series of caesarean-hysterectomies for PAS shows transfusion of at least four units of packed red blood cells (RBCs) in 20% patients, cystotomy (deliberate or not) in 3%, and re-operation in 8% and ureteral injury of about 3 to 8%<sup>9</sup> adverse outcomes were related to severity of PAS than caesarean-hysterectomy. Also conservative approaches did not prove better outcome.<sup>11,13</sup> In our study, In a rural medical college with limited facilities, All the cases were managed on emergency basis. Almost all patients in our study had Pre or post operative massive blood transfusions.

Uterine preservation with placental removal followed by repair of corresponding defect, may be successful in cases without excessive risk<sup>9</sup> In our fifth case where the placenta was invading the posterior bladder serosa, subtotal hysterectomy was done and placenta was removed partially by piecemeal followed by short course methotrexate therapy and patient had a successful complete recovery.

Conservative measures like retention of the placenta (IRP), partial myometrial excision, Triple P procedure which involves three main steps: perioperative localization of the upper placental edge, pelvic devascularization and placental non-separation with myometrial excision followed by the repair of the myometrial defect.<sup>9</sup> The safety and efficiency of triple P procedure is not fully studied. Hence, it couldn't be tried in the present study on emergency basis.

Decision on conservative management is taken when fertility preservation and reducing time of surgery becomes important than complications of placental retention like infection, sepsis, postpartum haemorrhage and coagulopathy. Since all patients in our study had completed their family. The decision of fertility preservation overrode the need to prevent maternal morbidity and mortality.

In this case series, all the patients had successful recovery and uneventful post operative period following peripartum hysterectomy performed after failed conservative management. For most cases, internal iliac artery ligation was the most commonly followed conservative management which eventually failed.

#### 4. Conclusion

1. In a rural tertiary care centre with limited resources, all cases were managed on emergency basis with multidisciplinary approach.
2. In our study, peripartum hysterectomy remains the main lifesaving procedure over conservative methods for PPH secondary to Abnormal Placental invasion.

#### 5. Source of Funding

Nil.

#### 6. Conflict of Interest

None.

#### Acknowledgments

We would like to thank the authorities of Sri Devaraj Urs Academy of Higher Education and Research (SDUAHER), Kolar, Karnataka, India for supporting this study.

#### References

1. Jauniaux E, Jurkovic D. Placenta accreta: Pathogenesis of a 20th century iatrogenic uterine disease. *Placenta*. 2012;33(4):244–51.
2. Jauniaux E, De-Campos DA. FIGO consensus guidelines on placenta accreta spectrum disorders: Introduction. *Int J Gynaecol Obstet*. 2018;140(3):261–4.
3. Cahill AG, Beigi R, Heine RP, Silver RM, Wax JR. Placenta Accreta Spectrum. *Am J Obstet Gynecol*. 2018;219(6):2–16.
4. Wu S, Kocherginsky M, Hibbard JU. Abnormal placentation: Twenty-year analysis. *Am J Obstet Gynecol*. 2005;192(5):1458–61.
5. Silver RM, Landon MB, Rouse DJ, Leveno KJ, Spong CY, Thom EA, et al. Maternal Morbidity Associated With Multiple Repeat Cesarean Deliveries. *Obstet Gynecol*. 2006;107(6):1226–32.
6. Tantbiroj P, Crum CP, Parast MM. Pathophysiology of Placenta Creta: The Role of Decidua and Extravillous Trophoblast. *Placenta*. 2008;29(7):639–45.
7. Cali G, Timor-Tritsch IE, Forlani F, Palacios-Jaraquemada J, Monteagudo A, Agten AK, et al. Value of first-trimester ultrasound in prediction of third-trimester sonographic stage of placenta accreta spectrum disorder and surgical outcome. *Ultrasound Obstet Gynecol*. 2020;55(4):450–9.
8. Cali G, Timor-Trisch IE, Palacios-Jaraquemada J, Monteagudo A, Forlani F, Minnici G. Changes in ultrasonography indicators of abnormally invasive placenta during pregnancy. *Int J Gynecol Obstet*. 2018;140(3):319–25.
9. Yu FNY, Leung KY. Antenatal diagnosis of placenta accreta spectrum (PAS) disorders. *Best Pract Res Clin Obstet Gynaecol*. 2021;72:13–24.
10. Jauniaux E, Kingdom JC, Silver RM. A comparison of recent guidelines in the diagnosis and management of placenta accreta spectrum disorders. *Best Pract Res Clin Obstet Gynaecol*. 2021;72:102–16.
11. Sentilhes L, Goffinet F, Kayem G. Management of placenta accreta. *Acta Obstet Gynecol Scand*. 2013;92(10):1125–34.
12. Silver RM, Branch DW. Placenta Accreta Spectrum. *N Engl J Med*. 2018;378(16):1529–36.
13. Sentilhes L, Kayem G, Silver RM. Conservative Management of Placenta Accreta Spectrum. *Clin Obstet Gynecol*. 2018;61(4):783–94.

#### Author biography

C Jahnvi, Post Graduate

Gomathy E, Professor

**Cite this article:** Jahnvi C, Gomathy E. A case series on abnormal placenta accreta spectrum in a rural tertiary care centre. *Indian J Obstet Gynecol Res* 2022;9(1):143-146.