

Content available at: <https://www.ipinnovative.com/open-access-journals>

Indian Journal of Obstetrics and Gynecology Research

Journal homepage: [www.ijogr.org](http://www.ijogr.org)

## Original Research Article

## Intrauterine deaths in pregnancies with COVID-19 infection

Kandukuri Malavika<sup>1,\*</sup>, Janaki Vellanki<sup>1</sup><sup>1</sup>Dept. of Obstetrics and Gynaecology, Gandhi Medical College and Hospital, Secunderabad, Telangana, India

## ARTICLE INFO

## Article history:

Received 03-02-2022

Accepted 21-03-2022

Available online 20-05-2022

## Keywords:

COVID- 19

Intrauterine fetal death

Placental histopathology

## ABSTRACT

**Background:** Corona virus outbreak emerged in Wuhan in late December 2019. It was declared as pandemic by WHO in March 2020. Patients usually present with fever cold, cough and fatigue. The severity of the disease varies from moderate to severe, with the majority of cases being mild. Fatality was high in immuno-compromised patients. Pregnancy is considered to be an immunosuppressive state, so pregnant women were also at risk of acquiring COVID-19 infection. According to the literature, COVID-19 infection during pregnancy may cause fetal discomfort, preterm labour, miscarriage, or neonatal death.

**Materials and Methods:** This is an observational analytical study that took place over an 8-months period during which the hospital served as a nodal centre for Covid patients. All pregnant women with intrauterine death at 20 weeks or more of pregnancy with COVID-19 infection confirmed through RTPCR were included in the study. Placental fragments and amniotic fluid were tested for SARS-COV2 infection. Histology of placental fragments were studied by pathologist.

**Results and Conclusion:** Out of 30 Intrauterine deaths reported during the study period only twelve of them are due to associated co-morbidities like hypertensive disorders, diabetes and others, remaining are due to COVID-19 related hypoxia. Fetal demise with no other clinical or obstetric disorders prove that intrauterine deaths is also an outcome in pregnancies with COVID-19 infection with signs of acute chorioamnionitis and other inflammatory reactions noted in histological specimen of placental fragments.

This is an Open Access (OA) journal, and articles are distributed under the terms of the [Creative Commons Attribution-NonCommercial-ShareAlike 4.0 License](https://creativecommons.org/licenses/by-nc-sa/4.0/), which allows others to remix, tweak, and build upon the work non-commercially, as long as appropriate credit is given and the new creations are licensed under the identical terms.

For reprints contact: [reprint@ipinnovative.com](mailto:reprint@ipinnovative.com)

## 1. Introduction

Novel corona virus outbreak emerged in Wuhan, a city in china in late December 2019.<sup>1</sup> The World Health Organization (WHO) officially named it as Corona virus disease 19 (COVID-19) and proclaimed it as a pandemic on March 11th, 2020.<sup>2</sup>

COVID-19 is caused by SARS-CoV-2, a member of the corona virus family. The primary mode of transmission is through the respiratory droplets and direct contact.<sup>3</sup> Infected people usually have fever, cold, cough, and lethargy, as well as dyspnea, myalgia, and sore throat.<sup>4</sup> The presence of ground glass opacities is a common

radiographic finding. The disease severity ranges from mild to serious, with the majority of cases being mild. Patients with advanced age or underlying comorbidities had a higher mortality rate.

Owing to the fact that pregnancy is considered to be an immunosuppressive state, pregnant women were also at threat of COVID-19 infection, though it was unclear how the disease would manifest differently in pregnant women than in non-pregnant women.

The most of pregnant women have mild type of disease, with only a few experiencing severe maternal morbidity or death.

More than 90% of pregnant women who have pneumonia are at risk of miscarriage and other complications.

\* Corresponding author.

E-mail address: [malavika0908@gmail.com](mailto:malavika0908@gmail.com) (K. Malavika).

Viral pneumonia is most commonly associated with morbidity and mortality in pregnant women. It is more severe and less responsive to treatment than bacterial pneumonia.

Data suggests that depending on the severity of the disease, Pregnant women may have symptoms such as hypoxia, hypotension, and placental hypoperfusion, which can result in fetal discomfort, premature labour, miscarriage, or death.

### 1.1. Pathogenesis

Angiotensin converting enzyme 2 (ACE-2) receptors, which are present in lung alveolar epithelial cells, small intestine enterocytes, and vascular endothelial cells are the functional receptors of SARS-CoV2.<sup>5</sup> This virus' spike proteins may bind to sensitive cells' cellular receptors to infect their target cells, following which viral replication occurs in the cell cytoplasm.

It shows high and early replication rates. Using several strategies, SARS-COV-2 may infect dendritic cells, macrophages and T cells to avoid host innate immune response.<sup>6–9</sup> It is capable of doing this by abolishing Type-1 interferon (T1FN) expression after the suppression of signal transducers and activation of transcription (STAT) proteins.

The SARS-CoV2 then destroys the infected cells and is released into the body's bloodstream, promoting innate immunity. This results in the release of pro-inflammatory cytokines (IL-1 beta, IL-6, and TNF-alpha) as well as T and B cells.<sup>10,11</sup>

These pro-inflammatory cells and cytokine storms cause hyper inflammation and lymphocyte depletion in the lungs.

The pulmonary histology pattern shows diffuse alveolar damage. Other changes include the formation of a hyaline membrane, alveolar haemorrhage, desquamation of pneumocytes, and significant infiltration of neutrophils and macrophages in the alveoli.

The ACE-2 receptor is also found in the human placenta, which explains how the virus infects the placenta.

Pregnant women with ARDS are much more prone to hypoxia, also have 20% increase in oxygen consumption, and have a 20% loss in functional residual capacity during pregnancy. ARDS induced hypoxia in pregnant women may lead to placental hypoxia. This hypoxic placenta produces anti-inflammatory and pro-inflammatory biomarkers that converge on the maternal endothelium, resulting in endothelial dysfunction, hypertension, and organ damage.<sup>12</sup>

Recent studies have shown that systemic maternal infections and inflammation can harm placental vasculogenesis and angiogenesis, resulting in poor pregnancy outcomes such as low birth weight and intrauterine fetal demise.

### 1.2. COVID-19 induced IUFD

Patients with cytokine storm syndrome are at a significant risk of developing IUFD. Cytokine storm is defined by enormous, uncontrolled cytokine release, which results in multi-organ failure and ARDS. Anaemia can occur in the patient, reducing oxygen flow to the foetus and eventually leading to ischemia and death if not treated. When not treated, a cytokine storm induces DIC, which leads to placental thrombosis and haemorrhage, resulting in placental insufficiency and IUFD.

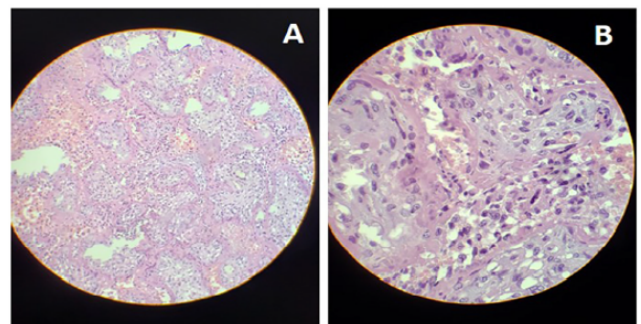
### 1.3. Laboratory confirmation of COVID-19

Pharyngeal swab specimens should be tested positive for RT-PCR (reverse transcriptase polymerase chain reaction). In this study, cycle threshold results below 33 were considered positive.<sup>13</sup>

To examine placental fragments, immediate samples within 24 hrs after delivery were taken. The fragments were transported to the laboratory in 3ml sterile saline. These samples were digested with proteinase-k for an hour at 55 degrees celsius, centrifuged, and the RNA was extracted from the supernatant. Samples of amniotic fluid were taken during birth and delivered to the laboratory in a refrigerator.

### 1.4. Histopathological examination of placenta

Formalin immersed placental specimens were transferred to the pathology laboratory within 24hrs after delivery. Haematoxylin and eosin stained placental specimens were studied by the pathologist. Histopathological examination of placenta showed signs of acute chorioamnionitis, extensive deposition of intervillous fibrin, mixed villitis and intervillitis are shown in Figure 1. Informed consent were obtained by the participants for the study.



**Fig. 1:** Histological findings **A:** Placenta low resolution: Extensive deposition of perivillous fibrin **B:** Placenta high resolution: Mixed villitis and intervillitis Source link doi: 10.1016/j.crwh.2020.e00243. PMID: 32704477; PMCID: PMC7354271.

1.5. Study design

Observational analytical study.

2. Materials and Methods

The research study was conducted in obstetrics and gynecology department at Gandhi Hospital, Secunderabad from March 2020 to November 2020 over a span of 8 months. The study include all cases of intrauterine fetal demise at 20 weeks or more of gestation in all women infected with COVID-19.

3. Results

Out of 30 intrauterine deaths reported in COVID-19 infected pregnant women at Gandhi hospital over a span of 8 months, only twelve of them are due to associated comorbidities like hypertensive disorders, diabetes and others. Remaining 18 intrauterine deaths are due to COVID-19 infection related hypoxia.

Table 1: Number of intrauterine deaths and its causes

Causes of Intrauterine deaths	Number of deaths	Percentage of causes
Severe preeclampsia	5	16%
Eclampsia	3	10%
Diabetes	2	7%
Abruption	2	7%
COVID-19 infection	18	60%

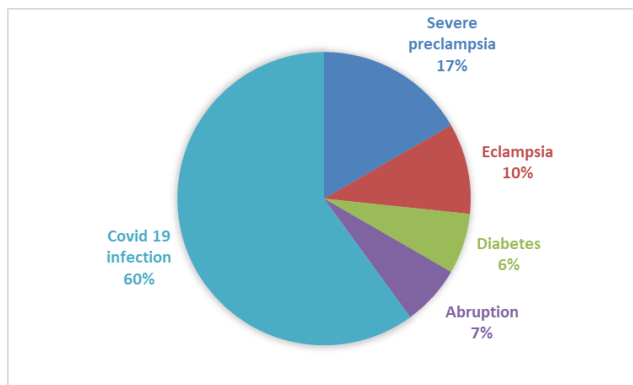


Fig. 2: Pie chart of causes of intrauterine deaths

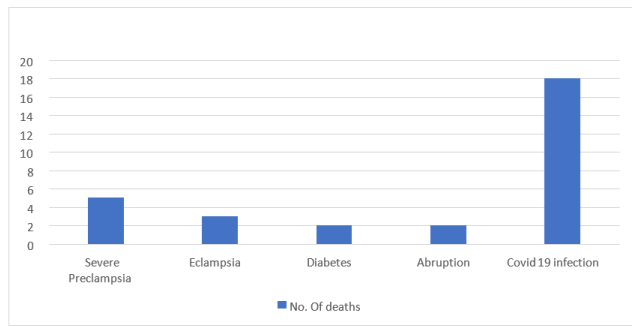
4. Discussion

Pregnant women with fetal demise at 20 or more weeks of gestation with COVID-19 infection confirmed through RTPCR were included in the study. All other parameters like age, parity, gestational age, birth weight were compared. Placental fragments were subjected to histopathology after being tested positive for SARS-COV2 infection through

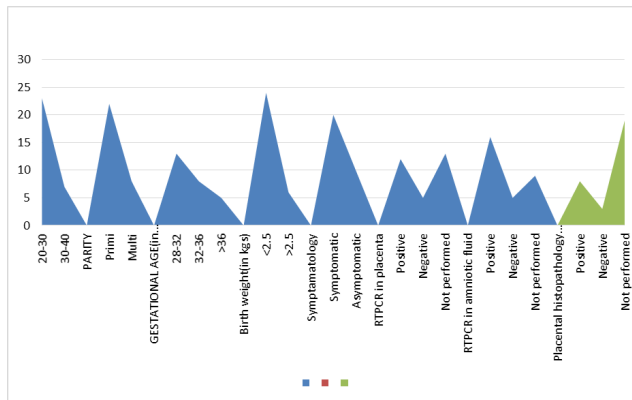
Table 2: Comparison of characteristics of 30 cases of fetal death in women with COVID-19

Age (years)	Parity	Gestational Age (in weeks)	Birth weight (in kgs)	Symptomatology	RTPCR in placenta		RTPCR in amniotic fluid		Placental histopathology showed reactions	
					P	NP	P	NP	P	N
20-30	Primi	28-32	>36	S	AS	NP	P	N	NP	NP
30-40	Multi	32-36	<2.5	S	AS	NP	P	N	NP	NP
23	7	13	24	6	10	13	16	5	9	19
					12	5	16	5	8	3

Here, S-Symptomatic, AS-Asymptomatic  
P-Positive, N-Negative, NP-Not Performed



**Fig. 3:** Pie chart of causes of intrauterine deaths



**Fig. 4:** Area chart of comparison of characteristics of 30 cases of fetal death in women with COVID-19

RTPCR. Amniotic fluid samples were also subjected to RTPCR.

Out of 30 cases, 18 cases of fetal demise are reported in women with confirmed COVID-19 infection without any other clinical or obstetric disorders proves that intrauterine fetal death can also be an outcome of SARS-COV2 infection in pregnancy. Placental changes like massive deposition of intervillous fibrin including villitis and intervillitis, intense neutrophils and lymphocyte infiltration suggests that SARS-COV2 has direct effect on placenta.

Even though exact mechanism for histological changes noted in placenta due to Intrauterine SARS-COV2 transmission are unclear, following hypothesis may be possible.<sup>14</sup>

1. Angiotensin converting enzyme (ACE2) receptor, sensitive receptor for SARS-COV2 expressed on placenta explains the direct effect of virus on placenta.<sup>15,16</sup>
2. Placental barrier damage due to maternal hypoxemia because of COVID-19 may lead to intrauterine transmission of SARS-COV2.

A strong point of our study is that all patients with laboratory confirmation of COVID-19 were only included in the study and histological sections of all placental

specimens were studied by the same pathologist. A drawback of our study is that placental and amniotic fluid samples of all cases were not subjected to RTPCR for confirmation of SARS-CoV2 infection.

It is necessary to find out all the associated comorbidities in pregnant women with COVID-19 infection for in-time appropriate management.

## 5. Conclusion

This is a study of pregnant women with fetal demise at 20 or more weeks of gestation including clinical features, pathogenesis leading to intrauterine fetal death. Vertical transmission of SARS-COV2 is otherwise proved with results being tested positive of amniotic fluid and placental fragments samples subjected to RTPCR. Due to limitations in our study, further researches are needed to confirm the findings and for in-time management of pregnant women with COVID-19 infection.

## 6. Source of Funding

None.

## 7. Conflict of Interest


The authors declare no conflict of interest.

## References

1. Ayed A, Embaireeg A, Benawadh A, Al-Fouzan W, Hammoud M, Al-Hathal M, et al. Maternal and perinatal characteristics and outcomes of pregnancies complicated with COVID-19 in Kuwait. *BMC Pregnancy Childbirth*. 2020;20:754. doi:10.1186/s12884-020-03461-2.
2. Wenling Y, Junchao Q, Xiao Z, Ouyang S. Pregnancy and COVID-19: management and challenges. *Rev Inst Med Trop Sao Paulo*. 2020;62:e62.
3. Richtmann R, Torloni MR, Otani ARO, Levi JE, Tobará MC, Silva CA, et al. Fetal deaths in pregnancies with SARS-CoV-2 infection in Brazil: A case series. *Case Rep Womens Health*. 2020;27:e00243.
4. Yee J, Kim W, Han JM, Yoon HY, Lee N, Lee KE, et al. Clinical manifestations and perinatal outcomes of pregnant women with COVID-19: a systematic review and meta-analysis. *Sci Rep*. 2020;10:18126. doi:10.1038/s41598-020-75096-4.
5. Hamming I, Timens W, Bulthuis ML, Lely AT, Navis G, Goor HV. Tissue distribution of ACE2 protein, the functional receptor for SARS coronavirus. A first step in understanding SARS pathogenesis. *J Pathol*. 2004;203(2):631–7.
6. Spiegel M, Schneider K, Weber F, Weidmann M, Hufert FT. Interaction of severe acute respiratory syndrome-associated coronavirus with dendritic cells. *J Gen Virol*. 2006;87(Pt 7):1953–60.
7. Chu H, Zhou J, Wong BH, Li C, Cheng ZS, Lin X, et al. Productive replication of Middle East respiratory syndrome coronavirus in monocyte-derived dendritic cells modulates innate immune response. *Virology*. 2014;p. 454–5. doi:10.1016/j.virol.2014.02.018.
8. Zhou J, Chu H, Li C, Wong BH, Cheng ZS, Poon VK, et al. Active replication of Middle East respiratory syndrome coronavirus and aberrant induction of inflammatory cytokines and chemokines in human macrophages: implications for pathogenesis. *J Infect Dis*. 2014;209(9):1331–42.
9. Chu H, Zhou J, Wong BH, Li C, Chan JF, Cheng ZS. Middle East respiratory syndrome coronavirus efficiently infects human primary T lymphocytes and activates the extrinsic and intrinsic apoptosis pathways. *J Infect Dis*. 2016;213(6):904–14.

10. Wong CK, Lam CW, Wu AK, Ip WK, Lee NL, Chan IH, et al. Plasma inflammatory cytokines and chemokines in severe acute respiratory syndrome. *Clin Exp Immunol*. 2004;136(1):95–103.
11. Kong SL, Chui P, Lim B, Salto-Tellez M. Elucidating the molecular pathophysiology of acute respiratory distress syndrome in severe acute respiratory syndrome patients. *Virus Res*. 2009;145(2):260–9.
12. Sava RI, March KL, Pepine CJ. Hypertension in pregnancy: taking cues from pathophysiology for clinical practice. *Clin Cardiol*. 2018;41(2):220–7.
13. Center for Diseases Control and Prevention Novel Coronavirus (2019-nCoV) Real-time RT-PCR Primers and Probes. 2020. Available from: <https://www.cdc.gov/coronavirus/2019-ncov/lab/rt-pcr-panel-primer-probes>.
14. Juan J, Gil MM, Rong Z, Zhang Y, Yang H, Poon LC. Effects of coronavirus disease 2019 (COVID-19) on maternal, perinatal and neonatal outcomes: a systematic review. *Ultrasound Obstet Gynecol*. 2020;56(1):15–27.
15. Lukassen S, Chua RL, Trefzer T, Kahn NC, Schneider MA, Muley T, et al. SARS-CoV-2 receptor ACE2 and TMPRSS2 are primarily expressed in bronchial transient secretory cells. *EMBO J*. 2020;39(10):e105114.
16. Valdes G, Neves LA, Anton L, Corthorn J, Chacon C, Germain AM. Distribution of angiotensin-(1-7) and ACE2 in human placentas of normal and pathological pregnancies. *Placenta*. 2006;27(2-3):200–7.

### Author biography

**Kandukuri Malavika**, Post Graduate Resident  <https://orcid.org/0000-0002-2771-4981>

**Janaki Vellanki**, Professor

**Cite this article:** Malavika K, Vellanki J. Intrauterine deaths in pregnancies with COVID-19 infection. *Indian J Obstet Gynecol Res* 2022;9(2):193-197.