

Content available at: <https://www.ipinnovative.com/open-access-journals>

Indian Journal of Obstetrics and Gynecology Research

Journal homepage: [www.ijogr.org](http://www.ijogr.org)

## Case Report

# Successful management of vascular invasive mole by uterine artery embolization and hysterectomy - A case report

Ruchi Kalra<sup>1</sup>, Aman Kumar<sup>2</sup>, Shikha Sonker<sup>1</sup>, Anusha Devalla<sup>1,\*</sup>,  
Vishakha Singh Gill<sup>1</sup>, Priyanka Sachdeva<sup>1</sup>, Saumya Arora<sup>1</sup>

<sup>1</sup>Dept. of Obstetrics and Gynaecology, People's College of Medical Sciences, Bhopal, Madhya Pradesh, India

<sup>2</sup>Dept. of Interventional Radiology, All India Institute of Medical Sciences, Bhopal, Madhya Pradesh, India



## ARTICLE INFO

### Article history:

Received 15-02-2023

Accepted 22-03-2023

Available online 18-05-2023

### Keywords:

Gestational trophoblastic tumor

Invasive mole

Uterine artery embolization

Hysterectomy

Abnormal uterine bleeding

Vascular uterine mass

## ABSTRACT

Gestational Trophoblastic Neoplasia (GTN) is a rare disease originating from pregnancy events that have varied incidences and clinical manifestations based on regional variation. We are reporting a case of a 36-year-old woman with Invasive mole from Central India who presented with abnormal uterine bleeding with severe anemia. She had three full-term vaginal deliveries and 2 spontaneous abortions, the last conception being an abortion around 7 years back. MRI pelvis demonstrated a hypervascular uterine mass suggestive of an Invasive Mole, supported by increased serum  $\beta$ -hCG levels of 31.8 IU/ml. There was no evidence of any metastases on adjunct radiological investigations. After a thorough counselling, the enlarged vascular uterine mass was managed by uterine artery embolization (UAE) followed by simple hysterectomy. Histopathology report confirmed the diagnosis of invasive mole with villi lying in the fibrinous blood clot sheath of the syncytial, and cytotrophoblasts were seen invading the myometrium foci. The patient being in the low risk FIGO scoring, calculated was 5, chemotherapy was not deemed necessary for the patient. Serial post operative  $\beta$ -hCG along with ultrasound pelvis and chest radiogram surveillance showed favourable results with no evidence of metastases even on 6 months follow up. Being a very rare condition, a high index of suspicion with prompt timely management ensures optimum care.

This is an Open Access (OA) journal, and articles are distributed under the terms of the [Creative Commons Attribution-NonCommercial-ShareAlike 4.0 License](https://creativecommons.org/licenses/by-nc-sa/4.0/), which allows others to remix, tweak, and build upon the work non-commercially, as long as appropriate credit is given and the new creations are licensed under the identical terms.

For reprints contact: [reprint@ipinnovative.com](mailto:reprint@ipinnovative.com)

## 1. Introduction

The gestational trophoblastic disease develops in the villous tissue of the placenta as a result of abnormal fertilization. Gestational trophoblastic disease (GTD) is a broad term that includes both benign and malignant growths arising from the conceptus. The WHO clinical and pathological classification of GTN includes Villous GTD, including partial hydatidiform mole, complete hydatidiform mole, and neoplastic invasive mole. Non-villous benign lesions include hypertrophic placental site (EPS), and placental site nodule (PSN). Non-villous gestational trophoblastic tumors

include choriocarcinoma, placental site trophoblastic tumor, and epithelioid trophoblastic tumor.<sup>1-3</sup>

The incidence of GTD has a regional variation reported as low of 23 per 100,000 pregnancies in Paraguay to a high of 1,299 per 100,000 pregnancies in Indonesia. The incidence in the United States is reported to be between 110 to 120 per 100,000 pregnancies.<sup>4</sup> A study from Italy reported the incidence of GTD as 1.3 cases per 1000 pregnancies.<sup>5</sup> A study from Chennai Tamil Nadu, India reported incidence as 3.4 per 1000 deliveries.<sup>6</sup> Another study from Kerala, India reported incidence as 3.22 to 2.36 per 1000 deliveries with one peak incidence of 7.17 /1000.<sup>7</sup> Overall, it is a rare disease with varied regional incidences and clinical presentation.

\* Corresponding author.

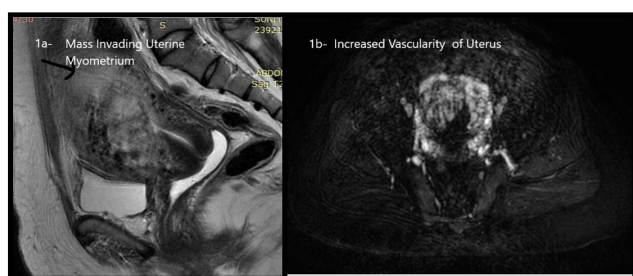
E-mail address: [anushadevalla2@gmail.com](mailto:anushadevalla2@gmail.com) (A. Devalla).

## 2. Case Report

We report a 36-year-old multiparous woman, who presented with abnormal uterine bleeding and severe anemia. She approached the gynecology outpatient department of a tertiary care hospital in central India with complaints of intermittent heavy prolonged bleeding per vaginum for the last five months. She was para 3 and gave a history of 2 abortions, last conception was a spontaneous abortion 7 years back. She was thin built woman with marked pallor and tachycardia on general examination. Her abdomen was soft, per speculum examination showed fresh bleeding from the cervical os. On bimanual examination, the uterus was uniformly enlarged, corresponding to a 10-week pregnant uterus, consistency was soft, regular contour, mobile, and bilateral fornices were non-tender with no obvious mass. She was admitted, and investigations were done. Her Hb was 6.2 gm %, anemia correction was done by transfusing 3 units of packed red cell concentrates and 2 doses of iron sucrose injections. All other investigations, liver function tests and kidney function tests, coagulation profiles (PT, APTT, INR) were normal. The X-ray chest was normal.

The pelvic ultrasonography showed a uterine mass lesion surrounded by extensive flow void suspicious of an arteriovenous malformation/ gestational trophoblastic neoplasia. Upper abdomen sonography was normal.

MRI pelvis with contrast was done for the confirmation of the diagnosis. A lobulated heterogeneous T2 intermediate to hyperintense lesion soft tissue of approx. size 1.9 x 3.1 x 4.7 cm<sup>3</sup> involving anterior myometrium with indistinct endo myometrial differentiation. The lesion was supplied by multiple serpentine T2 hypointense flow voids within uterine myometrium involving the mid and lower uterine body disrupting the junction zone, predominantly in the anterior myometrium suggesting gestational trophoblastic tumor. (Figure 1a) Left ovary showed cystic lesion 1.8 x 2.6 cm<sup>2</sup> most likely dominant follicle or functional cyst.

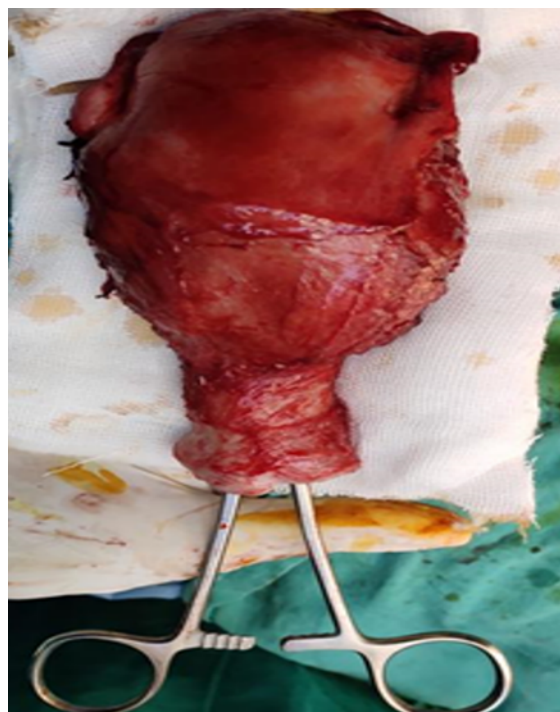

**Fig. 1: a):** MRI pelvis -Uterine Mmass invading myometrium; **b):** Vascular uterus

Serum  $\beta$ -hCG sample was 31.8 IU/ml to corroborate the radiological findings, history of abortions and clinical examination. To reduce the anticipated heavy intraoperative blood loss, the patient was referred for UAE.(Figure 1 b)

The bilateral UAE was done under local anesthesia and vascular access was done from the right femoral artery. Bilateral uterine arteries were embolized using 500-700 Poly Vinyl Alcohol and gel foam and complete devascularization was attained.

Following UAE, a total abdominal hysterectomy with bilateral salpingectomy was done under regional anesthesia the next day. Intraoperatively, the uterus was enlarged and very soft in consistency, 12 x 8 cm in size and bilateral fallopian tubes uniformly hypertrophied. There was increased vascularity and blood loss was higher than usual procedure, despite a successful UAE. (Figure 2)

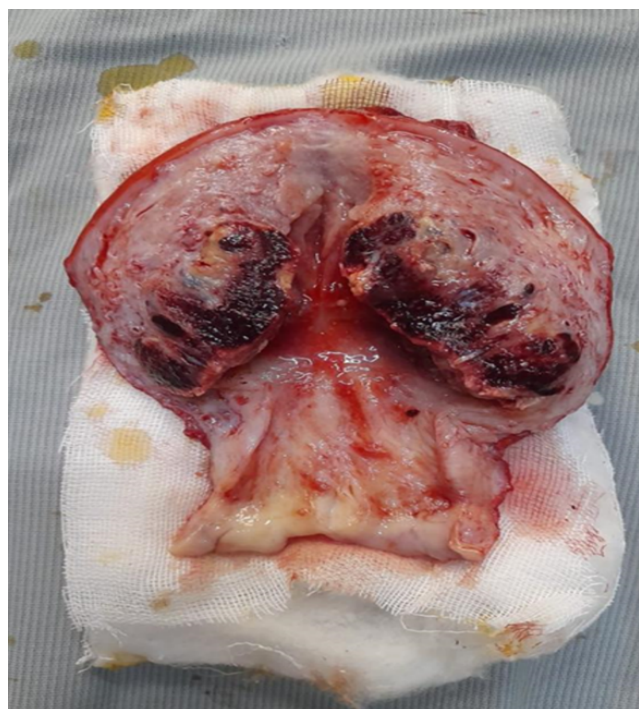


**Fig. 2:** Gross specimen of enlarged uterus

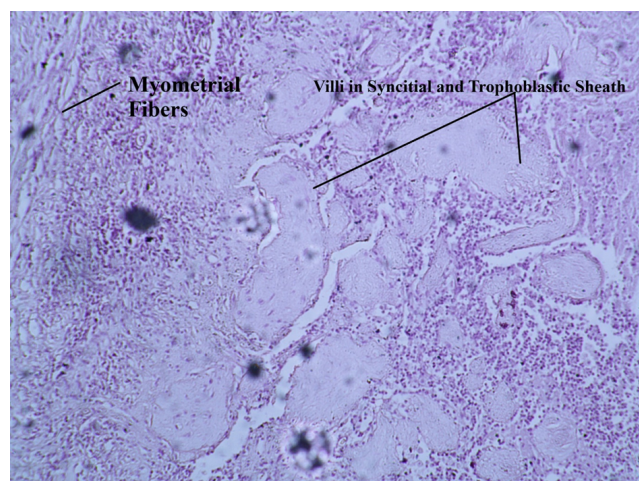
On the cut section of the specimen of the uterus, there was a polypoid mass of 6x3.5 cm with a shaggy-greyish appearance extending from mid-uterine into the upper uterine cavity.(Figure 3)

Postoperatively, the patient recovered uneventfully, and she was discharged on day 10 after stitch removal. Serum  $\beta$ -hCG levels done on the day 7th of surgery were 3 IU/ml (normal levels).

Histopathology reported endometrium to be in secretory phase. Multiple sections through the polypoid mass 6 x 3.5cm revealed abundant degenerated villi lying in the fibrinous blood clot and sheets of syncytial and cytotrophoblasts were seen invading the myometrium foci, admixed with neutrophils and cervix showing chronic inflammatory infiltrate. Findings were suggestive of Invasive mole. (Figure 4)



**Fig. 3:** Cut-open specimen showing mass invading uterine myometrial tissue



**Fig. 4:** Histopathology slide showing myometrium invasion by villi

FIGO staging and WHO risk scoring were used to prognosticate and guide further management. The disease was limited to the uterus and the score was based on the prognostic factors viz. i) Age below 40 years (score 0); ii) Previous pregnancy was an abortion (score 1); iii) Months since the last pregnancy more than 12 months (score 4); iv) Pre-treatment hCG (IU/mL) (Score 0); v) Largest tumour size, including the uterus based on MRI report <3 cm (Score 0); vi) Site of spread none (score 0); vii) Number of

tumours that have spread none (Score 0); viii) The number of drugs used to treat the tumor that has not worked none (score 0). The Cumulative risk score was 5 (Low Risk; score less than 7). Hence, with the diagnosis of Invasive Mole, Stage 1, disease confined to the uterus, Risk Score 5 (Low-risk score) with no distant metastasis, normalization of  $\beta$  HCG values after 7 days of hysterectomy, and patient willing to follow up, the decision to defer chemotherapy was taken after discussion with the patient. She has been under regular follow-up for 6 months now since surgery, serum  $\beta$ -hCG levels are within normal limits and the patient has no complaints.

### 3. Discussion

The patient presented as abnormal uterine bleeding with a vascular uterine mass. Her last pregnancy was a spontaneous abortion. The initial sonography report aroused the suspicion of arteriovenous malformation and MRI pelvis helped to reach a preoperative diagnosis suggesting a gestational trophoblastic neoplasia, where the tumor was invading the myometrium. The left ovary was cystic. Her Serum  $\beta$ -hCG levels were raised which correlated with the clinical and radiological findings. The uterus was enlarged and vascular, and she had a history of heavy bleeding per vaginum. Taking the patient's wishes into consideration, she was planned for hysterectomy as the primary treatment since she was not keen on fertility. The final diagnosis was clinched on the histopathological report that showed an invasive mole characterized by syncytial and cytotrophoblasts lined villi invading the myometrial tissue. As the  $\beta$ -hCG levels returned to normal value on the 7<sup>th</sup> day post-surgery and the patient was keen on a regular follow-up, the single agent Methotrexate chemotherapy was deferred; the decision of which was based on the discussion of the patient with treating clinicians. The patient was under regular monthly follow-up till 6 months after surgery. Her serum  $\beta$ -hCG levels, sonography of the whole abdomen, and X Ray chest were normal to date.

In Gestational trophoblastic tumors, chemotherapy is the primary line of therapy but in those subgroups of women who are not desirous of pregnancy, hysterectomy can be a feasible option. Bolze PA et al. have reported a study where 74 cases were treated at a French hospital by simple hysterectomy as first-line treatment without salvage chemotherapy and their serum  $\beta$  HCG levels came to normal similar to our case.<sup>8</sup>

Another study by C. K. Ramesan et al. reported from South India, more hysterectomies were done in the high-risk group cases for either intra peritoneal bleeding or vaginal bleeding, mostly diagnosed as choriocarcinoma or invasive mole and chemotherapy cycles were given in those patients.<sup>9</sup> They suggested hysterectomy as a way to reduce tissue bulk and thus reduce chemoresistance. Ngan HY et al. in their report have mentioned risk scores

of 5-6 are more chemo-resistant requiring multiple agents for chemotherapy.<sup>10</sup> In our case, the persistent normal levels of serum  $\beta$  HCG were reassuring with normal abdominal ultrasound and chest radiogram with patient willing for a long term follow up, hence the decision to defer chemotherapy. Braga A et al. have reported no cases of death in choriocarcinoma in patients not given chemotherapy.<sup>11</sup> The guidelines recommend risk assessment of individual cases by FIGO 2000 based risk scoring and Modified WHO Risk Scoring System as Adapted by FIGO, the decision to be done on an individual basis.<sup>2,3,12–14</sup>

The two commonly used single-agent chemotherapeutic drugs are methotrexate and actinomycin D. A large randomized trial by the Gynaecologic Oncology Group compared giving weekly intramuscular methotrexate 30 mg/m<sup>2</sup> as a bolus dose comparing with actinomycin D 1.25mg/m<sup>2</sup> in gestational trophoblastic neoplasia patients. Actinomycin D results were better in terms of efficacy but actinomycin D has more serious side effects.<sup>15</sup> National Comprehensive Cancer Network guidelines have recommended methotrexate or methotrexate -folinic acid regime as first-line and actinomycin D be reserved for those patients where methotrexate therapy is contraindicated.<sup>16</sup>

A multidrug therapy consisting of EMA–CO (etoposide, methotrexate, and actinomycin-D alternate used with cyclophosphamide, and vincristine) as preferred therapy in high-risk score cases with metastasis to liver, lung, or brain. The surgery is required in cases of intraperitoneal hemorrhage due to uterine perforation or uncontrolled vaginal bleeding, or to treat chemo-resistant tumors like placental site trophoblastic tumors and epithelioid trophoblastic tumors.<sup>17,18</sup>

#### 4. Conclusion

Through this case, the authors would like to highlight gestational trophoblastic disease as a possible differential diagnosis of abnormal uterine bleeding, especially if presenting as a vascular uterine mass. This condition can have variable manifestations and can present years after a pregnancy event. A high index of clinical suspicion is necessary to avoid unnecessary delay in diagnosis and treatment. Once diagnosed, patient's fertility considerations and clinical scenario should guide individualized management, that might necessitate hysterectomy and/or multi-agent chemotherapy.

#### 5. Source of Funding

No funding was required for the case.

#### 6. Conflict of Interest

The authors declare that they have no competing interests.

#### Acknowledgment

We acknowledge Dr. Rashmi Nichlani for her contribution in Histopathology diagnosis and for providing photographs.

#### References

1. Ngan HYS, Seckl MJ, Berkowitz RS. Update on the diagnosis and management of gestational trophoblastic disease. *Int J Gynaecol Obstet.* 2018;143(Suppl 2):79–85.
2. Tempfer C, Horn LC, Ackermann S, Beckmann MW, Ditttrich R, Eienkel J, et al. Gestational and Non-gestational Trophoblastic Disease. Guideline of the DGGG, OEGGG and SGGG (S2k Level, AWMF Registry No.032/049, December 2015). *Geburtshilfe Frauenheilkd.* 2015;76(2):134–44.
3. Tidy J, Seckl M, Hancock BW. Management of Gestational Trophoblastic Disease. *Int J Obstet Gynaecol.* 2021;128:e1–e27. doi:10.1111/1471-0528.16266.
4. Altieri A, Franceschi S, Ferlay J, Smith J, and CLV. Epidemiology and aetiology of gestational trophoblastic diseases. *Lancet Oncol.* 2003;4(11):670–8.
5. Capobianco G, Tinacci E, Saderi L, Dessole F, Petrillo M. High Incidence of Gestational Trophoblastic Disease in a Third-Level University-Hospital, Italy: A Retrospective Cohort Study. *Front Oncol.* 2021;11:684700. doi:10.3389/fonc.2021.684700.
6. Rakesh MP, Kalaichelvi K, Gangadharan G, Sreedath V. A profile of cases of gestational trophoblastic neoplasia at a tertiary care centre in South India. *Int J Reprod Contracept Obstet Gynecol.* 2020;9(5):1788–93.
7. Chandran JR, Devi DS, Gorhatti SN. Epidemiology of gestational trophoblastic disease at a tertiary hospital in India over last 8 years. *J SAFOG South Asian Fed Obstet Gynaecol.* 2019;11(1):27–9.
8. Bolze PA, Mathe M, Hajri T, You B, Dabi Y, Schott AM, et al. First-line hysterectomy for women with low-risk non-metastatic gestational trophoblastic neoplasia no longer wishing to conceive. *Gynecol Oncol.* 2018;150(2):282–7.
9. Ramesan CK, Thomas DS, Sebastian A, Thomas V, Thomas A, George R, et al. Role of Hysterectomy in Gestational Trophoblastic Neoplasia. *Indian J Surg Oncol.* 2021;12(2):386–90.
10. Ngan HYS, Seckl MJ, Berkowitz RS, Xiang Y, Golfier F, Sekharan PK, et al. Update on the diagnosis and management of gestational trophoblastic disease. *Int J Gynecol Obstet.* 2018;143(Suppl 2):79–85.
11. Braga A, Mora P, DeMelo AC, Amim-Junior J, Filho JR, Seckl MJ, et al. Challenges in the diagnosis and treatment of gestational trophoblastic neoplasia worldwide. *World J Clin Oncol.* 2019;10(2):28–37.
12. Santaballa A, García Y, Herrero A, Láinez N, Fuentes J, DeJuan A, et al. SEOM clinical guidelines in gestational trophoblastic disease. *Clin Transl Oncol.* 2017;20(1):38–46.
13. Elias KM, Berkowitz RS, Horowitz NS. State-of-the-Art Workup and Initial Management of Newly Diagnosed Molar Pregnancy and Postmolar Gestational Trophoblastic Neoplasia. *J Natl Compr Canc Netw.* 2019;17(11):1396–1401.
14. Soper JT. Gestational Trophoblastic Disease: Current Evaluation and Management. *Obstet Gynecol.* 2021;137(2):355–70.
15. Osborne RJ, Filiaci V, Schink JC, Mannel RS, Secord AA, Kelley JL, et al. Phase III trial of weekly methotrexate or pulsed dactinomycin for low-risk gestational trophoblastic neoplasia: a gynecologic oncology group study. *J Clin Oncol.* 2011;29(7):825–31.
16. Abu-Rustum NR, Yashar CM, Bean S, Bradley K, Campos SM, Chon HS, et al. Gestational Trophoblastic Neoplasia, Version 2.2019, NCCN Clinical Practice Guidelines in Oncology. *J Natl Compr Canc Netw.* 2019;17(11):1374–91.
17. Turan T, Karacay O, Tulunay G, Boran N, Koc S, Bozok S, et al. Results with EMA/CO (etoposide, methotrexate, actinomycin D, cyclophosphamide, vincristine) chemotherapy in gestational trophoblastic neoplasia. *Int J Gynecol Cancer.* 2006;16(3):1432–8.

18. Pushpalatha K, Singh B, Devalla A, Sasidharan S, Panwar H. Spontaneous Uterine Perforation in a Choriocarcinoma Presenting with Pyoperitoneum. *J South Asian Feder Obst Gynae.* 2021;13(4):272–4.

**Vishakha Singh Gill**, Assistant Professor

**Priyanka Sachdeva**, Resident

**Saumya Arora**, Resident

### Author biography

**Aman Kumar**, Assistant Professor

**Shikha Sonker**, Assistant Professor

**Anusha Devalla**, Assistant Professor

**Cite this article:** Kalra R, Kumar A, Sonker S, Devalla A, Gill VS, Sachdeva P, Arora S. Successful management of vascular invasive mole by uterine artery embolization and hysterectomy - A case report. *Indian J Obstet Gynecol Res* 2023;10(2):206-210.