

Comparative Study of Two Different Techniques of Laparoscopic Stripping in Ovarian Endometrioma – A Randomized control trial

Hema Priya L^{1,*}, Prathap T.²

^{1,2}Brindavan Hospital, Mysuru

***Corresponding Author:**

Email: drpriya_911@hotmail.com

Abstract

Laparoscopic ovarian cystectomy is the technique of choice in patients with large ovarian endometriomas. However, post operative residual ovarian function remains a major concern.

Objectives: The aim of this prospective, randomized study was to compare two different techniques of stripping at the original adhesion site and at the hilus. We also aimed to determine which technique of ovarian cystectomy causes least tissue damage, by histopathology analysis and by determining the residual ovarian volume.

Materials and Methods: 32 patients were enrolled, who had laparoscopically confirmed endometriomas > 3 cm in diameter. The patients were randomized into two groups, by a computer generated random number table. Two different techniques (direct stripping vs. excision of a circular rim of tissue) were compared at the original adhesion site (step 1). At step 2, all patients underwent randomization again, and two different techniques (completion of stripping vs. bipolar coagulation and cutting with scissors) were compared at the hilus. Operative time and operative difficulty were evaluated at both steps by the same surgeon. Histopathology confirmation of the loss of normal ovarian tissue was recorded at the original adhesion site, intermediate part and at the hilus. Residual ovarian volume was calculated at the end of six months.

Results: The mean operating time and difficulty showed no significant difference at both step 1 and step 2 with either technique. However complication rate (hemorrhage) was higher at step 2 in the direct stripping group. On histopathology, primordial follicles were identified in similar number of patients in each group. The residual ovarian volume six months post operatively showed no significant difference in both groups.

Conclusion: Both techniques of cystectomy are tissue sparing and can be safely used.

Keywords: Endometrioma, Infertility, Chocolate cyst, Laparoscopic cystectomy, Ovarian volume

Access this article online	
Quick Response Code:	Website: www.innovativepublication.com
	DOI: 10.5958/2394-2754.2016.00023.0

Introduction

Laparoscopy is the gold standard for the diagnosis and treatment of endometriosis. There are several techniques which have been described for treatment of ovarian endometriomas. However, cystectomy has proven to be the best technique as it is associated with good conception rates and pain relief^(1,23). The concern with cystectomy is that it may lead to inadvertent excision of normal ovarian tissue and decreased ovarian reserve. Various methods of stripping the cyst wall have been described, which prevent damage to normal ovarian tissue⁽¹⁴⁾. The aim of this study was to compare two different surgical techniques at the beginning of the stripping procedure (at the cyst original adhesion site) and two different techniques at the end of stripping procedure (at the ovarian hilus).

Materials and Methods

This prospective, single blind, randomized study was carried out at the Department of Obstetrics and Gynecology at Brindavan Hospital, Mysuru, India. Institutional approval was obtained, and informed consent was taken from the participants.

Thirty two women (n = 32) in the age group of 15 to 40 years with a clinical and ultrasonographic diagnosis of endometrioma >3 cm participated in the study. Laparoscopic confirmation of the diagnosis was done before recruitment. Women with past history of tuberculosis, previous ovarian cystectomy, or conversion to laparotomy were excluded from the study.

A detailed workup; including history, clinical examination, routine pre operative investigations, and trans abdominal or trans vaginal ultrasonography was done. Dimensions of both ovaries and the size of the endometrioma were measured. The ovarian volume was calculated by means of prolate ellipsoid formula:

$$\text{Volume} = 0.5233 \times \text{LD} \times \text{TD} \times \text{APD} \text{ in cu cm.}$$

Where, LD- Longitudinal diameter,

TD- Transverse diameter,

APD - Antero posterior diameter.

Similarly the volume of each ovarian cyst was measured.

Residual ovarian volume was calculated with the formula:

Residual volume = Ovarian volume - cyst volume.

Under general anesthesia, a 10 mm laparoscope was inserted through the umbilicus and two 5 mm trocars through the right and left flanks. The extent and severity of disease was assessed and ASRM grading was done. The endometriotic cyst was then mobilized from the ovarian fossa and the cyst ruptured. Randomization was done using a computer generated random number table. Direct stripping was done at the original adhesion site, for patients in group 1 where the ovarian parenchyma and the endometrioma were densely adherent to each other. In group 2, a disc of ovarian tissue was excised, followed by stripping. The plane of cleavage was identified and stripping was continued by exerting traction in opposite directions for the rest of the cyst wall.

At the ovarian hilus, a second randomization was done using a computer generated random number table. The cyst wall was stripped off using traction till it was completely removed, in group 1. Bipolar coagulation was done at the pedicle of the cyst wall and then it was cut with scissors, in patients of group 2.

We recorded the total operating time and partial times for the first and second procedures, separately. The same surgeons assessed the operative difficulty, using three criteria: presence of dense or flimsy adhesions, complete removal of the cyst wall, and blood loss. Complications during the procedure were recorded.

Three separate specimens from the excised cyst wall- the initial, intermediate and final portion, were sent for histopathologic examination. The amount of normal ovarian tissue removed with either technique in both the initial and final procedure was documented.

Monthly follow up was done, for six months by clinical examination and trans abdominal or trans vaginal ultrasonography. Pregnancies occurring during the follow up period were recorded. Six months after surgery, we calculated residual ovarian volume in both groups.

Statistical Analysis: Randomization was done at both steps using a computer generated random number table. The surgeon was made aware of the technique to be used only at the beginning of each step. Stata software was used for analysis of the data recorded. The Student's *t*-test and the χ^2 -test were used for continuous and categorical variables respectively. The Fisher's exact test was used for evaluation of operative difficulty. The Kruskal-Wallis test was used to evaluate the difference in quality of ovarian tissue removed at the three different cyst sites. Statistical significance was set at a *P* value less than 0.05.

Results

Patient characteristics: The age of the patients ranged from 19–36 years, with the mean being 27.18 years. Two patients were ≤ 20 years of age and 1 patient > 35 years. 6 patients were unmarried, who presented with dysmenorrhea. 26 were married of which 21 patients were nulliparous, and 5 were parous. Two patients opted for tubal sterilization simultaneously. 15 patients had unilateral cysts, 9 on the right side, and 6 on the left. 17 patients had bilateral chocolate cysts. All patients had stage 3 or 4 disease according to the revised ASRM scoring system. The ASRM scores ranged from 22 to 144 in both groups with the mean ASRM score being 63.

The mean residual volume was 14.07cc on the right side, in group 1 and 14.58cc in group 2. The mean residual volume of the left ovary was 13.61cc in group 1 and 16.3cc in group 2.

Table 1: Pre-operative residual ovarian volume

Residual Volume (CC)	Group 1		Group 2	
	Right	Left	Right	Left
1 – 5	0	2 (12.5%)	0	0
6 – 10	2 (12.5%)	3 (18.75%)	2 (12.5%)	1 (6.25%)
11 – 15	6 (37.5%)	6 (37.5%)	9 (56.25%)	5 (31.25%)
16 – 20	7 (43.75%)	3 (18.75%)	2 (12.5%)	7 (43.75%)
21 – 25	1 (6.25%)	1 (6.25%)	2 (12.5%)	2 (12.5%)
26 – 30	0	1 (6.25%)	1 (6.25%)	1 (6.25%)

The primary outcomes were to evaluate operative time, operative difficulty and the loss of normal ovarian tissue, in terms of loss of follicles and residual ovarian volume.

Recurrence and conception rates were recorded as secondary outcomes.

Step 1 (at the original adhesion site: direct stripping vs circular excision): The mean operative time in group 1 was 35.9 minutes, and 37.5 minutes in group 2 (*P* = 0.6). The operative difficulty was graded as easy, moderately difficult and difficult. The *P* value was determined to be 0.8 using the Fisher's exact test. No operative complications were noted in any patient in both the groups.

Step 2 (at the hilus: continuation of stripping vs cutting and coagulation): The mean operative time in the first group was 37.8 minutes, vs. 29 minutes in the second group (P = 0.8). Similarly there was no significant difference in the operative difficulty (P = 1.0). Six patients (18.7%) in group 1 and one (3.1%) in group 2 had excessive bleeding at the hilus, which was successfully controlled by coagulation with bipolar cautery in all patients.

Histo Pathological Analysis of the Cyst Wall: All specimens were divided into 3 parts; the original adhesion site, an intermediate part, and the hilar region were separately analyzed. Characteristic endometrial stroma and glands were seen in only 1 specimen, at the intermediate part in group 1.

Table 2: Histopathologic analysis for no. of follicles

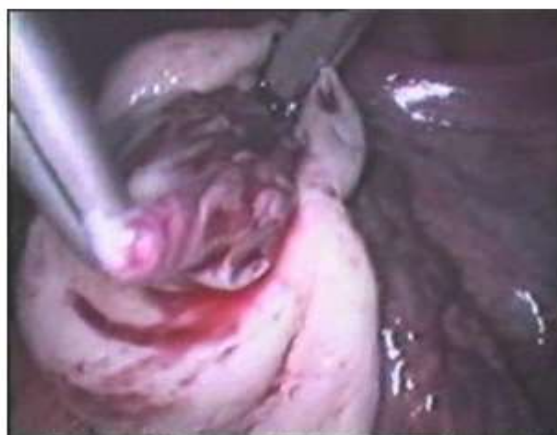Grading of follicles	Original Adhesion Site		Intermediate Part		Hilus	
	Stripping (n = 16)	Circular excision (n = 16)	Stripping (n = 16)	Circular excision (n = 16)	Stripping (n = 16)	Coag & cutting (n = 16)
No follicle	15(93.75%)	15(93.75%)	12(75%)	15(93.75%)	13(81.25%)	13(81.25%)
Primordial	1(6.25%)	1(6.25%)	4(25%)	1(6.25%)	2(12.5%)	3(18.75%)
Primary	0	0	0	0	1(6.25%)	0

No secondary follicles, or patterns similar to those present in the normal ovary could be identified.

Residual ovarian volume: The mean residual ovarian volume at the end of the follow up period ranged from 11.3cc to 13.7 cc. There was no significant difference in the residual ovarian volume between the two groups. The mean difference between the pre operative and post operative residual ovarian volume ranged from 1.9 cc to 3.1 cc in either group, on both sides. This did not prove to be statistically significant. However patients who underwent circular excision of a rim of tissue at the original adhesion site had a better outcome in terms of post op residual ovarian volume.

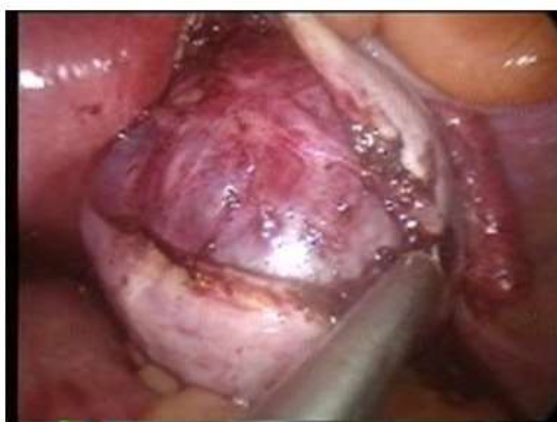Six (18.75%) patients had recurrence of the chocolate cyst within six months. The Fisher exact test was used to compare the recurrence rates between two groups and there was no significant difference with either technique at the original adhesion site or at the hilus.

Twenty three patients were being investigated for infertility, of which 2 patients (8.7%) conceived spontaneously. The first was at four months follow up, in group 2 followed by stripping at the hilus. The second patient underwent stripping at the original adhesion site followed by coagulation and cutting.



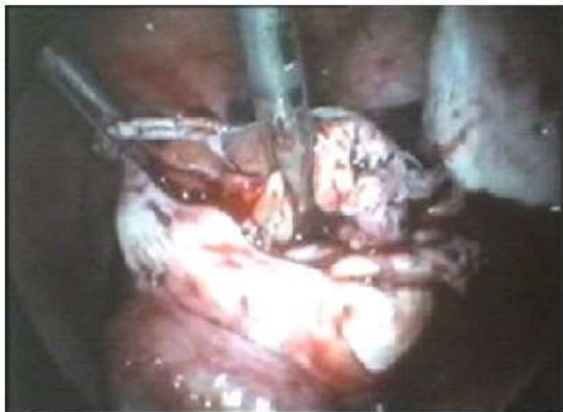Direct stripping at original adhesion site

Fig. 1



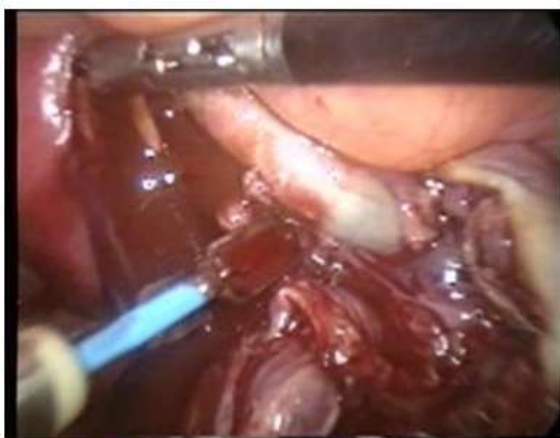Excision of circular rim of tissue at original adhesion site

Fig. 2



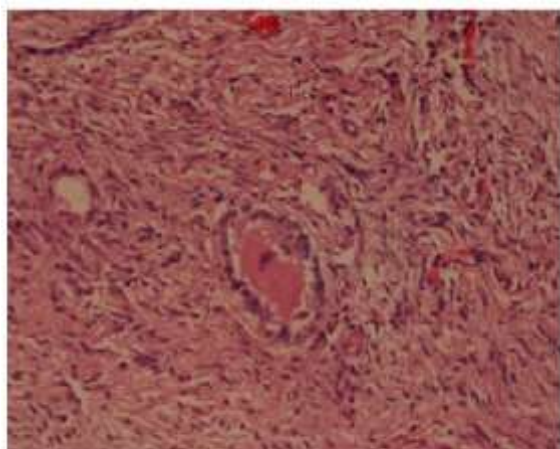
Completion of stripping upto hilus

Fig. 3



Bipolar coagulation & cutting at hilus

Fig. 4



Photomicrograph showing Primary Follicle

Fig. 5

Discussion

There have been several changes in the surgical management of endometriosis. Laparotomy has been almost completely replaced by laparoscopy. Various techniques such as burning of all visible endometriotic spots, drainage of the chocolate cyst, and excision of the cyst wall have been described. Various large randomized studies have proved that ablation of all visible endometriotic spots improve pregnancy rates in women with infertility⁽¹³⁾, and reduce pelvic pain in symptomatic patients^(20,21).

Chocolate cysts > 3 cm in size must be removed. Different approaches; such as laser vaporization of the cyst wall (2, 4, 21), drainage and coagulation, and cyst wall excision have been described^(3,14,18).

Ovarian cystectomy is much superior to drainage and ablation, with regard to recurrence of symptoms, subsequent fertility as well as recurrence of the endometrioma, as described in a Cochrane review⁽⁸⁾.

There are various techniques of laparoscopic ovarian cystectomy. Subsequent conception, recurrence rates and ovarian function have been studied with the different methods. Ovarian cystectomy by stripping the cyst wall⁽¹⁹⁾ is the technique of choice, as it completely removes the endometriotic tissue. However, it is more traumatic and may lead to loss of ovarian reserve and function. In 1996 Donnez et al suggested that endometrioma stripping may result in loss of viable ovarian cortex during surgery⁽⁴⁾. In another large study, Hachisuga et al reported that normal ovarian stroma was attached to the resected side of the capsule in majority of the endometriomas⁽⁷⁾.

When Muzzi and co-workers compared laparoscopic excision of endometriomas with other benign ovarian cysts; they found that, in patients with dermoids, serous and mucinous cystadenomas, normal ovarian tissue was inadvertently removed in only 6% of patients. However, in patients with chocolate cysts, normal ovarian tissue with primordial follicles was seen in 54%-69% of specimens⁽¹⁵⁾. This suggests that ovarian reserve is more affected following cyst excision of endometriomas, rather than other benign ovarian cysts.

A similar study, which compared two different techniques of stripping at the beginning and at the hilar region showed that normal ovarian tissue was seen in the excised cyst wall of endometriomas, in majority of the cases. At initial adhesion site more ovarian tissue was removed with the circular excision technique. However, there was no difference in the quality of ovarian tissue inadvertently removed, with both the techniques at the initial or at the final part of the procedure⁽¹⁷⁾.

In the present study, each specimen was examined at three sites; the original adhesion site, an intermediate part, and the hilar region. We found no significant difference in the number of primordial or primary follicles in any of the three specimens, irrespective of

the technique used during surgery. No secondary follicles, or patterns similar to those present in the normal ovary could be identified in these specimens. Thus we observed that neither technique is associated with significant loss of normal functional ovarian tissue.

A comparative study was done by Ho et al; in which 32 women undergoing controlled ovarian hyper stimulation were studied. A significant reduction in ovarian reserve was seen in women previously treated surgically for unilateral ovarian endometrioma than those with normal ovaries. It was concluded that surgery for ovarian endometrioma damages ovarian reserve⁽¹⁰⁾. Esinler studied 57 patients with endometriomas and concluded that laparoscopic endometriotic cystectomy reduces the ovarian reserve. However, in this study, diminished ovarian reserve was not associated with impaired pregnancy outcome in future IVF cycles⁽⁵⁾.

There are different studies which have been done to assess the ovarian reserve following cystectomy in patients with chocolate cysts, and the response of the residual ovarian tissue to controlled hyper stimulation. Reduction in oocyte quality, and lower fertilization rates have been reported by some investigators⁽²⁵⁾. It was hypothesized that ovarian endometriomas produce toxic substances that adversely affect cleavage of oocytes and fertilization.

Hemmings demonstrated that cyst wall coagulation was more tissue conserving when compared to cystectomy⁽⁹⁾. In a study by Loh et al, a reduced follicular response in natural and CC stimulated cycles, following ovarian cystectomy. However, when stimulated with gonadotropins, a good number of follicles were seen⁽¹¹⁾.

Laparoscopic ovarian cystectomy does not affect ovarian reserve as documented by E2 levels, number of follicles, oocytes retrieved, number and quality of embryos transferred, and clinical pregnancy rate⁽¹²⁾.

In our study, we recorded the residual ovarian volume at the end of six months, as a measure of the ovarian reserve. The difference in the pre op and post op residual ovarian volume was not statistically significant. However patients who underwent circular excision of a rim of tissue at the original adhesion site had a better outcome in terms of post op residual ovarian volume. Thus it was concluded that both techniques of laparoscopic stripping in ovarian endometrioma are equally good in terms of technical feasibility and are tissue sparing.

References

1. Beretta P, Franchi M, Ghezzi F, Busacca M, Zupi E and Bolis P. Randomized clinical trial of two laparoscopic treatments of endometriomas: cystectomy versus drainage and coagulation. *Fertil Steril* 1998;70:1176 - 1180.
2. Brosens IA, Van Ballaer P, Puttemans P and Deprest J. Reconstruction of the ovary containing large

- endometriomas by an extraovarian endosurgical technique. *Fertil Steril* 1996;66:517-521.
3. Canis M, Mage G, Wattiez A, Chapron C, Pouly JL and Bassil S. Second look laparoscopy after laparoscopic cystectomy of large ovarian endometriomas. *Fertil Steril* 1992;58,611-619.
4. Donnez J, Nisolle M, Gillet N, Smets M, Bassil S, Casanas-Roux F. Large ovarian endometriomata. *Human Reproduction* 1996;11:641-646.
5. Esinler I, Bozdogan G, Aybar F, Bayar U, Yarali H. Outcome of in vitro fertilization/intracytoplasmic sperm injection after laparoscopic cystectomy for endometriomas. *Fertil Steril*. 2006 Jun;85(6):1730-5.
6. Gambone JC, DeCherney AH. Surgical treatment of minimal endometriosis. *N Engl J Med* 1997;337:269- 70.
7. Hachisuga T, Kawarabayashi T. Histopathological analysis of laparoscopically treated ovarian endometriotic cysts with special reference to loss of follicles. *Human Reproduction* 2002;17:432-5.
8. Hart RJ, Hickey M, Maouris P. Excisional surgery versus ablative surgery for ovarian endometriomata (Cochrane Review) In *The Cochrane Library*, Issue 4, 2007. John Wiley & sons.
9. Hemmings R, Bissonnette F, Bouzayen R. Results of laparoscopic treatments of ovarian endometriomas: laparoscopic ovarian fenestration and coagulation. *Fertility and Sterility* 1998;70:527-9.
10. Ho HY, Lee RK, Hwu YM, Lin MH, Su JT and Tsai YC (2002) Poor response of ovaries with endometrioma previously treated with cystectomy to controlled ovarian hyperstimulation. *J Assist Reprod Genet* 19,507-511.
11. Loh FH, Tan AT, Kumar J and Ng SC. Ovarian response after laparoscopic ovarian cystectomy for endometriotic cysts in 132 monitored cycles. *Fertil Steril* 1999;72,316-321.
12. Marconi G, Vilela M, Quintana R and Sueldo C. Laparoscopic ovarian cystectomy of endometriomas does not affect the ovarian response to gonadotropin stimulation. *Fertil Steril* 2002;78:876-878.
13. Marcoux S, Maheux R, Be'rube' S, and the Canadian Collaborative Group on Endometriosis. Laparoscopic surgery in infertile women with minimal or mild endometriosis. *N Engl. J Med* 1997;337:217-22.
14. Martin DC. Laparoscopic treatment of ovarian endometriomas. *Clin Obstet Gynecol* 1991; 34, 452-459.
15. Muzii L, Bianchi A, Croce C, Mancini N and Benedetti Panici P. Laparoscopic excision of ovarian cysts: is the stripping technique a tissue-sparing procedure? *Fertil Steril* 2002;77,609-614.
16. Muzii L, Bellati F, Palaia I, Plotti F, Mancini N, Zullo M.A, Angioli R and Panici P.B, Laparoscopic stripping of endometriomas: a randomized trial on different surgical techniques. Part I: Clinical results *Human Reproduction* 2005;20(7):1981-1986.
17. Muzii L, Bellati F, Bianchi A, Palaia I, Mancini N, Zullo M.A, Angioli R and Panici P.B, Laparoscopic stripping of endometriomas: a randomized trial on different surgical techniques. Part II: pathological results *Human Reproduction* 2005 20(7):1987-1992.
18. Reich H and McGlynn F (1986) Treatment of ovarian endometriomas using laparoscopic surgical techniques. *J Reprod Med* 31,577-584.
19. Semm K. Course of endoscopic abdominal surgery. In Semm K, Freidrich ER, eds. *Operative manual for endoscopic abdominal surgery*. Chicago year book medical, 1 Sutton CJG, Ewen SP, Whitelaw N, Haines P. Prospective, randomized, double-blind controlled trial of laser laparoscopy in the treatment of pelvic pain

- associated with minimal, mild, and moderate endometriosis. *Fertil Steril* 1994;62:696–700.
20. Sutton CJG, Ewen SP, Whitelow N, Haines P. Prospective, randomized, double-blind controlled trial of laser laparoscopy in the treatment of pelvic pain associated with minimal, mild, and moderate endometriosis. *Fertil Steril* 1994;62:696–700.
 21. Sutton CJ, Ewen SP, Jacobs SA and Whitelaw NL. Laser laparoscopic surgery in the treatment of ovarian endometriomas. *J Am Assoc Gynecol Laparosc* 1997;4:319–323.
 22. Sutton CJG, Pooley AS, Ewen SP, Haines P. Follow-up report on a randomized controlled trial of laser laparoscopy in the treatment of pelvic pain associated with minimal to moderate endometriosis. *Fertil Steril*, 1997;68:1070–4.
 23. Vercellini P, Chapron C, De Giorgi O, Consonni D, Frontino G, Crosignani PG. Coagulation or excision of ovarian endometriomata? *American Journal of Obstetrics and Gynecology* 2003;188:606–10.
 24. Wyns C and Donnez J. Laser vaporization of ovarian endometriomas: the impact on the response to gonadotropin stimulation. *Gynecol Obstet Fertil* 2003;31:337–342.
 25. Yanushpolsky EH, Best CL, Jackson KV, Clarke RN, Barbieri RL, Hornstein MD. Effects of endometriomata on oocyte quality, embryo quality, and pregnancy rates in in vitro fertilization cycles: a prospective, case-controlled study. *Journal of Assisted Reproduction and Genetics* 1998;15:193–7.