

Content available at: <https://www.ipinnovative.com/open-access-journals>

Indian Journal of Obstetrics and Gynecology Research

Journal homepage: [www.ijogr.org](http://www.ijogr.org)

## Original Research Article

## To compare the effectiveness of Pap smear, VIA and colposcopy for screening of premalignant lesions of cervix

Mahin Fatima Faridi Khan<sup>1,\*</sup>, Bhavana Gupta<sup>1</sup>, Meenakshi Srivastava<sup>1</sup>, Kusum Lata<sup>1</sup>, Vibha Singh<sup>1</sup>, Twinkle<sup>1</sup><sup>1</sup>Integral Institute of Medical Science and Research, Lucknow, Uttar Pradesh, India

## ARTICLE INFO

## Article history:

Received 17-05-2023

Accepted 12-06-2023

Available online 24-08-2023

## Keywords:

Colposcopy

PAP smear

Malignant lesions

## ABSTRACT

**Background:** Cervical cancer poses a major public health challenge, particularly in developing nations, where around 80% of cases are diagnosed. Despite being a preventable disease, it remains highly prevalent, with over 600,000 new cases and 340,000 deaths reported worldwide in 2020. According to the GLOBOCAN 2020 data, cervical cancer represented 9.4% of all cancer cases and 18.3% of new cancer cases in India. However, cervical cancer is now considered preventable through cervical screening and curable, particularly if detected early, which emphasizes the importance of "prevention is better than cure". The current research utilized Pap smear, VIA, and colposcopy to identify abnormal cervical appearances indicative of carcinoma.

**Materials and Methods:** During a span of 18 months, a study was carried out on 329 women who were attending the OPD clinic at Integral Institute Of Medical Sciences and Research hospital. With the participants' consent, the women underwent VIA, Pap smear and colposcopy tests as part of the study.

**Results:** In the study 61 (18.5%) cases were found positive in VIA findings and 268 (81.5%) were VIA negative. In this study 85.7% of Pap smears were normal, out of 18.5% VIA positive, 77% of pap smears were abnormal 23 (37.5%) ASC (NOS/US), 8 (13.1%) AGC and AGC NOS, 6 (9.1%) AEC, 5 (8.2%) LSIL, 5 (8.2%) HSIL and out of 268 VIA negative all Pap were normal (100%). 61 colposcopies were done, out of 18.5% VIA positive, 73.6% colposcopies were positive 29 were CIN I (47.5%), 10 were CIN III (16.3), 6 were CIN II (9.8%) and 13.2% were normal and 13.2% were cervicitis. Biopsy was done in all colposcopy patients, 49.2% were CIN I, 27% were chronic cervicitis, 10% were CIN I, 3.2% were squamous cell carcinoma and 1.6% were adenocarcinoma in situ and 1.6% were ex show no atypia.

**Conclusion:** VIA offers a promising alternative to cytology for detecting premalignant lesions of the uterine cervix, with its cost-effectiveness, on-the-spot results, and high sensitivity and specificity. In low-resource settings like India, where a substantial number of women lack access to screening tests, VIA is especially well-suited. This screening method allows for immediate counseling and referral for treatment, helping to reduce delays in diagnosis and treatment which can help to minimize delays in diagnosis and treatment.

This is an Open Access (OA) journal, and articles are distributed under the terms of the [Creative Commons Attribution-NonCommercial-ShareAlike 4.0 License](https://creativecommons.org/licenses/by-nc-sa/4.0/), which allows others to remix, tweak, and build upon the work non-commercially, as long as appropriate credit is given and the new creations are licensed under the identical terms.

For reprints contact: [reprint@ipinnovative.com](mailto:reprint@ipinnovative.com)

## 1. Introduction

Cervical cancer is a notable public health issue, particularly in developing countries, where approximately 80% of cases

are reported. The cervix is susceptible to severe infections of the upper genital tract, as well as viruses and carcinogens, which can lead to the development of invasive carcinoma.<sup>1</sup> Although cervical cancer is preventable, it has a high incidence rate, with over 600,000 new cases and 340,000 fatalities recorded globally in 2020.<sup>2</sup>

\* Corresponding author.

E-mail address: [mahinfaridikhan@gmail.com](mailto:mahinfaridikhan@gmail.com) (M. F. F. Khan).

According to the GLOBOCAN 2020 report, cervical cancer constituted 9.4% of all cancer cases in India and 18.3% of new cancer cases in the country.<sup>3</sup> Unfortunately, cervical cancer is a prevalent cancer in India and a primary cause of cancer-related deaths among women in low- and middle- income nations. Based on population-based surveys, it has been found that cervical cancer screening rates are significantly lower in developing countries (19%) compared to developed countries (63%).<sup>4</sup>

A research conducted in 2020 using the National Family Health Survey data revealed that just 22% of women in India had undergone a cervical examination. At present, a range of screening methods are available for the early detection of cervical cancer and its precursor lesions. They vary in terms of their feasibility, testing characteristics, and economic considerations. Cervical cancer has a treatable and curable precursor lesion that can be detected through effective screening procedures. Therefore, the incidence and morbidity of cervical cancer can be reduced. Cervical cancer screening is a highly successful public health measure for cancer prevention that has been widely implemented. The significance of cervical screening stems from the fact that the development of invasive cervical cancer is typically preceded by an extended period of precancerous lesions that can be readily detected through routine screening and can be treated using simple methods. This renders cervical cancer a largely preventable disease with regular screening.<sup>5</sup> However, cervical cancer is now considered preventable through cervical screening and curable, particularly if detected early, which emphasizes the importance of "prevention is better than cure".<sup>6,7</sup> Due to the ease of examining the cervix through procedures such as cytological sampling, palpation, and tissue sampling, many screening programs have been implemented to detect and treat cervical cancer in its early stages. The current research utilized Pap smear, VIA, and colposcopy to identify abnormal cervical appearances indicative of carcinoma.

## 2. Material and Methods

### 2.1. Study design

This prospective observational analytical study was carried out in OPD of IIMSR, Department of Obstetrics & Gynecology, The study involved women aged 21 to 65 years and was conducted over a span of 18 months, from March 2021 to September 2022.

### 2.2. Inclusion criteria

1. Women of ages between 21 and 65 years.
2. Married women.
3. Women who exhibited abnormal symptoms such as excessive discharge, bleeding after intercourse, or bleeding between periods were included in the study.
4. No past history of cervical neoplasia.

### 2.3. Exclusion criteria

1. Pregnant women.
2. Women during post-natal period up to 3 months.
3. Previous surgery like cryosurgery, LEEP, conization, cautery, hysterectomy.
4. Previous abnormal results from previous screening.
5. Previous history of invasive cervical cancer treatment.

### 2.4. Data collection

The study was initiated only after receiving approval from the Institutional Research and Ethical Committee. Informed verbal, as well as written consent, was taken from the patient as well as the attendant. A detailed history (as per proforma) was taken for all women between 21-65 years attending OPD of our institute for a period of 18 months (March 2021 to Sep 2022). The patient's medical history was obtained, including demographic data and chief complaints, along with their duration. Additionally, her menstrual, gynecological, obstetric, and contraceptive history were discussed, as well as her past medical and surgical history. A dietary and family history were also taken.

A detailed general physical examination was performed, as well as a systemic examination. This was followed by an internal examination, which included both per speculum and per vaginal examinations.

Step 1 To perform cervical cytology, Ayre's spatula and cytobrush were used to collect a cervical smear. To prepare the sample, it was thinly spread onto a slide and then fixed with 95% ethyl alcohol. Following this, the staining procedure according to the Papanicolaou Staining Protocol was performed by the Pathology Department. The 2014 Bethesda System was used as the basis for interpreting the cytological results.<sup>8</sup>

---

#### Bethesda System

Within normal limits

Infections (org. Should be Specified.)

Reactive & Reparative Changes

Squamous Cell Abnormalities

1. ASC-US

2. ASC-H

LSIL (Low-Grade Squamous Intraepithelial Lesion)

HSIL (High-grade Squamous Intraepithelial Lesion)

Squamous Cell Carcinoma

---

Step 2 The cervix was carefully examined for the presence of Nabothian cysts, polyps, infections, or leukoplakia growths. After one minute had elapsed, a 5% acetic acid solution was administered to the cervix. The results of VIA were then classified as either positive or negative. To determine a positive result during the VIA test, the presence of a clearly visible, opaque, dense, or distinctive aceto-white area was noted. On the other hand, if

no such area was observed, or if the appearance was unclear or ambiguous, the result was considered negative.

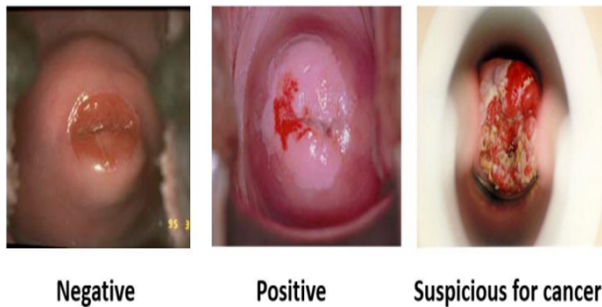


Fig. 1: Cancer type

Step 3: Women who received a positive result from the visual inspection with acetic acid (VIA) test were booked for a colposcopy examination on the same day. If any suspicious or abnormal lesion was identified during colposcopy, punch biopsies were performed based on the screening results.

These VIA-positive patients underwent a three-step colposcopy screening process, which involved the following:

- Application of normal saline
- Application of 5% acetic acid
- Application of lugol's iodine
- Colposcopy was interpreted by Swede score.<sup>9</sup> (Table 1)

The study compared and correlated the outcomes of VIA, Pap smear, and colposcopy using statistical analysis. Women who received normal results on all VIA and Pap smear both were recommended to follow up annually. However, those who tested positive on either the screening tests or colposcopy underwent biopsy and were treated based on the severity of the lesion. Treatment options included a hysterectomy, a 6-month follow-up, a repeat Pap smear, or the Loop Electrosurgical Excision Procedure (LEEP). Ethical clearance.

The research protocol adhered to the ethical standards approved by the Integral Institute of Medical Sciences & Research, Lucknow, UP.

The categorical variables were presented as frequencies and percentages (%), while the continuous variables were reported as either means  $\pm$  standard deviations (SD) or medians. Appropriate statistical tests were utilized for analysis.

1. To compare the qualitative variables, either Fisher's exact test or the chi-square test was employed.
2. The sensitivity, specificity, positive predictive value, negative predictive value, and accuracy of the conventional Pap smear, VIA, and colposcopy were determined.

3. If the p-value was less than 0.05, it was considered statistically significant.

The information was inputted into an MS Excel spreadsheet and analyzed using version 23.0 of the Statistical Package for Social Sciences (SPSS).

### 3. Results

An observational study was conducted in the outpatient department of the Department of Obstetrics & Gynecology at IIMSR, where a total of 329 women aged 21 to 65 years were enrolled over a period of 18 months.

The largest proportion of cases (20.7%) were observed among women aged between 41 to 45 years. (Table 2).

The majority 82.1% of patients were belonging to the upper lower socioeconomic class (Table 3).

White discharge was the major chief complaint (57.1%) followed by dirty discharge (15.5%), irregular menses (9.7%).

The Table 3 shows the results of VIA, Pap Smear, and colposcopy examination among the group.

Results of VIA out of which 18.5% cases were positive and 81.5% were negative.

PAP smear of VIA Positive Pap smear - most common finding was ASC (NOS/US) (37.7%), followed by NILM (23.0%), AGC and AGC NOS (13.1%), AEC (9.8%), LSIL (8.2%) and HSIL (8.2%).

PAP smear of VIA Negative Pap smear of VIA negative – 100% NILM.

Colposcopy examination - the most common was CIN I (47.5%) among the study group, followed by CIN III (16.3%), Normal (13.2%), Cervicitis (13.2%), and CIN II (9.8%).

Cervical Biopsy On biopsy, 49.1% of cases were CIN I, followed by chronic cervicitis (27.9%), CIN II (16.4%), SCC (3.3%), adenocarcinoma in situ (1.6%), and cx show no atypia (1.6%).

In the present study, the Sensitivity of VIA was 100.0%, Specificity Zero, PPV 70.49%, and Accuracy 70.49%.

The Sensitivity of Pap smear was 83.72%, Specificity 38.89%, PPV 76.6%, NPV 50%, and Accuracy 70.49%.

The Sensitivity of the colposcopy finding was 100.0% Specificity 88.89%, PPV 95.56%, NPV 100.0%, and Accuracy 96.72.

### 4. Discussion

Cervical cancer is a major cause of morbidity and mortality among women worldwide, especially in regions such as South Central Asia, Latin America, and Sub-Saharan Africa. The effectiveness of a screening test is not only determined by its accuracy; it must also take simplicity and safety into account.<sup>10</sup> Various techniques have been studied as alternatives to Pap smears for screening of cervical cancer. One of these techniques, direct visualization with

**Table 1:** The Swede score

Characteristic	Score		
	0	1	2
Uptake of acetic acid	Zero or transparent	Shady, Milky (not transparent, not Opaque)	Distinct, Opaque white
Margins and surface	Diffuse	Sharp but irregular, jagged, “Geographical”, Satellites	Sharp and even; difference in surface level, including “cuffing”
Vessels	Fine, regular	Absent	Coarse or atypical
Lesion size	<5mm	5-15 mm or spanning 2 quadrants	>15 mm or spanning 3-4 quadrants or endocervically undefined
Iodine staining	Brown	Faint or patchy yellow	Distinct Yellow

Total Score 0-4: normal/CIN 1

Total Score 5-6: CIN2/CIN3

Total Score 7-10: CIN3/cancer

**Table 2:** Distribution of the studied patients based on age

Age in Years	No. of patients (n=329)	Percentage
21-25	16	4.9%
26-30	63	19.1%
31-35	55	16.7%
36-40	52	15.8%
41-45	68	20.7%
46-50	33	10.0%
51-55	15	4.6%
56-60	16	4.9%
61-65	11	3.3%
Mean Age	39.9±9.9 Years	

**Table 3:** Distribution of the studied patients based on their characteristics

Variables	No. of Patients (n=329)	Percentage	
<b>Occupation</b>	Housewife	328	99.7%
	Teacher	1	0.3%
<b>Socioeconomic status</b>	Lower Middle Class	44	13.4%
	Upper lower Class	270	82.1%
	Upper Class	15	4.5%
<b>Chief Complaints</b>	White Discharge	189	57.4%
	Prolapse	28	8.5%
	Blood Mixed Discharge	5	1.5%
	Burning Micturition	4	1.2%
	Dirty Discharge	51	15.5%
	Irregular Menses	32	9.7%
	Post-Menopausal Bleeding	7	2.1%
	Curdy White Discharge	1	0.3%
	Heavy Menstrual bleeding	11	3.3%
	Pain Abdomen	1	0.3%

**Table 4:** Result of VIA, Pap smear, and colposcopy examination among the study group

Examination		No. of Patients (n=329)	Percentage (%)
VIA	Negative	268	81.5%
	Positive	61	18.5%
PAP Smear of VIA Positive (n=61)	NILM	14	23.0%
	LSIL	5	8.2%
	HSIL	5	8.2%
	ASC (NOS/US)	23	37.7%
	AGC and AGC NOS	8	13.1%
	AEC	6	9.8%
PAP Smear of VIA Negative (n=268)	NILM	268	100.0%
Colposcopy (n=61)	Normal	8	13.2%
	Cervicitis	8	13.2%
	CIN I	29	47.5%
	CIN II	6	9.8%
	CIN III	10	16.3%
Biopsy (n=61)	Chronic cervicitis	17	27.9%
	CIN I	30	49.1%
	CIN II	10	16.4%
	SCC	2	3.3%
	Adenocarcinoma in situ	1	1.6%
	Cx show no atypia	1	1.6%

**Table 5:** Sensitivity, specificity, PPV, NPV, and accuracy

	Sensitivity	Specificity	PPV	NPV	Accuracy
VIA	100.0	0.0	70.49	-	70.49
PAP	83.72	38.89	76.60	50.0	70.49
Colposcopy	100.0	88.89	95.56	100.0	96.72

acetic acid (VIA), has gained popularity and has been shown to be an effective alternative in developing countries. VIA is a simple screening tool that provides immediate results for cervical lesions. Pap smears have some limitations, such as inadequate smears, missing endocervical cells, and issues with slide fixation and air drying. Colposcopy is a useful method for evaluating abnormal cervical cytology. Acetic acid has the property of turning precancerous cervical lesions white due to their higher concentration of intracellular proteins, while normal tissues do not show any significant changes. This same technique is also utilized by physicians during colposcopy to locate and guide biopsy.<sup>11</sup>

In the present study, most of the cases (20.7%) were observed among women aged between 41 to 45 years. The study of Mrudula DM et al,<sup>1</sup> A study by Shaheen et al.<sup>12</sup> examined 500 cases of cervical cancer, with 61% (305 cases) occurring in women aged 21 to 40 years and 32% (160 cases) occurring in women aged 41 to 60 years. The mean age of participants was 40.84 years. The study also reported that the age distribution of cases was mainly between 31 to 40 years.

In the present study, the most common chief complaint in the studied cases was white discharge 189 (57.4%) Mrudula DM et al<sup>1</sup> who reported that the most common presenting chief complaint was white discharge seen in 190 cases (38%) which was comparable to Shaheen S et al,<sup>12</sup> where it was 48%.

Distribution according to VIA findings our study shows the results of VIA, 61 (18.5%) were VIA-positive cases, and 268 (81.5%) were VIA-negative. The findings were similar to the findings of Sinha S et al<sup>13</sup> where VIA was positive in 28 cases, 12.0% of the total study group. 88.0% of the study groups were negative 80 on VIA. Talathi M et al<sup>14</sup> out of 500 pt, 364 (72.8%) were VIA negative and 136 (27.2%) were VIA positive. Consul S et al<sup>15</sup> show VIA positive in 29 patients (13.8%), and 181 patients (86.2%) had normal VIA.

Our study revealed that 85.7% of Pap smears were normal. Of the 18.5% that were VIA positive, 77% of Pap smears were abnormal, including 23 (37.5%) cases of ASC (NOS/US), 8 (13.1%) cases of AGC and AGC NOS, 6 (9.1%) cases of AEC, 5 (8.2%) cases of LSIL, and 5 (8.2%)

cases of HSIL.

All 268 VIA-negative cases had normal Pap smears (100%). These findings were similar to those of Sinha S et al,<sup>13</sup> who reported that 17 cases were positive on Pap smear examination, with 10 cases of LSIL and 7 cases of HSIL, while 63 cases showed an inflammatory smear. Talathi M et al<sup>14</sup> found that among 136 women who tested positive for VIA, 42 (34%) had Pap results showing LSIL or HSIL, while all 328 women who tested negative for VIA had normal Pap smears.

61 colposcopies were done, out of 18.5% VIA positive, 73.6% colposcopies were positive, 29 were CIN I (47.5%), 10 were CIN III (16.3), 6 were CIN II (9.8%) and 8 were normal (13.2%) and 8 were cervicitis (13.2%). Our findings were in accordance with Talathi M et al,<sup>14</sup> where colposcopic findings of 128 patients were as follows 12.5% normal, 13.2% CIN III, 21% CIN II, 11.7% CIN I, and 32% cervicitis. Whereas in Agrawal A et al<sup>16</sup> out of 110 colposcopies 45.5% were normal, 18.2% were chronic cervicitis, 15.5% were CIN I, 17.3% were CIN II 3.6% were CIN III.

Distribution according to cervical biopsy findings Biopsy was done in all colposcopy patients, 49.2% were CIN I, 27% were chronic cervicitis, 10% were CIN I, 3.2% were squamous cell carcinoma and 1.6% were adenocarcinoma in situ and 1.6% were cx show no atypia, which was in accordance with Agrawal A et al<sup>16</sup> found that 33.3% had chronic cervicitis, followed by 28.3% with CIN I lesion, 13.3% with CIN 2, 6.7% with CIN 3 lesion and only 1.7% had histologically proven malignancy.

In the present study, the sensitivity of VIA was 100.0%, PPV was 70.49%, and accuracy was 70.49%. The sensitivity of the Pap smear was 83.72%, specificity 38.89%, PPV 76.6%, and NPV 50% whereas the accuracy was 70.49%. The sensitivity of colposcopy findings was 100.0%, specificity 88.89%, PPV 95.56%, and NPV 100.0% whereas the accuracy was 96.72%. According to a study conducted by Talathi M et al,<sup>14</sup> the sensitivity of VIA was found to be almost equivalent to that of the Pap smear, with VIA having a sensitivity of 100% and Pap having a sensitivity of 90.2%. The study also reported that VIA had a negative predictive value (NPV) of 100%. However, the specificity of VIA was zero in the study, since only participants who tested positive with VIA underwent cervical biopsy, and all participants who tested negative for VIA had a normal result on the Pap smear. In a study by Paswan A et al,<sup>17</sup> the sensitivity of visual inspection with acetic acid (VIA) for detecting invasive cervical cancer was found to be 85.1%, with a false negative rate of 14.9%. The study also reported that the specificity of VIA was 84.1%, with a false positive rate of 15.1%. The positive predictive value and negative predictive value for VIA in this study were 41.7% and 97.7%, respectively.

## 5. Conclusion

After breast cancer, cervical cancer is the second most prevalent type of cancer in India. The adoption of a successful screening programme is the only way to control the bulk of cases in India, which originate from rural regions. Cytology is a recognized screening tool for identifying premalignant lesions of the cervix. Nevertheless, VIA can also serve as a primary screening method that is cost-effective and provides immediate results. VIA is particularly attractive in low-resource settings such as India, where the majority of women in the low socioeconomic strata remain unscreened. Pap smear, on the other hand, has limitations, such as difficulty in reaching remote areas, infrastructure and resource constraints required for cytological screening in developing countries, and low follow-up rates. As an inexpensive screening method with greater sensitivity and specificity, VIA has the potential to effectively screen large populations. Additionally, VIA offers immediate, real-time screening results, enabling prompt counseling and referral for treatment as necessary. Using VIA in established cytology services could be a cost effective approach to distinguish a potentially abnormal cervix from a healthy one. Thus, VIA offers a promising alternative to cytology for detecting premalignant lesions of the uterine cervix, with its cost-effectiveness, on-the-spot results, and high sensitivity and specificity. VIA is especially attractive in low-resource settings like India, where many women do not have access to screening tests and can provide immediate counseling and referral for treatment, which can help reduce delays in diagnosis and treatment.

## 6. Limitation

Our study was hospital based. It is suggested to conduct the study in the general population of rural and urban India. It is suggested to further study variables like menstrual hygiene, socio-economic status, sex and health education, HPV vaccination, previous screening, awareness regarding cervical cancer, multiple sexual partners, parity, smoking, and immune status into consideration which can influence the study and disease progression.

## 7. Source of Funding

There is no funding for this research.

## 8. Conflict of Interest


The authors declare no conflict of interest.

## References

1. Dasari MM, Anem V, Gunta S, Seeram SK, Atla B. Comparative study of effectiveness of Pap smear versus visual inspection with acetic acid for mass screening of lesions of cervix. *Int J Res Med Sci.* 2018;6(6):2042–8.

2. Sung H, Ferlay J, Siegel RL, Laversanne M, Soerjomataram I, Jemal A, et al. Global Cancer Statistics 2020: GLOBOCAN Estimates of Incidence and Mortality Worldwide for 36 Cancers in 185 Countries. *CA Cancer J Clin.* 2021;71(3):209–49.
3. Globocan. International Agency for Research on Cancer; 2020. Accessed 29 April 2021. Available from: <https://gco.iarc.fr/>.
4. Sreedevi A, Javed R, Dinesh A. Epidemiology of cervical cancer with special focus on India. *Int J Womens Health.* 2015;7:405–14.
5. Bhatia N, Mukhopadhyay A, Kriplani A, Pandey RM, Gravitt PE, Shah KV, et al. Evaluation of adjunctive tests for cervical cancer screening in low resource settings. *Indian J Cancer.* 2007;44(2):51–5.
6. Peto J, Gilham C, Fletcher O, Matthews FE. The cervical cancer epidemic that screening has prevented in the UK. *Lancet.* 2004;364(9430):249–56.
7. Cohn DE, Herzog TJ. New Innovations in cervical cancer screening. *Clin Obstet Gynecol.* 2001;44(3):538–49.
8. Nayar R, Wilbur DC. The Pap test and Bethesda 2014. *Cancer Cytopathol.* 2015;123(5):271–81.
9. Alan M, Gunyeli I, Gultekin M, Sancı M, Yuce K. Correlation of Swede score colposcopy scoring system and histopathological results in patients with high-risk HPV infection other than HPV16 and 18. *Int J Gynecol Cancer.* 2020;30(1):35–40.
10. Arbyn M, Sankaranarayanan R, Muwonge R, Keita N, Dolo A, Mbalawa CG, et al. Pooled analysis of the accuracy of five cervical cancer screening tests assessed in eleven studies in Africa and India. *Int J Cancer.* 2008;123(1):153–60.
11. Singh KN, More S. Visual inspection of cervix with acetic acid (VIA) in early diagnosis of cervical intraepithelial neoplasia (CIN) and early cancer cervix. *J Obstet Gynaecol India.* 2010;60(1):55–60.
12. Shaheen S, Sharma R, Rashi R. Visual Inspection with Acetic Acid (VIA) in cervical cancer screening in low resource settings. *Bangladesh J Med Sci.* 2014;13(4):454–9.
13. Sinha S, Singh V, Mishra B, Singh A. Comparing the efficacy of visual inspection of cervix with acetic acid and Lugol's iodine with Pap smear cytology in screening for scancer cervix. *J Curr Res Sci Med.* 2018;4:10–6.
14. Talathi M, Wagh G. Comparison and correlation of visual inspection with acetic acid, papanicolaou smear and colposcopy in detection of precancerous cervical lesions. *Int J Reprod Contracept Obstet Gynecol.* 2016;5(10):3384–9.
15. Consul S, Agrawal A, Sharma H, Bansal A, Gutch M, Jain N. Comparative study of effectiveness of Pap smear versus visual inspection with acetic acid and visual inspection with Lugol's iodine for mass screening of premalignant and malignant lesion of cervix. *Indian journal of medical and paediatric oncology. Indian J Med Paediatr Oncol.* 2012;33(3):161–5.
16. Agrawal A, Sharma A, Gupta M, Agarwal N. Role of cytology, colposcopy and colposcopic directed biopsy in the evaluation of unhealthy cervix. *Int J Reprod Contracept Obstet Gynecol.* 2016;5(11):3765–9.
17. Paswan A, Kumar A, Jha K, Sinha SK. VIA (Visual inspection with acetic acid) and VILI (Visual inspection with lugol's iodine) as an initial approach with colposcopy as a next screening tool with its positive predictive value in low socioeconomic patients. *Int J Reprod Contracept Obstet Gynecol.* 2018;7(1):210–4.

### Author biography

**Mahin Fatima Faridi Khan,** PG 3rd Year Student  
 <https://orcid.org/0009-0000-8650-9438>

**Bhavana Gupta,** Professor and HOD

**Meenakshi Srivastava,** Professor

**Kusum Lata,** Associate Professor

**Vibha Singh,** Senior Resident

**Twinkle,** PG Student JR-3

**Cite this article:** Khan MFF, Gupta B, Srivastava M, Lata K, Singh V, Twinkle. To compare the effectiveness of Pap smear, VIA and colposcopy for screening of premalignant lesions of cervix. *Indian J Obstet Gynecol Res* 2023;10(3):247-253.