

Content available at: <https://www.ipinnovative.com/open-access-journals>

Indian Journal of Obstetrics and Gynecology Research

Journal homepage: www.ijogr.org

Case Report

Cervical lacerations: A case series

Sarah Quraishi¹, Gifty D¹, Arathy Raj², Swati Rathore¹, Beena K^{1*}

¹Dept. of Obstetrics & Gynecology, Christian Medical College, Vellore, Tamil Nadu, India

²S.L. Christian Medical College, Vellore, Tamil Nadu, India



ARTICLE INFO

Article history:

Received 16-05-2023

Accepted 27-03-2023

Available online 22-11-2023

Keywords:

Cervical laceration

Postpartum haemorrhage

Bucket handle cervical tear

ABSTRACT

Cervical laceration (CL) after vaginal delivery is one of the uncommon side effects with significant morbidity if undetected and unattended to promptly. This is however one of the common causes for postpartum haemorrhage. There are several documented risk factors for CL such as previous interventions on the cervix, induction of labour, use of Prostaglandins for induction, precipitate labour, operative vaginal deliveries and birth weight of more than 3500gm.

In this article we have described a series of eleven women who were detected to have CL following vaginal delivery. One of whom had delivery of the baby through a bucket handle cervical tear with a non-dilated cervical os. Almost all of them needed multiple blood and product transfusions in view of postpartum haemorrhage with one of them developing acute kidney injury subsequently.

This necessitates the need for prompt identification of CL and its needed intervention.

This is an Open Access (OA) journal, and articles are distributed under the terms of the [Creative Commons Attribution-NonCommercial-ShareAlike 4.0 License](https://creativecommons.org/licenses/by-nc-sa/4.0/), which allows others to remix, tweak, and build upon the work non-commercially, as long as appropriate credit is given and the new creations are licensed under the identical terms.

For reprints contact: reprint@ipinnovative.com

1. Introduction

Cervical laceration (CL) after vaginal delivery is one of the uncommon side effects with significant morbidity if undetected and unattended to promptly. The incidence of CL after vaginal deliveries ranges from 0.2% to 1.2%.^{1,2} This is one of the common causes for postpartum haemorrhage (PPH). CL can range from superficial to deep with extensions to the vagina or the lower segment of the uterus. Occasionally, there can be complete avulsion of the cervix from the uterus leading to a bucket handle tear.

2. Materials and Methods

From January, 2018 to April, 2022 there were 38549 vaginal deliveries in our tertiary care centre. Of them eleven women were identified to have CL needing surgical intervention. In this article we are describing a summary of these

eleven women who have had CL detected following vaginal delivery with detailed presentation of one of them who had a bucket handle tear of the posterior lip of cervix.

3. Case Presentation

Mrs. S a 26-year-old Primigravida, conceived with IVF after evaluation for 4 years of infertility. At 36 weeks and 5 days of gestation with risk factors of being gestational diabetes on medication and hypothyroidism. She had presented with prelabour rupture of membranes. Induction of labour was done using 2 doses of vaginal insertion of 25ug Misoprostol. The cervix was quite unfavourable at induction with a Bishop score of 2/13. Six hours from the second dose of misoprostol augmentation of labour was done when the Bishop score was 3/13. Labour progressed rapidly and within 6 hours of augmentation of labour she delivered vaginally a 2.8kg baby. Following delivery, she had PPH and exploration of the cervix revealed a five cm long CL along

* Corresponding author.

E-mail address: beenakingsbury@yahoo.com (Beena K).

the posterior lip of cervix with the external cervical os being only one cm dilated. (Figure 1) The tear was sutured under anaesthesia. (Figure 2) She had a significant blood loss of about a litre needing blood transfusion.

The following tabular columns are a summary of eleven such patients who have had cervical tears following vaginal delivery. (Tables 1, 2 and 3)

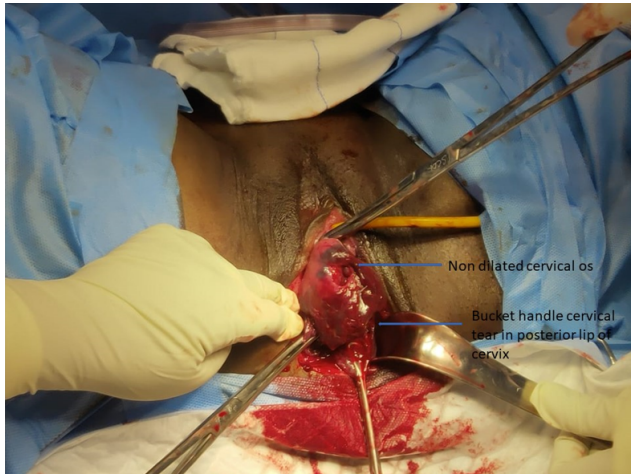


Figure 1: Posterior cervical tear with non dilated cervical os

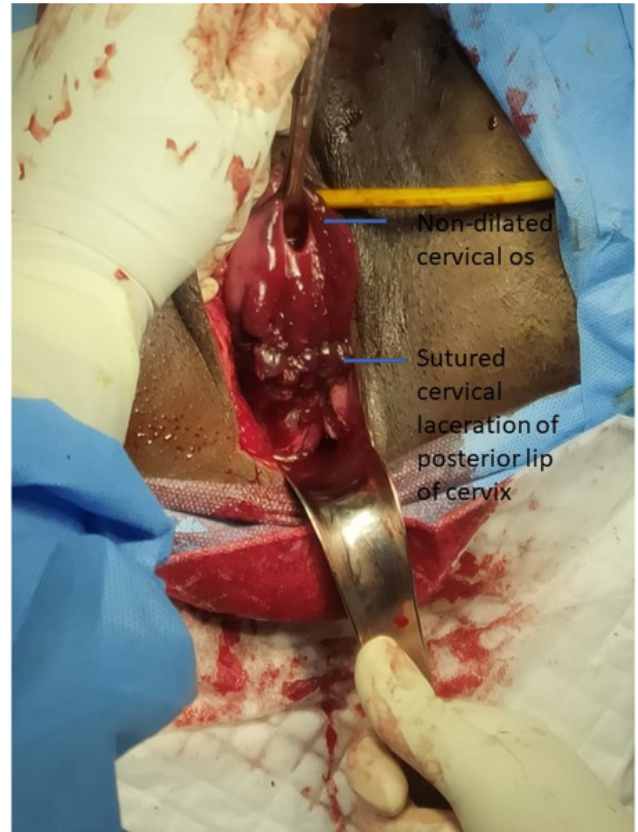


Figure 2: Sutured posterior cervical tear

Table 1: Patient characteristics

Characteristics	Value
Age	20-30 (Mean 24.8 years)
Parity	
Primigravida	6 (55%)
Multigravida	5 (45%)
Gestation age	
Term (≥ 37 weeks gestation)	10 (91%)
Preterm (≤ 36 + 6 weeks gestation)	1 (9%)

Table 2: Labour characteristics

Characteristics	Value
Labour—*	
Spontaneous	5 (45%)
Induced	4 (36%)
Augmentation of labour*	9 (82%)
Mode of delivery	
Vaginal delivery	7 (64%)
Low forceps delivery	3(27%)
Vacuum delivery	1(9%)
Weight of the baby	
<3500gm	8 (73%)
≥3500gm	2 (18%)

* information unavailable for 2 patients delivered elsewhere

Table 3: Details regarding cervical tear

Location of tear	
Anterior lip	4 (36%)
Posterior lip	7 (64%)
Length of tear *	
≤ 5 cm	4 (44%)
>5 cm	5 (56%)
Total blood loss *	
< 1000ml	2 (22%)
≥1000ml	7 (78%)
Associated DIC ‡	2 (20%) †
Need for ICU §care	3 (30%)
Duration of hospital stay	
< 5 days	5 (45%)
≥5 days	6 (55%)

* information not available for 2 patients delivered elsewhere and referred to our hospital for further care

†One patient developed acute kidney injury

‡DIC - disseminated intravascular coagulopathy

§ICU – intensive care unit

4. Discussion

Cervical laceration although not very common, is known to cause PPH. Incidence of CL among primigravida was 1% while among multigravida was 0.5% according to study by Landy in 2011.³ The known precipitating factors for CL in literature being previous interventions on the cervix 6-14% (polypectomy, LEEP, cerclage), induction of labour (threefold increased risk), use of Prostaglandins for induction of labour, precipitate labour, operative vaginal deliveries and birth weight > 3500gms.¹⁻⁵

However, in our experience of the known risk factors, the most common association were with induction of labour and operative vaginal delivery. In recent years the rate of induction of labour have exponentially increased.⁶ In literature induction of labour has been associated with increased risk of PPH, precipitated labour, need for operative delivery and uterine rupture.⁷ Instrumental delivery – both vacuum and forceps have been associated with increased maternal soft tissue injury including CL.⁸ Similarly precipitate labour, where the cervix rapidly dilates to accommodate the presenting part has also been enlisted as one of the reasons for CL.⁹ Hence, CL has to be anticipated and actively looked for in patients who undergo precipitate labour or have a rapid progression of labour or patients undergoing operative vaginal delivery and have associated increased bleeding.

Although the occurrence of cervical tear is rare, due to its associated increase in morbidity in terms of increased blood loss and the burden of increased need for blood and product transfusion, the occasional need for ICU care this complication following delivery has to be kept in mind and actively sought for especially in patients who have PPH.

5. Conclusion

Meticulous inspection of the cervix is needed in women who have increased vaginal bleeding after precipitate labour, induction of labour or operative vaginal delivery.

1. Cervical lacerations although rare can lead to traumatic postpartum haemorrhage.
2. Prompt identification and intervention is needed.
3. Be aware of its risk factors such as precipitate labour, previous cervical procedures, induction of labour with prostaglandins and birth weight > 3500gm.

6. Source of Funding

None.

7. Conflicts of Interest

The authors declare that they have no competing interests.

Acknowledgements

We would like to thank the labour room team who tirelessly worked in managing the patients. The medical records section team who helped in getting the charts for collecting data.

References

1. Parikh R, Brotzman S, Anasti JN. Cervical lacerations: some surprising facts. *Am J Obstet Gynecol.* 2007;196(5):17–8.
2. Kohli B, Nagpal M. Cervical Tear: A rare route of delivery: Case report. *Int J Clin Obstet Gynaecol.* 2020;4(1):251–2.
3. Landy HJ, Laughon SK, Bailit J, Kominiarek MA, Gonzalez-Quintero VH, Ramirez M, et al. Characteristics Associated With Severe Perineal and Cervical Lacerations During Vaginal Delivery. *Obstet Gynecol.* 2011;117(3):627–35.
4. Djokovic D, Costa C, Martins A, Abushad S. Spontaneous delivery through a cervical tear without cervical os dilatation. *Clin Case Rep.* 2015;3(1):3–6.
5. Dasari P, Sagili H, Udupi G. Unusual complication of vaginal delivery: is misoprostal the cause? *BMJ Case Rep.* 2012;2012:bcr2012007005. doi:10.1136/bcr-2012-007005.
6. Marconi AM. Recent advances in the induction of labor. *F1000Res.* 2019;8. doi:10.12688/f1000research.17587.
7. Lueth GD, Kebede A, Medhanyie AA. Prevalence, outcomes and associated factors of labor induction among women delivered at public hospitals of MEKELLE town-(a hospital based cross sectional study). *BMC Pregnancy Childbirth.* 2009;20(1):203. doi:10.1186/s12884-020-02862-7.
8. Biru S, Addisu D, Kassa S, Animen S. Maternal complication related to instrumental delivery at Felege Hiwot Specialized Hospital, Northwest Ethiopia: a retrospective cross-sectional study. *BMC Res Notes.* 2019;12:482. doi:10.1186/s13104-019-4530-7.
9. Suzuki S. Clinical Significance of Precipitous Labor. *J Clin Med Res.* 2015;7(3):150–3.


Author biography

Sarah Quraishi, PG Student

Gifty D, PG Student

Arathy Raj, Assistant Professor

Swati Rathore, Professor  <https://orcid.org/0000-0003-3660-7296>

Beena K, Associate Professor  <https://orcid.org/0000-0002-6638-142X>

Cite this article: Quraishi S, Gifty D, Raj A, Rathore S, Beena K. Cervical lacerations: A case series. *Indian J Obstet Gynecol Res* 2023;10(4):508-510.