

Content available at: <https://www.ipinnovative.com/open-access-journals>

Indian Journal of Obstetrics and Gynecology Research

Journal homepage: www.ijogr.org

Case Report

Spontaneous adrenal hematoma in pregnancy: A case report

Rajkumar Gupta¹, Nikhil Tayal^{1*}, Gopi Ramu¹

¹Dept. of Surgical Gastroenterology and Minimal Access Surgery, SDM Hospital, Jaipur, Rajasthan, India



ARTICLE INFO

Article history:

Received 19-04-2023

Accepted 17-11-2023

Available online 17-02-2024

Keywords:

Adrenal hematoma

Haemorrhage

Pregnancy

Spontaneous

ABSTRACT

Abdominal pain is a very common complaint during pregnancy, which can be because of a number of causes including surgical, non-surgical and pregnancy related factors. A rare cause of abdominal pain is adrenal haemorrhage, which can be traumatic as well as spontaneous. The exact incidence of spontaneous adrenal haemorrhage in pregnancy is not known, however various autopsy series have shown it to be 0.3-1.8% in general population. We present a case report of 27 year female with pain abdomen. On further evaluation, she was found to have left adrenal lesion for which she underwent left sided adrenalectomy. Common causes of adrenal haemorrhage include trauma, stress like surgery, sepsis, burns, pregnancy, anticoagulation or coagulopathy. Spontaneous adrenal haemorrhage is a rare diagnosis in pregnancy and a high degree of suspicion is needed for diagnosis. A preoperative diagnosis of adrenal hematoma is difficult to make and is usually made postoperatively.

This is an Open Access (OA) journal, and articles are distributed under the terms of the [Creative Commons Attribution-NonCommercial-ShareAlike 4.0 License](https://creativecommons.org/licenses/by-nc-sa/4.0/), which allows others to remix, tweak, and build upon the work non-commercially, as long as appropriate credit is given and the new creations are licensed under the identical terms.

For reprints contact: reprint@ipinnovative.com

1. Introduction

Abdominal pain is a very common complaint during pregnancy, which can be because of a number of causes including surgical, non-surgical and pregnancy related factors. A rare cause of abdominal pain is adrenal haemorrhage, which can be traumatic as well as spontaneous. The exact incidence of spontaneous adrenal haemorrhage in pregnancy is not known, however various autopsy series have shown it to be 0.3-1.8% in general population.¹

In pregnancy, adrenal gland undergoes both hyperplasia and hypertrophy in view of increased demand of various hormones in body. This change results in increased blood supply of adrenal which may predispose to congestion and haemorrhage.² The presenting complaints may vary from mild abdominal pain to severe life-threatening haemorrhage. Bilateral haemorrhage can lead to acute

deficiency of adrenal hormone production leading to adrenal crisis and adrenal shock.¹ Spontaneous adrenal hematoma in pregnancy is a very rare condition. Diagnosis is usually made on imaging of abdomen with contrast enhanced CT. Confirmatory diagnosis is made on histopathological examination. A preoperative clinical diagnosis is unusual due to nonspecific presentation.³ Diagnosis in pregnancy is challenging but MRI abdomen may help. The treatment depends upon the condition of patient on presentation and response to conservative management.⁴ A high degree of suspicion and clinical experience is needed for diagnosis as most patients present with non-specific symptoms. If neglected, it can result in maternal mortality.⁵

2. Case Presentation

A 27-year female, primigravida at 16 weeks of gestation, IUI conceived, presented with pain lower left abdomen. No other complaints were present. General physical examination was within normal limits. Per abdomen, uterus

* Corresponding author.

E-mail address: nikhil.tayal555@gmail.com (N. Tayal).

was 12-16 weeks gestation size. Systemic examination did not reveal any significant abnormality.

Blood investigations revealed Hb -10.7 gm/dL, TLC 9,260/dL, platelets 4.84 lacs. Serum cortisol levels – 384nmol/L, Calcium 9.4mg/dL. Urinalysis was normal.

On transabdominal USG, a well-defined solid cystic mass lesion measuring 65*57 mm is seen in left supra renal region. Mass appeared separately from left kidney and spleen with single live intrauterine pregnancy of 13 weeks + 5days.

Hormone profile showed TSH 0.59, T3 1.67, T4 10.44. Serum cortisol - 9.03 mcg/dL, HbA1C - 4.13%. Urinary nor-metanephrine 65.2 mcg/L, 312.96mcg/24hrs and Nor-Metanephrine: Creatinine ratio 434.67.

MRI abdomen showed a well-defined altered signal intensity lesion in left adrenal gland showing internal T1W, T2W and STIR hyper-intensity with T1W and T2W hypointense peripheral rim and multiple thick septations and debris within. Mild peri-lesional fat stranding was present. Relations with the surrounding structures appear clear. Adjacent splenic and other vessels show normal flow related signals, which was suggestive of adrenal neoplasm with haemorrhage.

Patient was planned for surgery after consulting endocrinologist and obstetrician. Intraoperatively, after left colon was mobilized, left adrenal artery and vein were identified, clipped separately and cut. Left adrenal gland dissected and excised. A drain was placed in the adrenal fossa. Oral liquids started on 1st postoperative day and increased gradually as she tolerated. The foetal well-being after surgery was confirmed by post-operative USG. She had an uneventful postoperative recovery and discharged after removing the drain on 4th postoperative day.

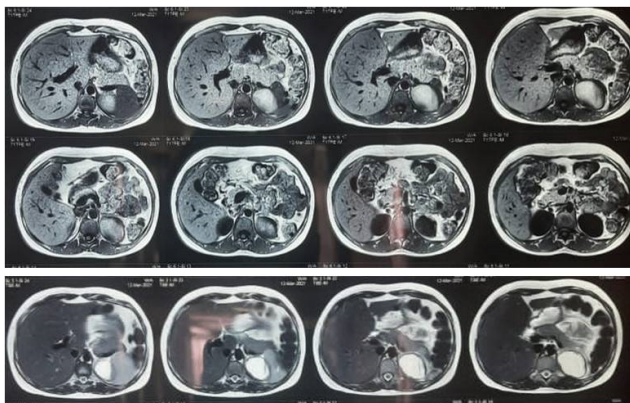


Figure 1:

3. Discussion

Common causes of adrenal haemorrhage include trauma, stress like surgery, sepsis, burns, pregnancy, anticoagulation or coagulopathy. Adrenal tumours like

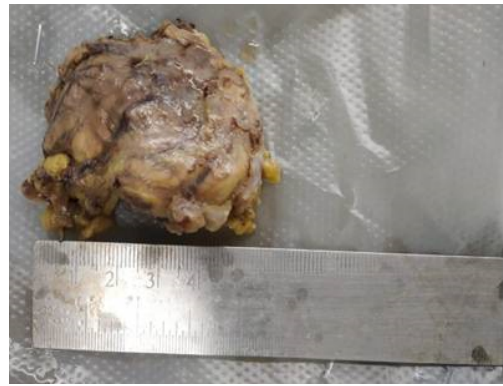


Figure 2:

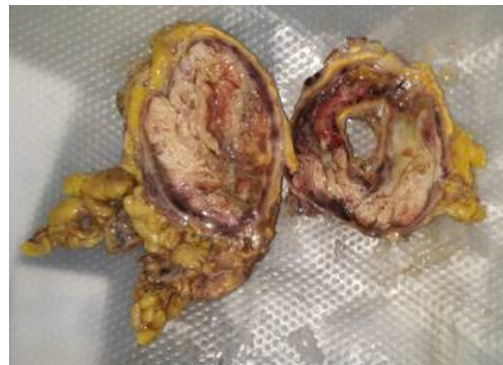


Figure 3:

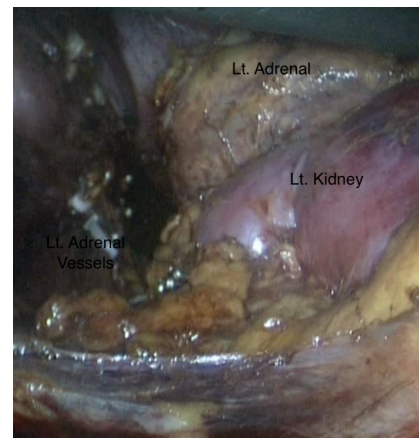


Figure 4:

adenoma and pheochromocytoma also predispose to adrenal haemorrhage.⁶ Adrenal hematoma is a rare entity in general population and even more in pregnancy. Pregnancy, being a hyperdynamic circulatory condition, itself is a risk factor for spontaneous adrenal haemorrhage. The underlying etiopathogenesis is increased blood supply to meet the demand of hyperplasia and hypertrophy of adrenal gland. The resulting increased blood vasculature may lead

to congestion, central venous thrombosis and vascular rupture. Pregnancy is a hyperdynamic and hypercoagulable state, which itself is a high risk factor for spontaneous adrenal haemorrhage.⁴

The clinical features of adrenal hematoma may vary from mild abdominal pain to severe life-threatening haemorrhage. The common symptoms are flank pain, nausea, vomiting, palpable flank mass and peritonism. Fever and fatigue can also be present. However, no sign or symptom is pathognomonic of the disease.⁷

Adrenal hematoma is characterized by presence of pseudo-capsule formation and repeated haemorrhage. As compared to the focal haemorrhage signal in tumour-related adrenal haemorrhage, adrenal simple hematoma has haemorrhage signal in different stages and lack of signal of tumour tissue. T1-weighted images show high-signal-intensity rim, which is the most important characteristic feature. This lasts from acute to subacute stage and is certified by signal intensity change from hypo-intensity to hyper-intensity on T2-weighted images as a result of intracellular deoxy-hemoglobin changed to be iron-free haemoglobin fragment. The mass is filled with inhomogeneous low signal on T2-weighted images, which is consistent with recurrent bleeding as seen on the sample and different from the signal of tumour-related tissue and the layering tendency of cystic lesions with haemorrhage.⁴

Initial management includes resuscitation using intravenous fluids. Adrenal crisis may be present which should be managed with steroid therapy.⁷ A thorough clinical history, examination is mandatory. A spectrum of investigations including complete blood work-up is required along with hormonal profile. Abdominal imaging with USG is usually the first investigation to rule out other differentials with renal stone or acute cholecystitis. MRI can be used as a measure of definitive diagnosis. However, confirmatory diagnosis can be made histologically only.

The success of conservative management depends upon the adequate fluid resuscitation, steroid therapy for adrenal insufficiency, and correction of any underlying coagulopathy. Surgery is indicated for the patients who are not responding to conservative management and continue to deteriorate despite aggressive resuscitation. Surgery should also be done for diagnostic doubt of associated adrenal tumour. Adrenal insufficiency should be addressed to prevent circulatory collapse. In severe haemorrhage, arterial embolization may be needed as a bridging for subsequent surgery.⁸ Full recovery of adrenal function is expected following resorption of the hematoma, with discontinuation of steroid therapy.

4. Conclusion

Spontaneous adrenal hematoma is a rare condition and even more so in pregnancy. The etiopathogenesis is related

to hyperdynamic circulation and hypercoagulable state in pregnancy. The presenting complaints are non-specific. The diagnosis is usually made on abdominal imaging used to rule out suspicious differential diagnosis. Once the diagnosis is confirmed on imaging, the treatment depends on the patient's general condition. Surgical treatment is done in patients not responding to the expectant management or in patients with a suspicion of underlying adrenal tumour.

5. List of Abbreviations

SAH: Spontaneous Adrenal Haemorrhage.

6. Sources of Funding

No.


7. Conflict of Interest


No.

References

- Gupta A, Minhas R, Quant HS. Spontaneous Adrenal Hemorrhage in Pregnancy: A Case Series. *Case Rep Obstet Gynecol.* 2017;2017:3167273. doi:10.1155/2017/3167273.
- Shen JZ, Stranks SN, Ho JT. Spontaneous adrenal haemorrhage in pregnancy. *Intern Med J.* 2011;41(4):362–3.
- Anagnostopoulos A, Sharma S. Spontaneous adrenal haemorrhage in pregnancy. *BMJ Case Rep.* 2011;2011:bcr0720114496.
- Yang L, Zhu YC, Liu RB. Spontaneous adrenal hematoma in pregnancy. *Medicine (Baltimore).* 2018;97(47):e13329.
- Gavrilova-Jordan LP, Edmister WB, Farrell MA, Watson WJ. Spontaneous Adrenal Hemorrhage During Pregnancy: A Review of the Literature and a Case Report of Successful Conservative Management. *Obstet Gynecol Surv.* 2005;60(3):191–5.
- Simon DR, Palese MA. Clinical update on the management of adrenal hemorrhage. *Curr Urol Rep.* 2009;10(1):78–83.
- Keizer AL, Peters LW, deVries C, Smets YFC, deWit LT, Pampus M. Spontaneous adrenal haemorrhage in early pregnancy. *BMJ Case Rep.* 2013;2013:bcr2012008062.
- Bockorny B, Posteraro A, Bilgrami S. Bilateral spontaneous adrenal hemorrhage during pregnancy. *Obstet Gynecol.* 2012;120(2):377–81.

Author biography

Rajkumar Gupta, Honorary Consultant  <https://orcid.org/0000-0001-6167-1826>

Nikhil Tayal, DrNB Trainee  <https://orcid.org/0000-0002-2954-0524>

Gopi Ramu, DrNB Trainee  <https://orcid.org/0000-0002-6825-108X>

Cite this article: Gupta R, Tayal N, Ramu G. Spontaneous adrenal hematoma in pregnancy: A case report. *Indian J Obstet Gynecol Res* 2024;11(1):93-95.