

Content available at: <https://www.ipinnovative.com/open-access-journals>

Indian Journal of Obstetrics and Gynecology Research

Journal homepage: [www.ijogr.org](http://www.ijogr.org)

## Case Report

# Malignant melanoma arising in mature teratoma with pugnacious spread: A case report

Sumedha Gupta<sup>1\*</sup>, Shalu Solanki<sup>1</sup>, Saritha Shamsunder<sup>1</sup>, Sana Ahuja<sup>2</sup>,  
Vinayak Varma<sup>3</sup>

<sup>1</sup>Dept. of Obstetrics and Gynaecology, VMMC & Safdarjung Hospital, New Delhi, India

<sup>2</sup>Dept. of Pathology, VMMC & Safdarjung Hospital, New Delhi, India

<sup>3</sup>Dept. of General Surgery, VMMC & Safdarjung Hospital, New Delhi, India



## ARTICLE INFO

### Article history:

Received 29-10-2023

Accepted 13-12-2023

Available online 17-02-2024

### Keywords:

Malignant melanoma

Mature teratoma

Dermoid

Prognosis

Treatments

## ABSTRACT

Of all ovarian neoplasms, mature cystic teratomas make up between 10–20%. Malignant transformation accounts for just 0.1-2 percent of cases of adult teratoma. Malignant melanoma is one of the rarest metamorphoses. Here, we describe a postmenopausal woman who complained of abdominal pain. Upon examination, it was discovered that she had an abdominally metastasized mature dermoid cyst that had ruptured. Following an exploratory laparotomy and staging procedures, she had a total abdominal hysterectomy and bilateral salpingo-oophorectomy with removal of melanotic deposits from the pouch of Douglas, bladder peritoneum, mesentery, and omentum, as well as the small and large bowel serosa. Only roughly 45 cases of malignant melanoma originating in mature cystic teratomas in the ovary have been documented since 1901.

This is an Open Access (OA) journal, and articles are distributed under the terms of the [Creative Commons Attribution-NonCommercial-ShareAlike 4.0 License](https://creativecommons.org/licenses/by-nc-sa/4.0/), which allows others to remix, tweak, and build upon the work non-commercially, as long as appropriate credit is given and the new creations are licensed under the identical terms.

For reprints contact: [reprint@ipinnovative.com](mailto:reprint@ipinnovative.com)

## 1. Introduction

The most prevalent kind of ovarian germ cell tumours is mature cystic teratoma (MCT), a benign tumour also known as a dermoid cyst. More than 80 percent of occurrences occur during the reproductive years, particularly in women under 40. The worst and most uncommon complication of MCT is malignant transformation that affects 1-3 percent of patients, particularly postmenopausal women. Squamous cell carcinoma (SCC) accounts for approximately 80% of the histological type of malignant changes; it is followed by adenocarcinoma, carcinoid tumour, melanoma, and sarcoma.<sup>1</sup> Due to the non-specific signs that make preoperative diagnosis challenging, the majority of patients have poor prognosis and are discovered at an advanced stage. Nonetheless, diagnosis at early stage is essential for

longer survival. In this investigation, we present another case of malignant transformation within a mature cystic teratoma.

## 2. Case Presentation

A 56-year-old lady who had been through six years of menopause presented with a palpable, expanding abdominal mass over a period of six months, but she had neither postmenopausal bleeding nor vaginal discharge. During physical examination, a smooth cystic mass in the lower abdomen that corresponds to the size of an 18-week uterus was discovered. Upon vaginal inspection, the right fornix was free, but a lump was felt in the left fornix. An ultrasound revealed a solid-cystic abdominopelvic mass with thin septations and mixed echogenicity. A massive multi-loculated solid-cystic abdominopelvic mass (8.5 x 7.8 x 10.2 cm) with areas of fat attenuation and fat fluid

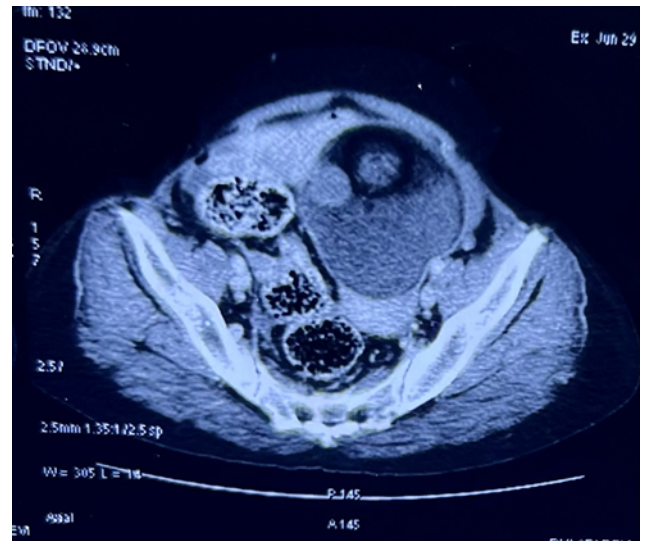
\* Corresponding author.

E-mail address: [sumedhagupta91@gmail.com](mailto:sumedhagupta91@gmail.com) (S. Gupta).

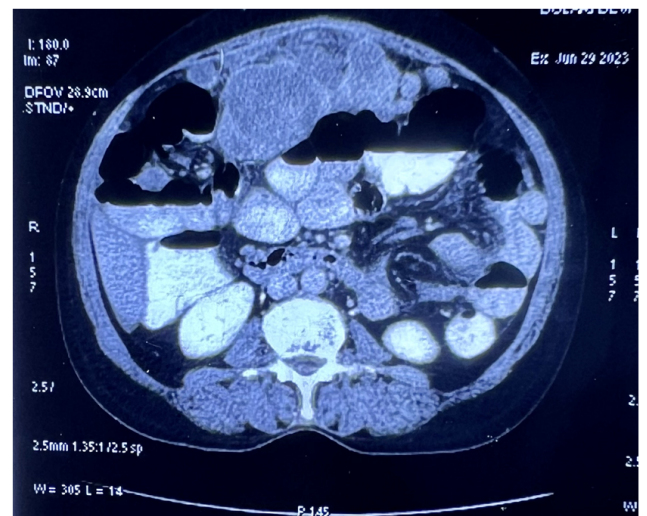
levels was discovered using computed tomography. There was also calcification that suggested the mass was either dermoid or epidermoid in the left ovary. Metastasis is most likely the cause of several enlarged soft tissue masses in the mesentery as well as peritoneal and omental thickening. (Figures 1 and 2) Right ovary was normal. Following an omental trucut biopsy, fibro-collagenous tissue and a hemosiderin deposit were seen; no evidence of malignancy was found. The results of biochemical analyses showed that the tumour markers CA19.9 (0.2 U/ml), CEA (3.2 ng/ml), LDH (218 units/litre), and CA125 (34 U/ml) were normal. A massive left ovarian cystic mass with capsular breach, as well as several melanotic deposits over the small and large bowel serosa, mesentery, omentum, pouch of douglas, and bladder peritoneal deposits, were discovered following an exploratory laparotomy and staging procedure (Figures 3, 4 and 5). The total abdominal hysterectomy with bilateral salpingo-oophorectomy and infra-colic omentectomy, along with the removal of metastatic deposits, was performed with R0 resection (Figure 6). Upon physical examination, the tumour was roughly 11x9x7 cm and was smooth-walled, originating from the left ovary. A cut section showed several cystic regions with hair shafts and pultaceous material inside, along with a few whitish calcification particles and a small, solid, blackish nodule measuring 2.0 x 1.0 cm. The right ovary and tube were both healthy. There was found to be a left ovarian capsular breach. A tumour with a malignant transition to malignant melanoma was identified by final histopathology (Figures 7 and 8). Metastatic melanoma deposits were seen over the bladder peritoneum, mesentery, omentum, pouch of douglas, and the serosa of the small and large bowels. Immuno-histochemical markers like SOX-10, S-100, HMB-45 (Figure 9), Melan A, and a 70–80% Ki67 index were positive in tumor cells. The final diagnosis of stage IIIC ovarian carcinoma was made. It is necessary to rule out the chance of a melanoma developing in another location—such as the skin, central nervous system, eyes, or gastrointestinal tract—with subsequent involvement of the ovarian tract. The post-operative patient had radiologic imaging, including a PET-CT scan, for additional evaluation, and the results revealed no signs of metastases. Additionally, she had a colonoscopy, which came out normal, ruling out a gastrointestinal system metastasis. Following an Multidisciplinary team evaluation, adjuvant chemotherapy and immunotherapy were recommended for the patient. A Dacarbazine injection was started for the patient.

### 3. Discussion

All three of the germ cell layers biological components, which make up ovarian teratomas, have the potential to develop into malignant tumours, although this occurs in just 0.17–2% of instances.<sup>1</sup> There is documentation of a broad



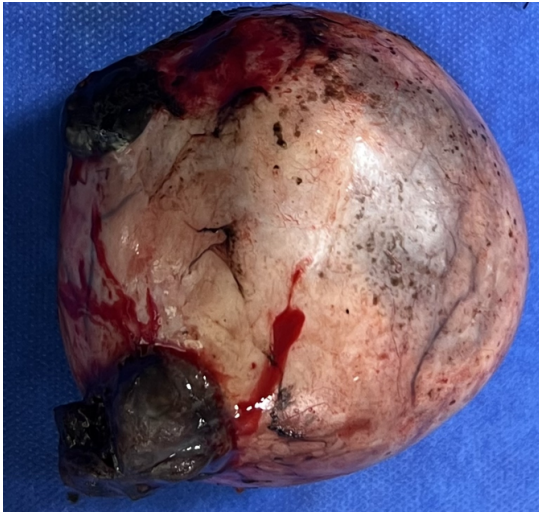**Figure 1:** Ill defined large heterogenous lesion seen in left adnexa shows post contrast enhancement, fat and calcifications- represent neoplastic etiology – likely dermoid/epidermoid of left ovary



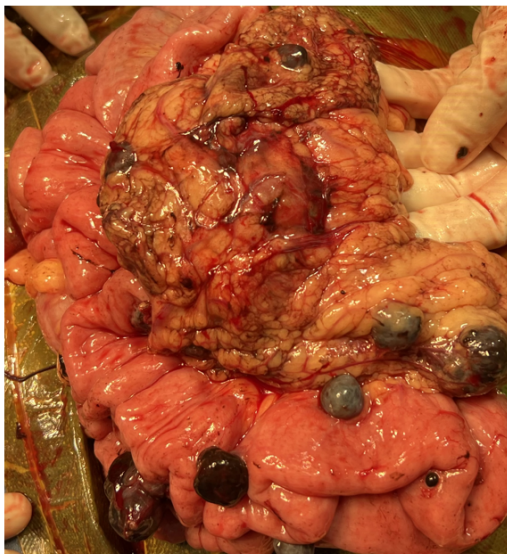**Figure 2:** Multiple enlarged enhancing soft tissue mass in omentum and mesentery likely metastatic deposit

range of malignant tumours, with squamous cell carcinoma accounting for the majority (88.3%) and being followed by adenocarcinoma, fibrosarcoma, carcinoid tumours, and mixed tumours.<sup>2</sup> With an estimated prevalence of 0.2-0.8%, malignant melanoma originating in an ovarian teratoma is an uncommon occurrence.<sup>3</sup> The majority of ovarian melanomas are metastases from other known melanomas,<sup>4</sup> of which there have been 77 cases documented so far,<sup>5</sup> with up to 18% of autopsies showing asymptomatic ovarian metastases.<sup>6</sup> The majority of cases identified as primary ovarian melanoma are actually metastases from a primary melanoma that is unknown.<sup>5,7</sup> There have been

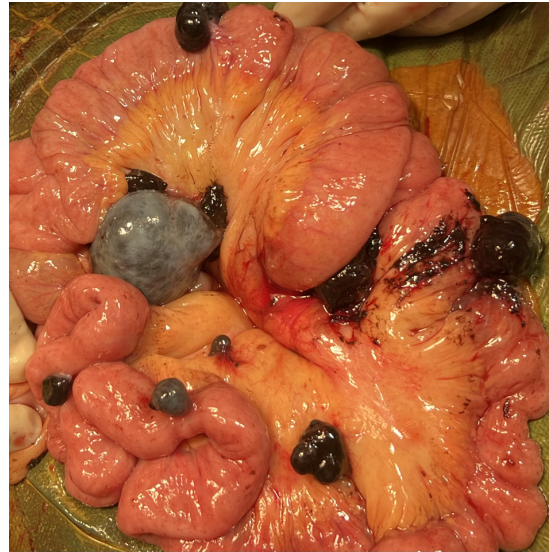



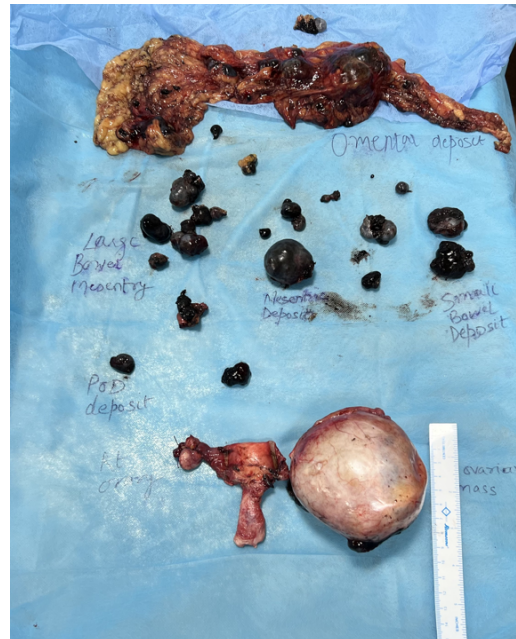**Figure 3:** Left ovarian mass with capsular rupture



**Figure 4:** Omental caking with multiple melanotic deposits



**Figure 5:** Multiple melanotic deposit over small bowel surface and mesentery



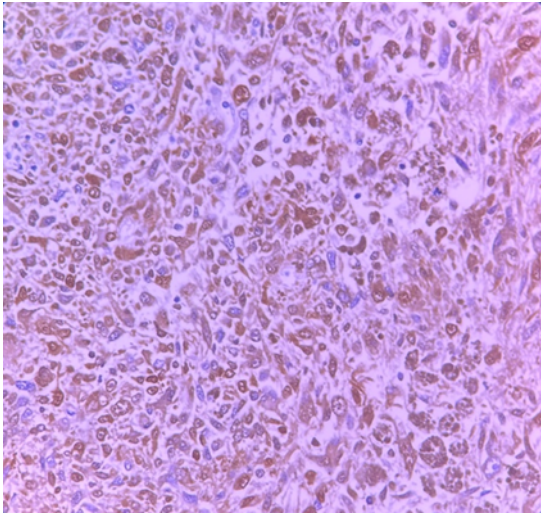
**Figure 6:** Final specimen sent for histopathological evaluation

45 documented examples of mature cystic teratoma-derived primary melanoma.<sup>8</sup> The diagnosis of a primary ovarian melanoma arising from ovarian parenchyma (in the absence of a dermoid cyst) may be very uncommon, as no such cases have been clearly documented yet, according to a review of the literature. Andrews published the first case of primary malignant melanoma inside an ovarian dermoid cyst in 1901.<sup>9</sup>

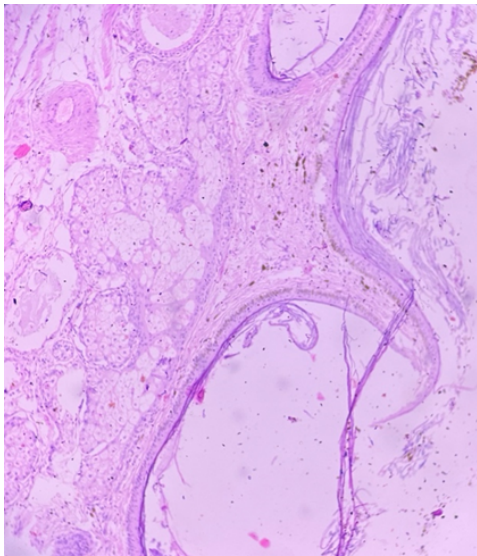
Our case did not exhibit dermo-epidermal junctional activity, which is consistent with a review by Ueda et al.,<sup>10</sup> which reported finding it in only 50% of the cases. This could be explained by the possibility that any melanocyte-containing ovarian dermoid component could be the source of a melanoma. The diagnosis of malignant melanoma arising in a teratoma was supported

by the presence of a blackish solid nodular area within the dermoid on gross examination and microscopic features characteristic of melanoma (pleomorphic vesicular nuclei, prominent eosinophilic nucleoli, and intranuclear inclusions) in our patient. The diagnosis was validated by immunohistochemistry, which revealed that the cancer cells had high levels of HMB-45, a particular marker for melanoma. Also, 80% of the melanoma cancer cells had positive values for S-100, SOX 10, Melan-A, and Ki67. Additionally, these immunohistochemistry markers

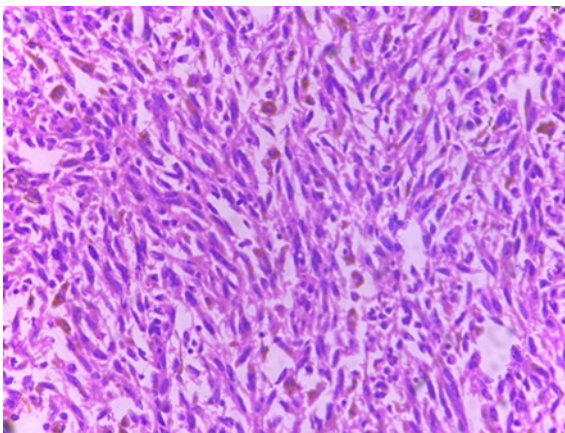




**Figure 9:** Immunohistochemical marker HMB-45 staining of melanocytic cells



**Figure 7:** Haematoxylin and eosin stained section showing stratified squamous epithelium lining of mature cystic teratoma



**Figure 8:** Invasive Melanoma (H & E, 10 x)

were positive in our case. Since our case satisfies the majority of the criteria put forth by Boughton et al.,<sup>11</sup> including being unilateral, associated with an ovarian teratoma, lacking any evidence of extraovarian melanoma, and showing a strong correlation between the clinical and pathologic context and intraepithelial junctional activity, it was classified as primary ovarian melanoma. A cautious prognosis is typically associated with ovarian cystic teratomas that undergo malignant transformation. Ascites, adhesions, cyst rupture, full-thickness cyst wall invasion, and extensive dissemination are all linked to a poor prognosis. These tumours typically spread by direct extension as opposed to lymphatic or hematologic pathways. Additionally, there were direct metastases to the omental, mesentery, intestinal serosa, and peritoneal surfaces in our instance. Histopathologic analysis supported the clinical, radiologic, and surgical diagnosis of a dermoid cyst with an incidental melanoma component. The diagnosis of primary ovarian melanoma was established in our instance by the cytological characteristics, melanin pigment, and immunohistochemistry positive for HMB45, in addition to a negative survey for melanoma elsewhere. Chemotherapy is the recommended course of treatment for ovarian malignant melanoma after a hysterectomy, pelvic clearing, and salpingo-oophorectomy. Chemotherapy with medications including cisplatin, dacarbazine, and temozolomide has prolonged survival in certain cases with primary ovarian melanomas, despite the fact that these tumours have a very bad prognosis, similar to melanomas developing at other odd places.<sup>12</sup> Additionally, recent research has emphasised the significance of immunotherapies, and malignant melanomas can be treated using targeted therapy. Patients with ovarian melanoma at a similar stage have a worse prognosis than those with ovarian carcinoma.

#### 4. Conclusion

It is extremely uncommon for malignant melanoma to develop from an ovarian mature cystic teratoma. Before contemplating the diagnosis of a primary ovarian melanoma, it is crucial to determine its genesis in a teratoma and rule out a primary melanoma elsewhere.

#### 5. Source of Funding

None.

#### 6. Conflict of Interest

None.



## References

- Mandal S, Badhe BA. Malignant Transformation in a Mature Teratoma with Metastatic Deposits in the Omentum: A Case Report. *Case Rep Pathol.* 2012;2012:568062. doi:10.1155/2012/568062.
- Hye S, Seong. Primary malignant melanoma arising in a cystic teratoma. *Obstet Gynecol Sci.* 2013;56(3):201–4.
- Godoy HE, Kesterson J, Kasznica JM, Lele S. Malignant melanoma arising in mature cystic teratoma of the ovary. *Gynecol Oncol Case Rep.* 2011;2(1):14–5.
- Sbitti Y, Fadoukhair Z, Kadiri H, Oukabli M, Essaidi I, Kharmoum S, et al. Diagnostic challenge for ovarian malignant melanoma in premenopausal women: Primary or metastatic? *World J Surg Oncol.* 2011;9:65. doi:10.1186/1477-7819-9-65.
- Gupta D, Deavers MT, Silva EG, Malpica A. Malignant melanoma involving the ovary: a clinicopathologic and immunohistochemical study of 23 Cases. *Am J Surg Pathol.* 2004;28(6):771–80.
- Liberati F, Maccio T, Ascani S, Farabi R, Lancia D, Peciarolo A, et al. Primary malignant melanoma arising in an ovarian cystic teratoma. *Acta Oncol.* 1998;37(4):381–83.
- Moehrl M, Fischbach H, Nuessle B, Rassner G. Primary malignant melanoma arising in a cystic necrotic ovarian teratoma. *Eur J Obstet Gynecol Reprod Biol.* 2001;99(2):268–71.
- Lee S, Kim HJ, Chon RG, Kim A, Kim HB. Primary malignant melanoma arising in an ovarian mature cystic teratoma -a case report and literature review. *Korean J Pathol.* 2011;45:659–64.
- Andrews HR. Primary melanoticsarcoma of the ovary. *Trans Obstet Soc.* 1901;43:228–31.
- Ueda Y, Kimura A, Kawahara H, Kitagawa H, Nakanishi I. Malignant melanoma arising in a dermoid cyst of the ovary. *Cancer.* 1991;67(12):3141–5.
- Boughton RS, Hughmanick S, Marin-Padilla M. Malignant melanoma arising in an ovarian cystic teratoma in pregnancy. *J Am Acad Dermatol.* 1987;17(5 Pt 2):871–5.
- Puzanov I, Flaherty KT. Targeted molecular therapy in melanoma. *Semin Cutan Med Surg.* 2010;29(3):196–201.

## Author biography

**Sumedha Gupta**, Senior Resident

**Shalu Solanki**, Senior Resident

**Saritha Shamsunder**, Professor

**Sana Ahuja**, Assistant Professor

**Vinayak Varma**, Senior Resident

**Cite this article:** Gupta S, Solanki S, Shamsunder S, Ahuja S, Varma V. Malignant melanoma arising in mature teratoma with pugnacious spread: A case report. *Indian J Obstet Gynecol Res* 2024;11(1):119-123.