

Content available at: <https://www.ipinnovative.com/open-access-journals>

Indian Journal of Obstetrics and Gynecology Research

Journal homepage: www.ijogr.org

Case Series

Descemet's membrane tears following forceps delivery

Aditi Pradeep Parab¹, Josephine S Christy^{1*}, Vaibhav Khanna²

¹Aravind Eye Hospital, Pondicherry, India

²Khanna Medicare Centre, New Delhi, India



ARTICLE INFO

Article history:

Received 02-11-2023

Accepted 16-12-2023

Available online 17-02-2024

Keywords:

Vaginal delivery

Descemet's membrane

Amblyopia

ABSTRACT

Purpose: To report a case series on corneal trauma induced by forceps assisted vaginal delivery.

Materials and Methods: Case records of six patients who had clinical features suggestive of corneal trauma induced by forceps delivery were retrospectively reviewed and analysed.

Results: Vertical to oblique corneal Descemet's membrane (DM) tears were noted in all 6 patients which included 2 males and 4 females. Right eye was involved in all patients and one patient had bilateral involvement. The age of presentation ranged from 5 to 39 years. Three patients had visual acuity better than 6/18 and three had worse than 6/18 in their affected eyes. All patients had corneal astigmatism in the range of 1.75 to 8 diopters.

Conclusions: A complicated vaginal delivery should be anticipated at the earliest by the obstetrician and an apt decision on the mode of delivery has to be attempted in order to prevent avoidable ocular trauma, especially in forceps assisted vaginal deliveries. All neonates who are born by forceps assisted vaginal delivery require mandatory referral to an ophthalmologist to rule out any ocular trauma. Early intervention can prevent irreversible vision loss due to amblyopia.

This is an Open Access (OA) journal, and articles are distributed under the terms of the [Creative Commons Attribution-NonCommercial-ShareAlike 4.0 License](https://creativecommons.org/licenses/by-nc-sa/4.0/), which allows others to remix, tweak, and build upon the work non-commercially, as long as appropriate credit is given and the new creations are licensed under the identical terms.

For reprints contact: reprint@ipinnovative.com

1. Introduction

Obstetrical forceps delivery induced trauma to the eye include a wide variety of presentations which may range from trivial ocular trauma to vision threatening injuries. In India, the rate of instrumental deliveries ranges from 2.7 to 7.7%.^{1,2} A study conducted in a tertiary care teaching hospital in Puducherry showed the rate of instrumental deliveries to be around 7.7% during 2010 to 2015.³ Another study conducted at a tertiary care centre in Bangalore showed the rate of forceps assisted deliveries to be 3.9%.⁴ But rate of these injuries are decreasing in today's era due to advances in the technique of delivery and increasing rates of caesarean sections.⁵ Nevertheless, there are certain situations where the obstetrician still has

to use forceps to deliver the foetus during labour. Such situations include maternal exhaustion, foetal distress, arrest of the foetal head in the same pelvic plane and ineffective uterine contractions.⁶ Common neonatal complications due to forceps delivery include facial lacerations, facial nerve injury, ocular trauma, skull fracture, intracranial hemorrhage, subgaleal hematoma, hyperbilirubinemia and foetal death.⁷ McAnena et al., reported that the rate of ocular injuries in forceps assisted deliveries was one in 413.⁸ If untreated, these ocular complications can lead to significant vision loss. In the present case series, we have discussed about six patients with varied presentation of ocular trauma following forceps delivery, along with its subsequent effect on visual impairment.

* Corresponding author.

E-mail address: josyfred@gmail.com (J. S. Christy).

2. Case Series

This series includes six patients who were clinically diagnosed to have tear in Descemet's membrane (DM) with history suggestive of forceps assisted vaginal delivery. Diagnosis was based on clinical examination and was supported by corneal topography and anterior segment optical coherence tomography (AS-OCT). Figure 1 shows slit lamp images and Table 1 shows the clinical characteristics of all six patients with DM tear. Four out of six patients were females. The age of presentation ranged from 5 – 39 years. All patients presented with the chief complaint of defective vision in the affected eye. Three patients had presenting best corrected visual acuity (BCVA) better than 6/18 and three patients had worse than 6/18. All six patients had developed amblyopia but two being in the paediatric age group had scope for visual improvement with patching exercises and one was given refractive correction.

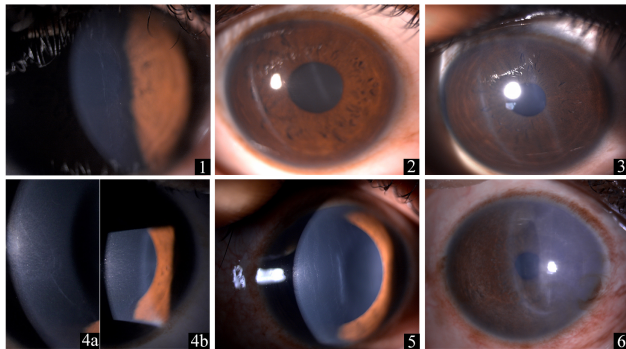


Figure 1: 1 Shows slit lamp image of vertical DM tear in case; 2 and 3 shows slit lamp image of oblique parallel DM tears in case 2 and 3 respectively; 4a and 4b shows slit lamp image of oblique and vertical DM tear in right and left eye respectively; 5 shows slit lamp image of multiple vertical DM tears in case 5 shows slit lamp image of central DM tear with nasal scarring in case 6

3. Discussion

Obstetrical forceps delivery though rare nowadays, is still in practice in places where advance technology is yet to reach. The rate of instrumental deliveries in India range from 2.7 to 7.7%^{1,2} which is lesser in comparison to the rates in United Kingdom (10-12%) and United States of America (10-15%).⁹ But this trend of instrumental vaginal deliveries is changing with the advent of new technology and there is an increasing rate of caesarean sections. The rate of caesarean section delivery in India has increased from 8.5% in 2005-2006 to 17.2% in 2015-2016 to 21.5% in 2019-2021.^{10,11} However, in rural regions with limited access to surgical facilities for caesarean sections, instrumental deliveries are still conducted, leading to the continued occurrence of ocular complications resulting from forceps deliveries. Jain et al., documented the rate of ocular injuries

to be around 17.3% in newborns delivered by forceps and 15% in newborns delivered by normal vaginal delivery.⁵

Ocular injuries secondary to forceps assisted vaginal delivery include facial nerve palsy, hyphema, descemet's membrane tear, corneal oedema, Purtscher's retinopathy, vitreous hemorrhage, injury to lids/adnexa, hematoma formation, cranial nerve palsies, etc.^{5,7} Obstetrical forceps-induced Descemet's membrane tears (FIDMT) are usually encountered during complicated forceps-assisted deliveries. Hence, these should be intentionally looked for, especially following a difficult or complicated forceps assisted delivery.

Ocular finding include a classical vertical or oblique linear tear at the level of Descemet's membrane (DM) which is clearly visualised on slit lamp examination. On rare instances, horizontal DM tears have also been documented in literature.¹² These tears are generally unilateral and usually the left eye is commonly affected as the left occipito-anterior is the commonest foetal position during vaginal delivery.¹³ However in our case series, right eye was affected in all patients with one bilateral disease which was similar to the study by McDonald et al.¹⁴ Clinical features can range from a small DM tear to a large tear with dense stromal fibrosis and induced corneal astigmatism. Honig et al, have classified the DM tears following forceps or vacuum assisted deliveries into four types. Type 1- large DM tears with one end extending into the anterior chamber and the other having scroll formation, Type 2- scrolls at each margin of the break, Type 3- small breaks in DM which heals by fibrosis and is found posterior to original tear, Type 4- small break in DM with minimal fibrosis.¹⁵ In a few cases with late presentation, these are just incidental findings noticed on routine examination, of which patients may not be aware of.¹⁶ Following a Descemet's membrane detachment (DMD), there occurs corneal oedema resulting in clouding of the cornea. In some, corneal oedema may resolve spontaneously or with a course of topical steroids leaving a clear cornea with visible edges of the break over a period of 1-3 weeks. But in some patients, it may not resolve and may lead to corneal decompensation in long run. These DM breaks lead to corneal astigmatism and dense amblyopia.¹⁷ Hence neonates with clouding of cornea especially after a forceps delivery should be definitely advised examination under anaesthesia and should be looked for any DMD. If any, air can be injected in anterior chamber and can be tried for apposition with the posterior stroma.¹⁸ Early intervention either surgically or in the form of refractive error correction, identification and treatment for amblyopia can help restore the vision.

4. Conclusion

Since obstetricians and neonatologists are always the first contacts with the newborn, they should be well aware of the consequences of forceps assisted deliveries and appropriate

Table 1: Clinical characteristics of patients presenting with DM tears

Case No.	Age/Sex	Affected eye	UCVA	BCVA	Manifest astigmatism	Topographical astigmatism	Type of tear
1	5/F	RE	6/36p	6/12p	-3.0DC @180°	5.7D	Vertical DM tear
2	13/M	RE	6/36	6/18	-0.5DS/-1.75DC @180°	-	Oblique parallel DM tears
3	13/M	RE	6/60	6/9p	-	4.3D	Oblique parallel DM tears
4	17/F	RE	6/6	6/6	1.25DS/+4.0DC@105°	1.4D	Oblique and vertical DM tear
5	26/F	RE	5/60	6/36p	-8.0DC @180°	8.3D	Multiple vertical DM tears
6	39/F	RE	4/60	4/60	+1.0DS	-	Central DM tear with nasal scarring

RE- Right eye, LE- Left eye, UCVA- Uncorrected visual acuity, BCVA- Best corrected visual acuity, DM- Descemet's membrane

measures should be taken for timely referral of the newborn to an ophthalmologist. This will help in early identification of the DM tear and its timely intervention will also ensure prevention of irreversible visual loss in the child. Since the rates of instrumental deliveries are lowering due to increase in the rate of caesarean sections, the younger obstetricians are less exposed to performing instrumental deliveries resulting in their poor clinical experience. Hence, a well performed uneventful forceps delivery is also of utmost importance in preventing ocular complications thereby preventing blindness.

5. Source of Funding

None.


6. Conflict of Interest

None.

References

1. Prameela RC, Asha MB, Prajwal S. Outcome of instrumental vaginal deliveries in referred cases. *J Evol Med Dent Sci*. 2015;4(19):3275–81.
2. Lamba A, Kaur R, Muzafar Z. An observational study to evaluate the maternal and neonatal outcome of forceps delivery in a tertiary care government hospital of a cosmopolitan city of India. *Int J Reprod Contracept Obstet Gynecol*. 2016;5(2):292.
3. Dhodapkar SB, Chauhan RC. Trends of instrumental deliveries at a tertiary care teaching hospital in Puducherry. *Indian J Appl Res*. 2015;5(7):513–5.
4. Gayatri S, Sujani BK, Urvashi, Sinha P. Outcome of Assisted Vaginal Deliveries in a Tertiary Care Centre in Bengaluru. *J Evolution Med Dent Sci*. 2021;10(40):3538–42.
5. Jain IS, Singh YP, Grupta SL, Gupta A. Ocular hazards during birth. *J Pediatr Ophthalmol Strabismus*. 1980;17(1):14–6.
6. Nikolov A, Nashar S, Atanasova M, Dimitrov A. Indications for vaginal delivery with forceps application. *Akusherstvo i Ginekologiya*. 2011;50(5):3–12.
7. Muraca GM, Sabr Y, Lisonkova S, Skoll A, Brant R, Cundiff GW, et al. Perinatal and maternal morbidity and mortality after attempted operative vaginal delivery at midpelvic station. *CMAJ*. 2017;189(22):764–72.
8. Mcanena L, O'keefe M, Kirwan C, Murphy J. Forceps delivery-related ophthalmic injuries: a case series. *J Pediatr Ophthalmol Strabismus*. 2015;52(6):355–9.
9. ACOG Practice Bulletin. Clinical Management Guidelines for Obstetrician-Gynecologists. Number 60, March 2005. Pregestational diabetes mellitus. *Obstet Gynecol*. 2005;105(3):675–85.
10. International Institute for Population Sciences (IIPS) and ICF. 2017. National Family Health Survey (NFHS-4), 2015–16. Mumbai, India: IIPS. Available from: <https://dhsprogram.com/pubs/pdf/fr339/fr339.pdf>.
11. International Institute for Population Sciences (IIPS) and Macro International. 2007. National Family Health Survey (NFHS-3), 2005–06. Mumbai, India: IIPS.
12. Thomson E, Buchanan L. The Ophthalmoscope. In: *Obstetric injuries of the cornea*; 1905. p. 267.
13. Lloyd RI. Birth injuries of the cornea and allied conditions. *Trans Am Ophthalmol Soc*. 1938;35:212–20.
14. McDonald MB, Burgess SK. Contralateral occipital depression related to obstetric forceps injury to the eye. *Am J Ophthalmol*. 1992;114(3):318–21.
15. Honig MA, Barraquer J, Perry HD, Riquelme JL, Green WR. Forceps and vacuum injuries to the cornea: histopathologic features of twelve cases and review of the literature. *Cornea*. 1996;15(5):463–72.
16. Agarwal R, Singh NK, Sinha R, Sharma N. Obstetrical forceps-induced Descemet membrane tears. *Indian J Ophthalmol*. 2021;69(12):3432–41.
17. Reddy SC. Ocular Birth Injuries following Forceps Assisted Delivery in a Newborn. *Am J Med Med Sci*. 2019;9(2):50–3.
18. Kancherla S, Shue A, Pathan MF, Sylvester CL, Nischal KK. Management of descemet membrane detachment after forceps birth injury. *Cornea*. 2017;36(3):375–6.

Author biography

Aditi Pradeep Parab, Cornea Fellow  <https://orcid.org/0000-0001-9849-9353>

Josephine S Christy, Head of Cornea and Refractive Services

Vaibhav Khanna, Consultant

Cite this article: Parab AP, Christy JS, Khanna V. Descemet's membrane tears following forceps delivery. *Indian J Obstet Gynecol Res* 2024;11(1):132-134.