

Content available at: <https://www.ipinnovative.com/open-access-journals>

Indian Journal of Obstetrics and Gynecology Research

Journal homepage: www.ijogr.org

Case Series

A case series on live ectopic pregnancy

Prantik Meddya^{1*}, Malay Kumar Nandi¹

¹Dept. of Obstetrics and Gynaecology, Bankura Sammilani Medical College, Bankura, West Bengal, India



ARTICLE INFO

Article history:

Received 05-11-2023

Accepted 27-12-2023

Available online 17-02-2024

Keywords:

Live

Oral contraceptive pills

Pelvic inflammatory disease

Cornual ectopic

Methotrexate

ABSTRACT

A pregnancy which develops outside uterus is called ectopic pregnancy that comprises nearly two percent of total pregnancies. In first case a 25years old female presented with lower abdominal pain and bleeding per vagina with 3 months of amenorrhea and history of irregular oral contraceptive pill use. A live ectopic pregnancy of 12 weeks 3 days gestation found on right fallopian tube during laparotomy and right salpingectomy was done. In second case, a third gravida mother presented with bleeding per vagina and lower abdominal pain with history of 2.5 months of amenorrhea and chronic pelvic inflammatory disease. During laparotomy, both sided hydrosalpinx and left sided live ectopic pregnancy found on the distal end of fallopian tube and left salpingectomy with right sided tubal ligation was done. In third case, a third gravida mother with history of lower uterine caesarean section and ruptured left sided tubal ectopic pregnancy previously, presented with lower abdominal pain with 2 months of amenorrhea. Ultrasonography diagnosed a live right sided cornual ectopic pregnancy of 6weeks 6days and conservative management with injection methotrexate was started. Later due to sudden hemodynamic instability, emergency laparotomy was done and ruptured right cornual ectopic pregnancy was found and treated with total abdominal hysterectomy. All these cases were managed successfully. This case series emphasizes that early serological and sonographic diagnosis of location of pregnancy is necessary, there should be high suspicion for ectopic pregnancy even beyond the first trimester and the decision of conservative management in early ectopic pregnancy should be taken judiciously after checking all parameters of the patient.

This is an Open Access (OA) journal, and articles are distributed under the terms of the [Creative Commons Attribution-NonCommercial-ShareAlike 4.0 License](https://creativecommons.org/licenses/by-nc-sa/4.0/), which allows others to remix, tweak, and build upon the work non-commercially, as long as appropriate credit is given and the new creations are licensed under the identical terms.

For reprints contact: reprint@ipinnovative.com

1. Introduction

An ectopic pregnancy occurs when a fertilized ovum gets implanted outside normal uterine cavity.¹ It is one of the most common causes of extrauterine pregnancy is 1.3-2.4% worldwide² and in India it is 1-2%³. Most common site of ectopic pregnancy is fallopian tube (90%) and it can also occur in the cervix, ovary, myometrium, broad ligament, previous caesarean section scar rarely.⁴ Extra-uterine pregnancy generally presents at 6-9 weeks of gestation.² Ectopic pregnancy generally presented with

history of amenorrhoea, abdominal or pelvic pain with or without bleeding per vagina and even haemorrhagic shock in case of ruptured ectopic pregnancy. To diagnose an ectopic pregnancy clinical suspicion along with Trans-abdominal sonography or Trans-vaginal sonography and serological confirmation of pregnancy is needed.⁵ In this article three case reports (all were un-booked patients) have been discussed about live ectopic pregnancy which were diagnosed and managed in Bankura Sammilani Medical College and Hospital, Bankura.

* Corresponding author.

E-mail address: prantikmb007@gmail.com (P. Meddya).

2. Case 1

A 25 years old female, gravida 3, parity 1+1, living issue one with one abortion followed by dilatation and curettage at ten weeks of gestational age during second pregnancy, presented with complaints of diffuse lower abdominal pain and mild bleeding per vagina for two days and vomiting for ten days. There was history of amenorrhoea for three months. Patient was oral contraceptive pills irregularly since her last pregnancy two years back. Urine pregnancy test came positive. There was no history of abortifacient intake or trauma or recent sexual intercourse. On examination, there was mild pallor with tachycardia (pulse rate 106 beats per minute) and blood pressure 110/66 mm Hg. On per abdominal examination mild tenderness was present in the right iliac fossa and hypogastrium region. On per vaginal examination uterus was normal in size and a 3x3 cm² globular mass felt in right adnexa with right adnexal fullness, tenderness along with cervical motion tenderness and mild bleeding per vagina. On investigation, hemoglobin 8.7gm% with beta-HCG 1,18,327 mIU/ml. Trans-abdominal sonography showed a well defined thick walled sac like structure of 4x3.5 cm² the right adnexa with live fetus of 12weeks 3 days maturation with CRL(crown rump length) of 5.8cm, mild free fluid present on pouch of Douglas. She was diagnosed with right sided tubal ectopic pregnancy of 12 weeks and planned for emergency laparotomy. During laparotomy an intact gestational sac with live fetus found on right sided fallopian tube and right ovary, left fallopian tube and ovary were healthy.

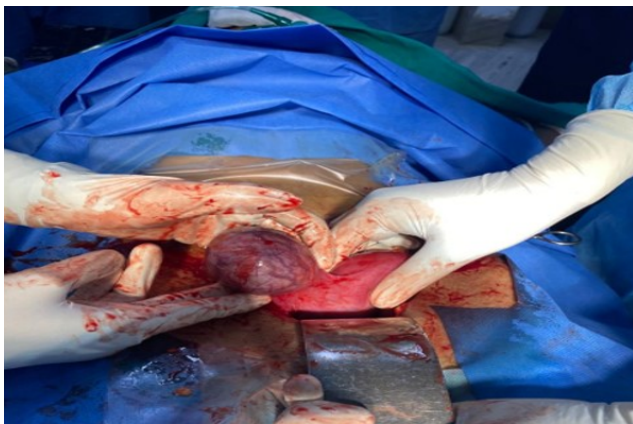

Figure 1: Ectopic pregnancy of right side

Right salpingectomy done and nearly 100ml of serosanguinous free fluid found. Peritoneal lavage and intra-abdominal drain given. Patient received one unit packed red blood cell post operatively. Patient was discharged in stable condition six days after surgery.

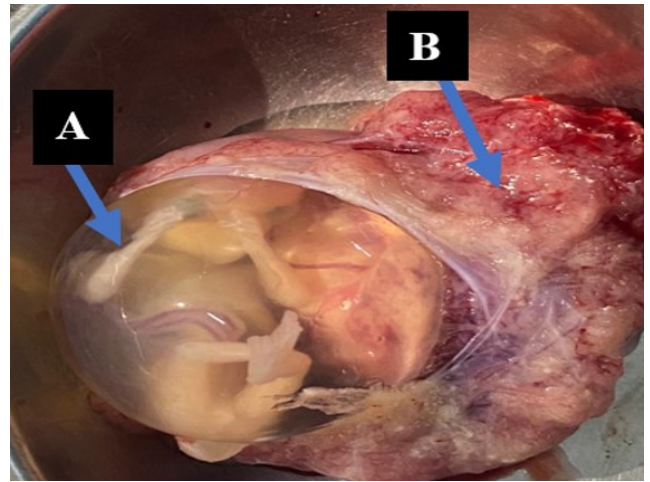


Figure 2: A → Fetus, B → Placenta

3. Case 2

A 36 years old, gravida 3, parity 2+0 (both normal vaginal delivery, last child birth 18 years ago), presented with complaints of bleeding per vagina and pain in the lower abdomen since last 1 week. She had history of amenorrhoea for 2.5 months. She was taking oral contraceptive pills 15 years regularly and irregularly for last 3 years, and she was suffering chronically with white discharge and pelvic inflammatory disease. On examination, pulse rate was 106 beats per minute, Blood pressure was 112/76 mm Hg, mild Pallor was present. There was no history of abortifacient intake or trauma or recent sexual intercourse. Per abdominally there was mild tenderness in left iliac fossa and hypogastrium. On per vaginal examination cervical motion tenderness was present along with left adnexal fullness and tenderness and mild bleeding per vagina. On investigation, hemoglobin 9.0gm%, beta-HCG 80,027mIU/ml. Transvaginal sonography showed bulky uterus, heterogenous with extra-uterine gestational sac noted in left adnexa containing live fetus of 8weeks 4days (CRL of 10.2 mm), left and right ovary healthy, suggestive of ectopic pregnancy. Patient underwent emergency laparotomy and left sided ectopic pregnancy found in the distal part of fallopian tube and bleeding was present from the fimbrial region. Left and right ovary were healthy. Right and left sided hydrosalpinx were present. Left salpingectomy with fimbriectomy along with right sided tubal ligation done.

500 ml of hemoperitoneum was present and it was suctioned out. Peritoneal lavage and intra-peritoneal drain were given. Patient received 1 unit whole blood intra-operatively and she was discharged in stable condition 6 days after surgery. After 1 month during follow up beta-HCG was <5 mIU/ml.

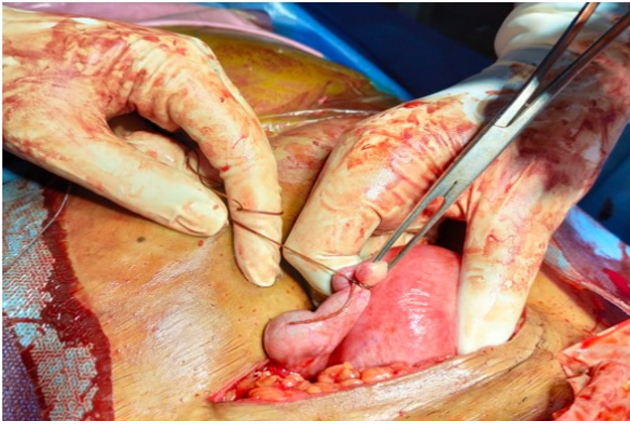


Figure 3: Tubal ligation in right sided hydrosalpinx

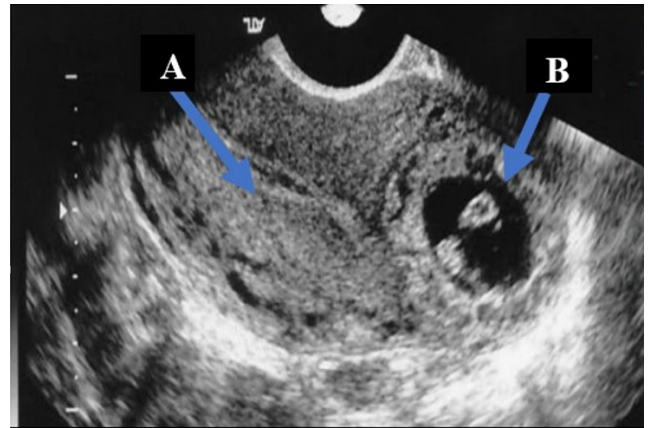


Figure 5: A → Uterus, B → Cornual ectopic pregnancy

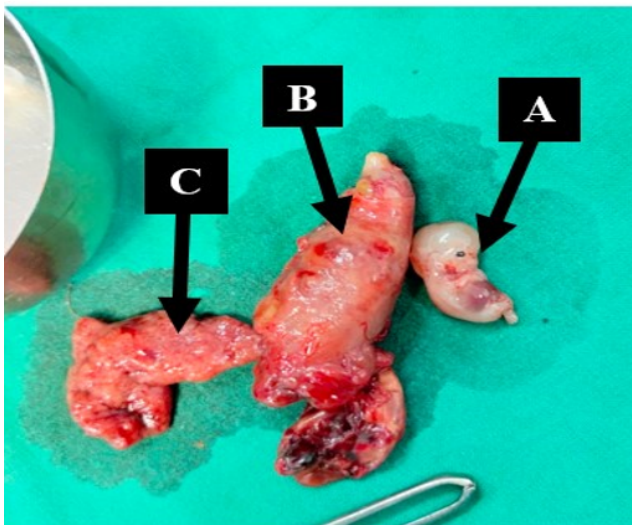


Figure 4: A → Fetus, B → Left fallopian tube, C → Placenta

4. Case 3

A 30 years old, gravida 3, parity 1+1 (LUCS in first pregnancy 8 years ago and second pregnancy was ruptured tubal ectopic pregnancy of left side of 7 weeks gestation which was treated by left salpingectomy 5 years ago), presented with lower abdominal pain for 2 days with amenorrhoea for 2 months. On examination, urine pregnancy test was positive, pulse rate 90/minute, blood pressure 120/76 mm Hg, mild pallor present. Per abdominally, mild tenderness was present in hypogastrium. Per vaginally uterus was mild bulky and there was no cervical motion tenderness or adnexal fullness. On investigation, hemoglobin was 9.8gm%, beta-HCG 12,212 mIU/ml. On trans-vaginal sonography, a 3x2.8x2.6 cm³ thick echogenic round mass with an apparent fetal pole of 11 mm with gestational age of 6weeks 6days with positive cardiac activity present on right cornual region and there was no free fluid in pouch of Douglas.

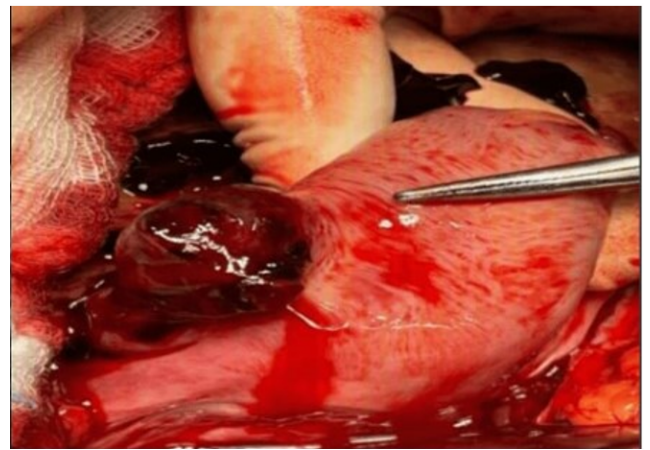


Figure 6: Right sided ruptured cornual ectopic pregnancy

After discussing the risk is to benefit ratio with the patient and patient party, conservative management was started with Injection Methotrexate 50mg/m² intra-muscularly as it is a fertility sparing treatment and Methotrexate halts the trophoblastic growth. After 18 hours patient complained of acute abdominal pain with bleeding per vagina. On examination, pulse rate 120 beats per minute, blood pressure 90/56 mm Hg. Per abdominally severe tenderness present in hypogastrium and per vaginally, severe cervical motion tenderness with fullness in pouch of Douglas was present and hemoglobin was 7.8gm% on hemoglobinometer. Emergency laparotomy was done and 3x3 cm² right cornual ectopic pregnancy found which was ruptured on posterior surface. 1 litre of blood clot was found intra-abdominally. The ectopic pregnancy was removed but due to uncontrolled bleeding from the cornual end, total abdominal hysterectomy was done. Post-operatively pulse rate 120 beats/minute, blood pressure 100/56 mm Hg, oxygen saturation 94% on room air and she was shifted to HDU. Patient received 1unit whole blood intra-operatively and total 2unit PRBC was transfused post operatively. After

48 hours she was shifted to septic ward and after 7 days post-operatively she was discharged in stable condition. On 1 month follow up beta-HCG was <2mIU/ml.

5. Discussion

Ectopic pregnancy causes 75% of maternal death in first trimester and 9-13% of all pregnancy related deaths.⁶ In majority of cases ectopic pregnancies implant in different sites of fallopian tube, most commonly in the ampulla(70%) followed by isthmus(12%), fimbria (11.1%) and interstitium(2.4%).⁷

There are many risk factors associated with ectopic pregnancy such as previous ectopic pregnancy, tubal damage or adhesion from pelvic infection or prior abdomino-pelvic surgery, history of infertility, in-vitro fertilization treatment, increased maternal age, smoking. However, there is no identifiable causes in 50% of cases.^{8,9}

Current use of oral contraceptive pills reduces the risk of unwanted intrauterine pregnancy AOR=0.04(0.02-0.08) and ectopic pregnancy AOR₁=0.14(0.07-0.26). However, when contraceptives failed and pregnancy occurred, current use of oral contraceptive pills increase the risk of ectopic pregnancy AOR₂=4.08(1.64-10.07) compared with the non-use of contraceptives.¹⁰

Factors		
High risk (OR > 4.0)	Moderately elevated risk (OR > 2.0)	Mildly elevated risk (OR < 2.0)
- prior tubal surgery adjusted OR: 4.0 (2.6-6.1); OR: 4.7-21.0	- sterility adjusted OR: 2.1-2.7; OR: 2.5-21.0	- age over 40 years (OR: 1.4-6.1)
- prior extrauterine pregnancy (OR: 6.0-11.5)	- current or prior ascending infection adjusted OR: 3.4 (2.4-5.0); OR: 2.5-3.7	
- sterilization (OR: 4.9-18.0)	- cigarette smoking adjusted OR: 1.5 (1.1-2.2); OR: 2.3-2.5	
- use of intrauterine device adjusted OR: 2.4 (1.2-4.9); OR: 4.2-45.0	- more than one sexual partner (OR: 2.1-2.5)	
- intrauterine exposure to diethylstilbestrol (OR: 2.4-13.0)	- tubal pathology adjusted OR: 3.7 (1.2-4.8); OR: 2.5-3.5	

*adjusted for prior ascending infection, cigarette smoking, educational level, and region of origin; OR, odds ratio.

Figure 7: Risk factors of extra-uterine pregnancy^{8,9}

Tubal pregnancy often becomes symptomatic in the first trimester due to lack of submucosal layer and implantation in the muscular layer of the fallopian tube which allows the proliferating trophoblast to erode the muscular layer. This usually leads to tubal rupture at 7.2 weeks ±2.2.⁷ Gari R et al. reported a case of live 13 weeks ruptured ectopic pregnancy.¹¹ In case number 1, unruptured tubal ectopic found at 12 weeks 3 day gestation. So, treating clinician should have high suspicion of ectopic pregnancy even beyond early first trimester.

In case number 2, chronic pelvic inflammatory disease was probably the cause of hydrosalpinx and along with this, irregular use of oral contraceptive pills and old age has lead to the ectopic pregnancy.

Cornual ectopic pregnancy (interstitial pregnancy) is rare type of ectopic pregnancy. It comprises 2%-4% of all ectopic pregnancy and 1/2500-1/5000 of all pregnancies.¹²⁻¹⁴ The embryo embeds in the funnel shaped

junction between uterus and fallopian tube.¹² It has high morbidity and mortality (2.2%-2.5%) in the first trimester.^{13,15} Without early diagnosis it can grow and causes uterine rupture and bleeding.^{13,16}

Though cornual resection and hysterectomy is the traditionally accepted surgery, the fertility is affected.^{12,15,16} Successful management includes early ultrasonographic diagnosis, laparoscopic resection and suturing of the uterine cornua.¹³ Conservative management can be tried by halting the growth and development of the embryo, allowing resorption of the gestational sac¹⁷ and for this Methotrexate is used as it arrests the growth of the trophoblasts by inhibiting the DNA synthesis.¹⁸ Methotrexate is the most commonly used chemotherapeutic agent for the conservative management of early ectopic pregnancy with a success rate of 91% and upto 66.7% in cornual ectopic pregnancy.^{12,17} Meical treatment with methotrexate is less effective when gestational age is >9weeks, beta-HCG >10,000 mIU/ml, fetal cardiac activity is present and when crown-rump length is > 10mm.^{17,18}

In our case number 3, beta-HCG> 10,000, CRL of 11mm describes the methotrexate failure. After this failure, if patient's condition was stable, then ideal treatment would be wedge resection of ectopic pregnancy and cornual region of uterus to preserve the uterine integrity.^{16,17} But due to hemodynamic instability, hysterectomy was performed.

All these patients were un-booked. The hospital where all these cases were managed, is a tertiary care hospitals and majority of patients who came here are from low socio-economic background and from remote and low resource areas. Health and pregnancy related awarenesses are very limited in those areas and early pregnancy diagnosis and its proper follow up is very difficult to perform. 1st antenatal visit mainly occurs in the late first trimester, in some cases even in the mid second trimester. That's why the locations of the pregnancies are generally diagnosed lately and early diagnosis of ectopic pregnancies are missed. Ectopic pregnancies are generally diagnosed lately in ruptured form with severe hemoperitoneum and severe hemodynamic instability of the patients.

6. Conclusions

Ectopic pregnancies are one of the major causes of maternal mortality in first trimester. The rate of this extrauterine pregnancy is increasing day by day due to increased maternal age, smoking, in-vitro fertilization treatment, insufficient knowledge about the proper use of contraceptive pills, increased rate of pelvic inflammatory disease and poor hygiene mainly in the developing countries.

High index of suspicion, early ultrasonography, serum beta-HCG levels help in the early diagnosis of ectopic pregnancy. Unusual mode of presentation of ectopic pregnancy other than tubal rupture and yespresentation beyond early first trimester should be kept in mind when

managing a patient of ectopic pregnancy.

Patient's haemodynamic condition should be assessed thoroughly before deciding the mode of treatment and the decision also depends on the beta-HCG levels, size of the gestational sac and patient's desire for future fertility. Determining an upper limit of beta-HCG value at which conservative management with Methotrexate can be given is yet to be clear. Appropriate surgical treatment requires advanced laparoscopic skills and techniques to manage or avoid uterine haemorrhage and to reconstruct the cornua in cornual ectopic pregnancy.

Awareness should be spread in remote areas regarding early treatment seeking in case of missed period & irregular menstrual bleeding or spotting, self-identification of signs and symptoms of pregnancy, early 1st antenatal visit, early identification of location of pregnancy by ultrasonography in hospitals. These are possible by educating the ground level workers under rural health mission and arranging health camps more frequently.

7. Source of Funding

None.


8. Conflict of Interest


None.

References

1. ACOG Practice Bulletin No. 191: Tubal Ectopic Pregnancy. *Obstet Gynecol.* 2018;131(2):65–77.
2. Taran FA, Kagan KO, Hübner M, Hoopmann M, Wallwiener D, Brucker S. The Diagnosis and Treatment of Ectopic Pregnancy. *Dtsch Arztebl Int.* 2015;112:693–704.
3. Tahmina S, Daniel M, Solomon P. Clinical Analysis of Ectopic Pregnancies in a Tertiary Care Centre in Southern India: A Six-Year Retrospective Study. *J Clin Diagn Res.* 2016;10(10):13–6.
4. Panelli DM, Phillips CH, Brady PC. Incidence, diagnosis and management of tubal and nontubal ectopic pregnancies: a review. *Fertil Res Pract.* 2015;1:15.
5. Belics Z, Gérecz B, Csákány MG. A méhenkíüvifogamzás korai diagnosztikája. *Orv Hetil.* 2014;155(29):1158–66.
6. Gaskins AJ, Missmer SA, Rich-Edwards JW, Williams PL, Souter I, Chavarro JE. Demographic, lifestyle, and reproductive risk factors for ectopic pregnancy. *Fertil Steril.* 2018;110(7):1328–37.
7. Khalil MM, Shazly SM, Badran EY, Shazly SAM, Ali MK, Badee AYA. An advanced second trimester tubal pregnancy: case report. Middle East. *Fertil Soc J.* 2012;17:136–8.
8. Ankum WM, Mol BW, Veen FVD, Bossuyt PM. Risk factors for ectopic pregnancy: a meta-analysis. *Fertil Steril.* 1996;65(6):1093–9.
9. Mol BW, Ankum WM, Bossuyt PM, Veen FV. Contraception and the risk of ectopic pregnancy: a meta-analysis. *Contraception.* 1995;52(6):337–41.
10. Li C, Zhao WH, Meng CX. Contraceptive Use and the Risk of Ectopic Pregnancy: A Multi-Center Case-Control Study. *PLoS One.* 2014;9(12):e115031.
11. Gari R, Abdulqader R, Abdulqader O. A Live 13 Weeks Ruptured Ectopic Pregnancy: A Case Report. *Cureus.* 2020;12(10).
12. Tuncay G, Karaer A, Coskun EI, Melekoglu R. Treatment of unruptured cornual pregnancies by local injections of methotrexate or potassium chloride under transvaginal ultrasonographic guidance. *Pak J Med Sci.* 2018;34(4):1010–3.
13. Varun N, Nigam A, Elahi AA, Jain A. Cornual ectopic pregnancy: laparoscopic management step by step. *BMJ Case Rep.* 2018;2018:bcr2017223998. doi:10.1136/bcr-2017-223998.
14. Dagar M, Srivastava M, Ganguli I, Bhardwaj P, Sharma N, Chawla D. Interstitial and Cornual Ectopic Pregnancy: Conservative Surgical and Medical Management. *J Obstet Gynaecol India.* 2018;68(6):471–6.
15. Chang YW, Tsai HW, Wang PH, Wu H, Twu NF, Yen MS, et al. Single-port laparoscopic surgery for cornual pregnancy after failure of methotrexate treatment. *Taiwan J Obstet Gynecol.* 2015;54(3):322.
16. Liao CY, Tse J, Sung SY, Chen SH, Tsui WH. Cornual wedge resection for interstitial pregnancy and postoperative outcome. *Aust N Z J Obstet Gynaecol.* 2017;57(3):342–45.
17. Tinelli R, Stomati M, Surico D, Cicinelli E, Trojano G, Angioni S. Laparoscopic management of a cornual pregnancy following failed methotrexate treatment: case report and review of literature. *Gynecol Endocrinol.* 2020;36(8):743–5.
18. Andrés MP, Campillos JM, Lapresta M, Lahoz I, Crespo R, Tobajas J. Management of ectopic pregnancies with poor prognosis through ultrasound guided intrasacular injection of methotrexate, series of 14 cases. *Arch Gynecol Obstet.* 2012;285(2):529–533.

Author biography

Prantik Meddya, PG Student  <https://orcid.org/0009-0006-3930-6981>

Malay Kumar Nandi, Associate Professor  <https://orcid.org/0009-0004-4230-0957>

Cite this article: Meddya P, Nandi MK. A case series on live ectopic pregnancy. *Indian J Obstet Gynecol Res* 2024;11(1):140-144.