

## Role of diagnostic hystero-laparoscopy in management of infertility

Vasundhara P<sup>1,\*</sup>, Satya Sowjanya K<sup>2</sup>

<sup>1</sup>Professor, <sup>2</sup>Junior Resident, Dept. of Obstetrics & Gynecology, Katuri Medical College & Hospital, Guntur, Andhra Pradesh

**\*Corresponding Author:**

Email: ananthavasup@gmail.com

### Abstract

**Background of the study:** Globally the incidence of infertility is increasing. Infertility affects 10-15% of couple of reproductive age group. 12% of the female population of reproductive age were reported infertile in 2002 national survey of family growth. Infertility is a social stigma and psychological trauma to the couple. The couple should undergo battery of investigations to diagnose their cause for infertility. Most of the time, the work up is cumbersome and time consuming. Once diagnosis is achieved treating that cause takes some more time. To avoid this problem we need a proper test to diagnose and treat the problem early. Diagnostic hystero-laparoscopy is such a type of test to diagnose accurately and to treat properly at the same time

**Aim of the study:** The Primary aim of the study is to detect the anatomical abnormalities in the reproductive organs in infertile women by doing diagnostic hystero- laparoscopy, and also to compare the results with other modalities of diagnostic procedures like hysterosalpingography, transvaginal ultrasonography, Secondary aim is to treat the anomalies while doing hystero-laparoscopy.

**Keywords:** Infertility, Diagnostic hystero-laparoscopy, Hysterosalpingography, Transvaginal ultrasonography, Infertile women

### Introduction

Infertility is “a disease of the reproductive system defined by the failure to achieve a clinical pregnancy after 12 months or more of regular unprotected sexual intercourse”.<sup>(2)</sup> The diagnosis and treatment of this disorder is gaining importance because of availability of information about treatment options. Fertility medicine has become one of the most rapidly evolving area in medicine.

The female factor accounts for 33% of cases of infertility. Women reach maximum fertility potential at the age of 24 yrs and it starts to decline from the age of 30yrs. So the diagnosis and treatment should be quick and meticulous. Experience has shown that majority of pelvic pathology in infertile women is frequently not well appreciated by routine pelvic examinations and the usual diagnostic procedures.

Direct visualisation of the reproductive organs and correction of pathology will be needed for better outcome. Diagnostic hystero laparoscopy will fulfil the criteria and helps the treating physician. The present study was done to analyse the causes and treatment of female factor of infertility by using diagnostic hystero laparoscopy.

### Materials and Methods

The study was conducted at Katuri Medical College and Hospital, Chinakondrapadu, Guntur district, Andhra Pradesh, over a period of 2 years.

Both primary and secondary causes of infertility were considered in this study.

Women aged 20-40 years with normal hormone profile without male factor infertility were included.

History was taken from each woman who was enrolled in this study, which included social status, marital life, Present and past medical and surgical

illnesses, drug addictions, coital history and family history. Detailed clinical examination was done for all the subjects.

Each couple was explained about the management protocol and procedure, uses and complications hystero-laparoscopy.

Out of 258 counselled 198 women accepted for the management. Informed and written consent was taken from all the women in this study.

Out of them 146 women were with primary infertility and 52 women with secondary infertility.

They were investigated with haemogram, blood grouping and typing, thyroid profile and renal function tests, chest X-ray and transvaginal/trans abdominal ultrasound.

Trans vaginal sonography(TVS) was performed to identify uterine anomalies and pathology in endometrium, fallopian tubes and ovaries.

Hystero-salpingography(HSG) was performed between day-8<sup>th</sup> and day- 11<sup>th</sup> of the cycle with a radio opaque dye, Urograffin. HSG was done to know the uterine anomalies and tubal patency.

Diagnostic hystero-laparoscopy will help to visualise the genital organs from both inside and outside with naked eye.

After pre anaesthetic check-up these women were posted for diagnostic hystero-laparoscopy under general anaesthesia. Through abdominal ports entire pelvic cavity and organs were visualised. By doing hysteroscopy the uterine cavity, endometrium and ostia were examined. Methylene blue a water soluble dye was injected into the uterine cavity through cervical cannal, and observed for the spillage into the pelvic cavity from the fimbrial end with the help of laparoscope. The abnormalities identified during the procedure were treated simultaneously.

Post-operative care was given for all women and they were allowed soft diet 6 hrs after the procedure. I.V antibiotics were given for 24hrs followed by oral antibiotics for five days. Adequate analgesia was given. The women were discharged after 48hrs. Before discharging each woman was explained about the cause of the infertility, treatment given and plan of management.

The results of each procedure, HSG, TVS, and DHL were compared with each other. The results are analysed with percentages and proportion

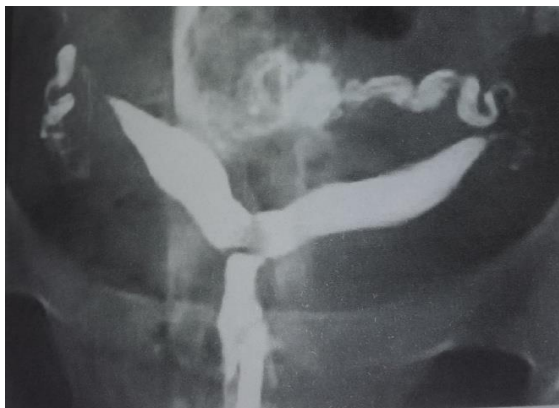

Fig. 1: Bicornuate uterus on HSG

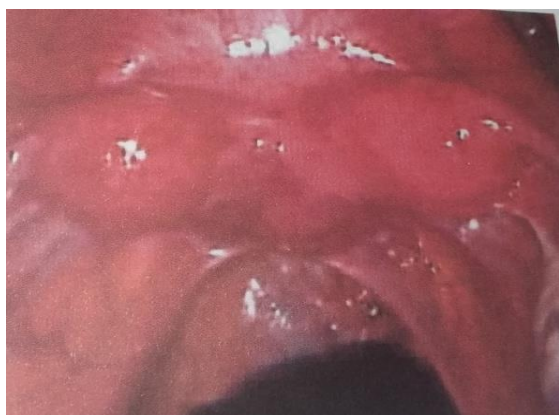


Fig. 2: Bicornuate uterus on DHL

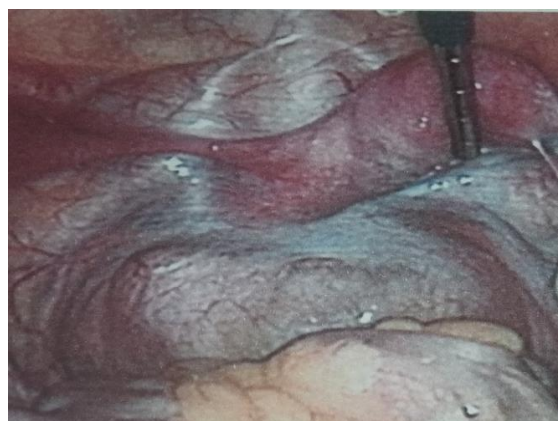

Fig. 3: Unicornuate uterus on laparoscopy

**Results**

The causes analysed for the infertility by TVS, HSG and DHL are PCOS, congenital anomalies of uterus, endometrial hyperplasia, endometrial polyp, leiomyoma, segmental agenesis/block of the fallopian tubes, hydrosalpinx, ovarian cysts, pelvic adhesions, tuberculosis and endometriosis.

**Table 1**

S. No	Pathology observed
1	Uterine anomalies
2	PCOS
3	Polyps
4	Endometrial hyperplasia
5	Tubal agenesis/block
6	Hydrosalpinx
7	Fibrotic ostia
8	Ovarian cyst
9	Endometriosis
10	Tuberculosis(pelvic adhesions)

Out of 198 who were investigated, a total of 65 abnormalities were detected in 60 women with infertility.

By doing only TVS 32 women with abnormalities were identified out of 198 women.

**Table 2**

S. No	Pathology observed	No. of patients	Percentage
1	PCOS	24	12.1
2	Ovarian cyst	02	1
3	Uterine anomalies	05	2.5
4	Endometrial hyperplasia	01	0.5
Total		32	15.7

17 women were identified having pathology by doing only HSG.

**Table 3**

S. No	Pathology observed	No. of patients	Percentage
1	Uterine anomalies	9	4.5
2	polyps	1	0.5
3	Hydrosalpinx	2	1
4	Tubal block	5	15
5	Total	17	8

With the help of hystero laparoscopy anomalies detected in 60 women.

**Table 4**

S. No	Pathology observed	No. of patients	Percentage
1	Uterine anomalies	16	8.1
2	PCOS	22	11

3	Polyps	3	1.5
4	Endometrial hyperplasia	1	0.5
5	Tubal agenesis	2	1
6	Hydrosalpinx	2	1
8	Ovarian cyst	3	1.5
9	Pelvic adhesions	3	1.5
10	Endometriosis	3	1.5
11	With >1 above mentioned abnormalities	5	2.5
Total		60	30

During the procedure of hystero laparoscopy corrective surgeries were done in 58 women. Uterine anomalies like unicornuate uterus, uterus didelphis, bicornuate uterus are left untreated because of the complications (adhesions leading to further infertility, abortions, adherent placenta to the scar, scar rupture during pregnancy).

Table 5

S. No	Pathology identified	Treatment given
1	Septate uterus	Septal resection
2	PCOS	Ovarian drilling
3	Polyps	Polypectomy
4	Endometrial hyperplasia	Curettage
5	Tubal block	Cannulation
6	Hydrosalpinx	Decompression
7	Fibrotic ostia	Cannulation
8	Ovarian cyst	Ovarian cystectomy
9	Pelvic adhesions	Adhesiolysis
10	Endometriosis	Fulguration

Comparison between TVS, HSG and DHL in the diagnosis of abnormality.

Table 6

Pathology identified	TVS	HSG	DHL
Uterine anomalies	5	9	16
PCOS	24	-	24
Polyps	1	1	4
Endometrial hyperplasia		-	1
Tubal agenesis	-	5	3
Hydrosalpinx	1	2	3
Fibrotic ostia	-	-	1
Ovarian cyst	1	-	3
Pelvic adhesions	-	-	5
Endometriosis	-	-	5
Total	32	17	65

Only 32 women were identified with pathology by TVS (16%), only 17 (9%) women by HSG.

Combination of these two, 42 (21%) women were identified with definite pathology.

14 women who presented with infertility and were initially considered normal, were identified to have a pathological reason after performing DHL.

Minor degrees of pelvic adhesions were not detected by both TVS and HSG.

By DHL 65 (32.5%) abnormalities were detected in 60 women and corrective surgeries done in 58 during the procedure itself. No anaesthetic and post-operative complications were observed in those women.

Septal resection done in 5 women and 3 out of them conceived. After ovarian drilling the response to hormone therapy was increased and out of 15 who were in regular follow up, 6 patients achieved pregnancy.

## Discussion

Infertility is "a disease of the reproductive system defined by the failure to achieve a clinical pregnancy after 12 months or more of regular unprotected sexual intercourse."

The diagnostic work up should be started in those couple as soon as possible. Women reach maximum fertility potential at the age of 24 yrs and it starts to decline from the age of 30yrs. So the diagnosis and treatment should be quick and meticulous.

The transvaginal sonography helps to visualise the genital tract from both inside and outside. But it has very high intra-observer and inter observer variations. The woman needs another appointment and equipment for the treatment.

Hysterosalpingography is simple and a very quick procedure and best to know about the uterine anomalies and tubal patency at out-patient department. But it cannot display the exterior of the genital organs, ovaries and pathology in the endometrium. Moreover it is not therapeutic.

Diagnostic hystero laparoscopy is now gaining importance because it can directly visualise the entire genital tract from both inside and outside at the same time.

With the naked eye the abnormality can be visualised so that inter-observer variations will be minimised. This will helps in picking up the diagnosis which was missed by doing both TVS and HSG.

Once the cause is identified therapeutic/corrective surgeries can be done immediately during the procedure in most of the patients.

When compared to other modalities of management of infertility it is less time consuming with good results. DHL has high specificity, diagnostic accuracy and it is cost effective. Subjecting the woman to anaesthesia and surgery will be associated with psychological stress and complications. It is the main limitation for this procedure. With the help of proper counselling and good surgical expertise we can overcome these short comings.

## Conclusion

Diagnostic hystero laparoscopy is superior to all other investigations as it has both diagnostic and

therapeutic approach. It gives promising results even though there is a risk of anaesthetic or surgical complications to the patient. Good knowledge and surgical skill of the surgeon will combat this. Its diagnostic accuracy and therapeutic options made it gold standard in treating a woman with infertility. Because of lesser hospital stay and less pain, many women of late are choosing this procedure. It is cost effective and definitive treatment is possible. Once the diagnosis is confirmed the women can be counselled for best available treatment options and protocols can be followed for good results.

### References

1. Speroff L, Mark A.F,(2005) Female infertility: clinical gynaecologic endocrinology and infertility, 7<sup>th</sup> edition, 1013-1068.
2. Chandra A, Martinez GM, Mosher WD, Abma JC, Jones J., Fertility, family planning and reproductive health of women: data from the 2002 National survey of family survey of family growth. National survey for health statistics. Vital health stat 23 2005;25:1-60.
3. Mol BW, Collins JA, Burrows EA, van der Veen F, Bossuyt PM. Comparison of hysterosalpingography and laparoscopy in predicting fertility outcome. Hum Reprod. 1999;14:1237-42.
4. Jayakrishnan K, Koshy AK, Raju R. Role of laparohysteroscopy in women with normal pelvic imaging and failed ovulation stimulation with intrauterine insemination. J Hum Reprod Sci.2010;3:20-4.
5. Godinjak Z, Idrizbegovic E. Should diagnostic hysteroscopy is a routine procedure during diagnostic laparoscopy in infertile women. Bosn J Basic Med Sci. 2008;8:44-7.
6. Tsuji I, Ami K, Miyazaki A, Hujinami N, Hoshiai H. Benefit of diagnostic laparoscopy for patients with unexplained infertility and normal hysterosalpingography findings. Tohoku J Homer HA, Li TC, Cooke ID.
7. The septate uterus: A review of management and reproductive outcome. Fertil Steril. 2000;73:1-14.