

Rupture of Unscarred Pregnant Uterus: A Catastrophic Event: Case series and Review of Literature

Naina Kumar^{1,*}, Shaveta Garg²

¹Associate Professor, ²Assistant Professor, Dept. of Obstetrics & Gynecology, Maharishi Markandeshwar Institute of Medical Sciences & Research, Ambala

***Corresponding Author:**

Email: drnainakumar@gmail.com

Abstract

Aim: To discuss risk factors associated with rupture of pregnant uterus, its diagnostic dilemmas and associated maternal and fetal complications. **Background:** Unscarred uterine rupture is rare and associated with high risk of maternal and fetal morbidity and mortality, especially in developing countries.

Case Description: Present case series discusses six cases of unscarred uterine rupture in pregnant women over a period of seven months in rural tertiary care centre of Northern India. All cases were un-booked and were referred for poor maternal condition. There were no maternal mortalities, but uterine rupture in all cases resulted in significant blood loss leading to features of shock, severe fetal distress and fetal deaths (five out of six cases), expulsion of fetus, placenta or both into abdominal cavity, injury to bladder and need for urgent exploratory laparotomy and uterine repair or hysterectomy. All these cases occurred in unscarred uterus and major risk factors were: grand multiparity, injudicious use of oxytocics and or prostaglandins for induction and augmentation of labor, malformed uterus.

Conclusion: Unscarred uterine rupture is increasing in developing countries due to poor health care facilities and lack of awareness amongst pregnant women. There are usually no specific signs for uterine rupture resulting in delay in diagnosis and loss of golden hour period when life of both mother and fetus can be saved. This can be prevented by creating awareness amongst pregnant women about regular antenatal check-ups, hospital deliveries, family planning and training medical and paramedical staffs at periphery for conducting deliveries.

Clinical Significance: Uterine rupture is a preventable catastrophic event with high maternal morbidity and fetal morbidity and mortality.

Keywords: Fetus; Bladder; Hysterectomy; Placenta; Uterine rupture; Shock.

Introduction

Uterine rupture is defined as disruption of full thickness uterine wall with expulsion of fetal parts and or placental tissue into peritoneal cavity.⁽¹⁻³⁾ It is a rare peri-partum complication associated with high maternal and fetal morbidity and mortality.^(4,5) Incidence of uterine rupture (both scarred, unscarred) has increased in last few years⁽⁶⁾ with an overall incidence of 0.03-0.3%.⁽⁷⁾ Spontaneous rupture of unscarred uterus is very rare, but its incidence is rising especially in developing countries, with an estimated incidence of 1/5700 to 1/20,000 pregnancies.⁽⁸⁻¹¹⁾ Also uterine rupture is more common in developing countries as compared to developed countries.^(2,12) Evidences report that spontaneous uterine rupture accounts for 13% of all cases of uterine rupture.⁽¹⁰⁾ A recent Indian study, reported an incidence of 0.17%⁽¹³⁾ accounting for 5-10% of all maternal deaths and 80-95% of perinatal mortalities^(14,15) in India due to uterine rupture.

Important risk factors for rupture of unscarred pregnant uterus include grand multi-parity, prolonged labor, over enthusiastic use of uterotonics, obstructed labor,⁽¹⁶⁾ mal-presentations, breech extraction⁽¹⁷⁾ and instrumental delivery.^(16,17) Other factors include trauma (motor vehicle injuries, obstetric maneuvers like forceful internal/external podalic versions), congenital (Ehlers-Danlos type IV)^(18,19) or acquired weakness of myometrium (due to protracted labor, use of strong and high doses of uterotonic drugs).^(20,21)

Uterine rupture especially unscarred one is associated with catastrophic maternal and fetal complications. The maternal mortality ranges between 1 and 13% and perinatal mortality between 74 and 92%.⁽²⁾

We therefore report six cases of unscarred uterine rupture in third trimester, where etiological factors were different (Table 1). In all cases there was no maternal mortality but five out of six fetuses were dead on delivery.

Table 1: Demographic features of women with rupture of unscarred uterus

| | Case 1 | Case 2 | Case 3 | Case 4 | Case 5 | Case 6 |
|----------------------------|---|---|---|---|---|--|
| Age | 25 years | 29 years | 22 years | 31 years | 33 years | 27 years |
| Parity | G2P1L1 | G3P2L2 | Primigravida | G4P3L3 | G5P4L4 | G3P1L1A1 |
| Previous mode of delivery | Preterm vaginal delivery | Two normal deliveries | - | Three normal deliveries | Four normal deliveries at home | One normal delivery, followed by one Medical termination of pregnancy |
| Gestational age | 29+2 weeks | 39+2 weeks | 38+3 weeks | 36 weeks | 39+4 weeks | 38+5 weeks |
| Hemoglobin at presentation | 5 gm% | 4 gm% | 5.5 gm% | 6 gm% | 4.5% | 7 gm% |
| Management | Exploratory laparotomy with hemi-hysterectomy | Exploratory laparotomy with total hysterectomy, bladder repair and Double-J stenting of both ureters | Exploratory laparotomy with subtotal hysterectomy | Exploratory laparotomy with subtotal hysterectomy | Exploratory laparotomy with total hysterectomy | Exploratory laparotomy with repair of uterine rent |
| Site of uterine rupture | Fundus of right horn of bicornuate uterus | Lower segment of uterus extending to involve left vaginal vault and posterior wall of bladder including trigone | Posterior wall of uterus 2-3 cms below fundus | Fundal rupture | Lower segment of uterus extending downwards on right side involving vaginal vault | Anterior wall 4 cms below fundus |
| Injury to adjacent organs | - | Bladder rupture in trigonal region | - | - | - | - |
| Units of blood transfusion | 4 | 5 | 4 | 2 | 4 | 2 |
| Fetal outcome | Dead and lying in abdominal cavity | Dead and lying in abdominal cavity | Dead and breech of fetus protruding into abdominal cavity along with placental tissue | Dead and lying in abdominal cavity | Dead and lying in abdominal cavity | Live fetus with one shoulder and hand protruding in abdominal cavity. Baby was put on ventilator support for few days, but survived. |
| Fetal weight | 1.3 Kg | 3.4 Kg | 2.8 Kg | 2.7 Kg | 3.3 Kg | 3 Kg |

Case Description

Case 1: Uterine rupture with bicornuate uterus: A 25 years old un-booked pregnant women (Gravida: 2, Para: 1 and Live: 1) at 29+2 weeks of gestation with previous one preterm vaginal delivery reported to labor room in emergency hours with history of amenorrhea since 7^{1/2} months with pain in abdomen since one day followed by sudden syncopal attack. On admission patient was semi-conscious with blood pressure 80/60 mm of Hg, pulse rate 126 beats per minute. On per abdominal examination; abdomen was tense and tender, uterine contour was not well defined, fetal parts were easily palpable and fetal heart sound was not audible on

stethoscope. On per speculum examination cervical os was open, show present, on per-vaginal examination cervix was one finger loose, 20-30% effaced, presenting part not felt. The patient was managed immediately with rapid infusion of fluids through wide bore cannula, catheterization done, blood samples were sent for all investigations and cross matching for transfusion. Her urgent hemoglobin was 5 gm/dl. Emergency bedside ultrasound revealed uterine rupture with dead baby in abdominal cavity and massive hemo-peritoneum. Patient was shifted immediately to operation theatre for exploratory laparotomy with two units of blood. Intra-operatively uterus was bicornuate

with rupture of non-communicating right horn at fundus. The dead fetus was lying in abdominal cavity with part of placenta protruding through ruptured horn into abdominal cavity. Around 2-2.5L of blood was present in abdominal cavity (Fig. 1). Hemi-hysterectomy or right horn was done with left intact horn with bilateral tubes and ovaries preserved. Patient was put on antibiotics for seven days, her post-operative period was uneventful. After four units of blood transfusion, patient was discharged under satisfactory condition. Patient was counseled about contraception and was advised not to conceive in future.

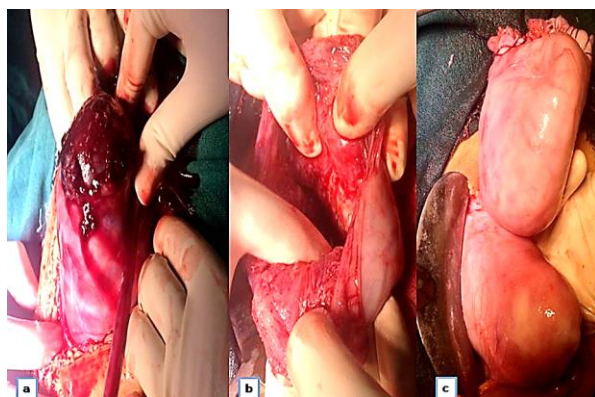


Fig. 1: a) Bicornuate uterus with ruptured right non-communicating horn with placental tissue seen through it, b) Ruptured non-communicating horn, c) Bicornuate uterus before hemi-hysterectomy

Case 2: Term rupture of unscarred uterus with bladder rupture: A 29 years old un-booked pregnant woman (Gravida: 3; Para: 2 and Live: 2) at 39+2 weeks of gestation with previous two normal deliveries was referred to Obstetrics department of rural tertiary care centre in emergency hours with history of amenorrhea since nine months, pain in abdomen since three days, for which she was previously admitted to some local hospital in periphery. As per patient's relatives, she was put on intravenous infusion with some drug for augmentation of labor (records not available). Till afternoon she was having strong labor pains, after which she suddenly collapsed and was referred with one unit of blood on flow. On general examination patient was in a state of shock with blood pressure 80/60 mm of Hg, pulse rate 144/min, feeble. Patient was very pale. On per abdominal examination; abdomen was tense, tender, uterine contour could not be made out; fetal parts were felt easily, but fetal heart sound was not audible on stethoscope. On per speculum examination, cervical os was open with blood tinged liquor seen coming through os. On per vaginal examination cervix was 7-8 cms dilated, membrane absent with blood stained liquor, presenting part high up. On catheterization, there was frank hematuria. Two wide bore intravenous cannulas were inserted

immediately; blood samples were drawn for investigations, and cross-matching for arrangement of blood for transfusion. Her urgent hemoglobin was 4 gm/dl and emergency bedside ultrasonography revealed massive hemo-peritoneum with dead fetus lying in abdominal cavity. Patient was prepared and shifted for emergency exploratory laparotomy, taking all high risk consents and consent for hysterectomy. On opening the abdomen, cavity was full of blood (2-3L), uterus was ruptured from lower segment involving vaginal vault on left side, bladder was ruptured on posterior wall in trigonal region with bulb of Foley's catheter lying in abdominal cavity. The posterior wall of bladder was retracted with anterior vaginal wall. A term good size dead fetus was lying in abdominal cavity along with placenta. Left ureter was exposed from the Wertheim's tunnel (Fig. 2). With great difficulty anatomy was restored, posterior surface of bladder was dissected out from anterior vaginal wall, two small ureteric openings were seen at edge of torn bladder. Total hysterectomy was done with bilateral tubes and ovaries left in situ. After Double J stenting of ureters, as their opening was seen at torn edge of posterior wall, bladder repair was done. Abdominal cavity cleaned and after achieving complete hemostasis, abdomen closed in layers with drain placed in abdominal cavity. With five units of blood transfusion and higher antibiotic coverage patient recovered well. Double J stents were removed on day 21 along with foley's catheter and patient was discharged under satisfactory condition.

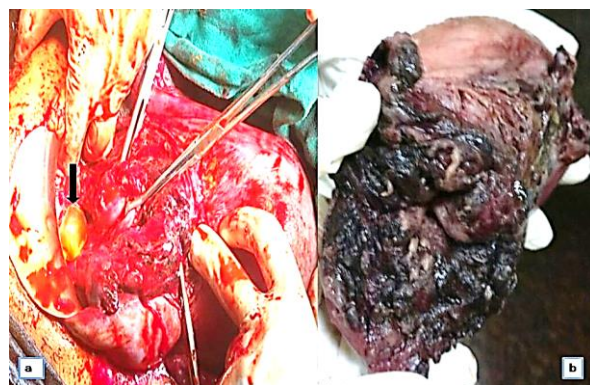


Fig. 2: a) Lower segment ruptured uterus extending to involve left vaginal vault along with posterior bladder rupture (Foley's catheter seen in abdominal cavity), b) Post-hysterectomy specimen

Case 3: Posterior uterine wall rupture in Primigravida: A 22 years old un-booked primigravida women at 38+2 weeks reported to labor room with history of amenorrhea since nine months, pain in abdomen since three days, leaking per vaginum since two days. As per the relatives patient was receiving treatment from some quack (dai), who had given her multiple injections for increasing labor pains. On general examination patient was conscious, well oriented to time place and person. Patient was very

pale, her blood pressure was 90/60 mm of Hg, pulse rate 138/min, feeble. On per abdominal examination, abdomen was tense and tender, uterine contour was lost, fetal parts were not felt properly, fetal heart sound could not be localized by stethoscope. On per speculum examination cervical os was open, blood mixed liquor was seen coming through it. On per vaginal examination cervix was 4 cms dilated 40-50% effaced, vertex high up. Patient was immediately catheterized, intravenous fluids started, blood samples sent for investigations and cross matching for arrangement of blood. Her hemoglobin was 5.5 gm/dl and an urgent obstetrics ultrasound revealed rupture of uterus in fundal region with fetal parts lying partially in abdominal and partially in uterine cavity with massive hemo-peritoneum (1.5-2L). Patient was shifted to operation theatre for urgent exploratory laparotomy with two units of blood. Intra-operative findings include: uterus was ruptured transversely on posterior wall 2-3 cms below fundus, breech of fetus up to umbilicus was seen coming through rent along with placental tissue (Fig. 3). There was blood in abdominal cavity around 1.5L. Dead baby was delivered, edges of ruptured uterus were necrosed, and an attempt was made to re-suture it, but on failing and due to continuous bleeding from rupture site and persistent fall in blood pressure; a decision for subtotal hysterectomy was made after taking consent from the relatives. Bilateral tubes, ovaries and cervix were left in situ. Abdomen was closed after achieving complete hemostasis. A total of four blood transfusions were given along with higher antibiotics. Her post-operative recovery was unremarkable and she was discharged in healthy condition on day 9 post-operative.

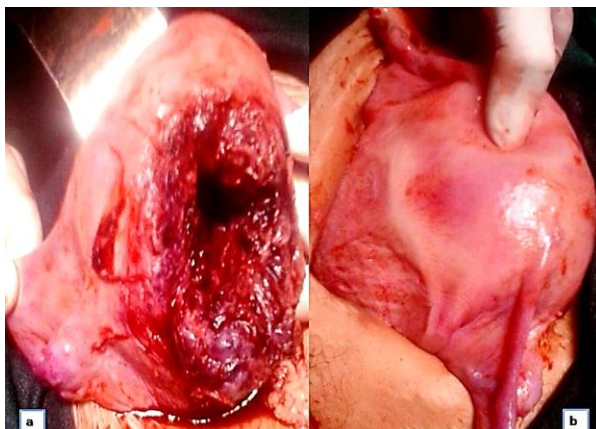

Fig. 3: a) Posterior wall uterine rupture, b) Anterior surface of uterus

Case 4: Uterine rupture at Fundus: A 31 years old un-booked grand-multipara women (Gravida: 5, Para: 3, Live: 3, Abortion: 1) at 36 weeks of gestation with previous three home deliveries was referred to rural tertiary care centre from periphery in morning hours with history of amenorrhea since nine months, followed

by pain in abdomen since two days. Patient was trying for home delivery since two days under some quack. After vigorous trial, when she failed to deliver she was taken to nearest peripheral health centre, from where she was referred. On admission her general condition was poor, she was semiconscious, pale, her blood pressure was 90/60 mm of Hg, pulse rate 126/min, hypovolumic and feeble. On per abdominal examination, abdomen was tense, tender, uterine contour could not be made out, fetal parts were not palpable and fetal heart was not audible. An urgent ultrasound revealed hemo-peritoneum with dead fetus along with placental tissue lying in abdominal cavity. After catheterization, sending all investigations and arranging blood for transfusion, patient was shifted for emergency exploratory laparotomy. Her immediate preoperative hemoglobin was 6 gm/dl. Her intra-operative findings include: rupture of whole of fundus of uterus with dead fetus lying in abdominal cavity with placenta (Fig. 4). Abdominal cavity was full of blood (2-2.5 l). Subtotal hysterectomy was done with bilateral tubes, ovaries and cervix left in situ. After a total of two transfusions patient recovered and was discharged under satisfactory condition on eighth post operative day.

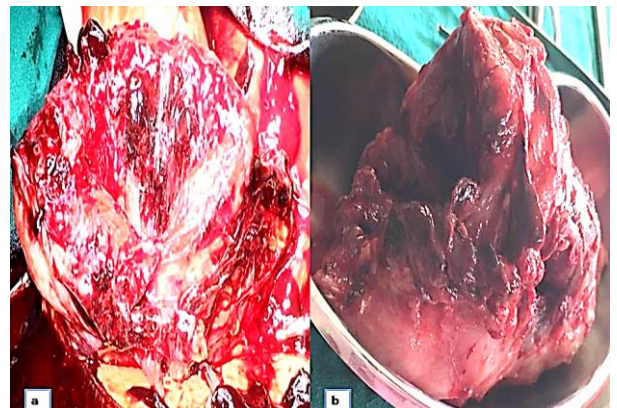


Fig. 4: a). Fundal rupture of uterus, b) Post-hysterectomy specimen

Case 5: Uterine rupture in Grand multipara: A 33 years old Gravida 5, Para 4 with Live 4 un-booked pregnant women at 39+3 weeks with singleton pregnancy was referred from periphery in evening hours with complaints of amenorrhea since nine months, pain in abdomen since two days. She was previously admitted to peripheral health centre with same complaints 2 days back; where normal delivery was tried, but when patient fail to deliver she was referred to our centre. Patient was conscious well oriented to time place and person. According to patient, she had severe abdominal pain followed by sudden cessation of pain since early morning hours. On general examination patient had a sick look with severe degrees of palor, blood pressure 130/80 mm of Hg and pulse rate 136/min, feeble. On per abdominal examination,

abdomen was tense and tender with guarding and rigidity present. Uterus and fetal parts could not be palpated well due to rigidity and tenderness. There were no uterine contractions. Fetal heart sound was not audible with stethoscope. On per speculum examination cervical os was open, edematous with blood stained liquor seen coming through it. On per vaginal examination right antero-lateral lip of cervix was not felt, membranes were absent, blood tinged liquor seen and presenting part was very high up. Patient was catheterized immediately, intravenous line started with Ringer lactate, blood samples were sent for investigations and cross matching for arranging blood for transfusion. An urgent obstetric ultrasound was done, which revealed features of peritonitis with hemo-peritoneum. Fetus was dead with no cardiac activity and was high up. No comment could be made on uterus. Her hemoglobin was 4.5 gm/dl. Hence, after making a provisional diagnosis of uterine rupture from signs and symptoms, patient was shifted for urgent exploratory laparotomy with two units of blood ready for transfusion. On opening the abdomen, cavity was full of blood clots, peritoneum was thickened and signs of peritonitis were present indicating old rupture of uterus. The rupture was present in lower segment of uterus extending downwards on right side involving vaginal vault. Bladder was not injured as it was retracted downwards along with the anterior vaginal wall (Fig. 5). An assistant was made to introduce her hand through vagina and hand was found in abdominal cavity posterior to bladder and anterior vaginal wall. A dead fetus along with placenta lying in abdominal cavity was removed. The intestines, mesentery and peritoneum were all meconium stained. Total hysterectomy was done with bilateral tubes and ovaries left in situ. Bladder was sharply dissected out from anterior vaginal wall for vault closure. Abdominal cavity washed with warm saline and drain kept in abdominal cavity. Higher intravenous antibiotics were started. A total of four blood transfusions were given and patient was kept catheterized for seven days post-operatively. On day 8th patient developed high grade fever with moderate abdominal distention. All her investigations including urine culture, blood culture, dengue, malarial parasite and vaginal swabs were sent, which came out to be negative. A repeat ultrasound of abdomen with X-ray was done which revealed signs of old peritonitis. Patient's antibiotics were changed after which she started responding. Her distention settled and she became afebrile. On day 15th patient was discharged under satisfactory condition.

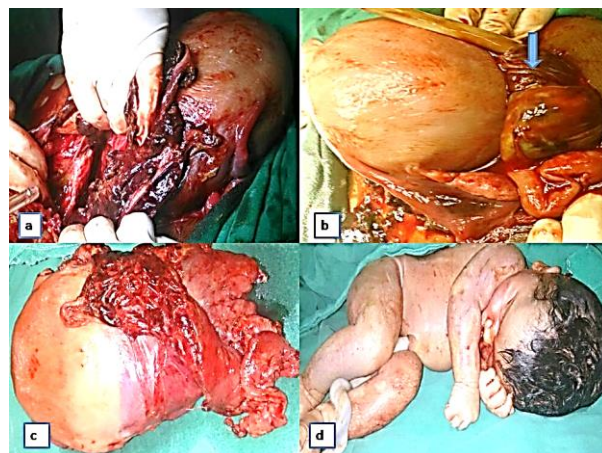


Fig. 5: a) Lower segment ruptured uterus extending to involve left vaginal Vault with bladder retracted anteriorly with anterior vaginal wall, b) Placenta lying posteriorly in abdominal cavity, c) Post-hysterectomy specimen, d) Term good size dead fetus

Case 6: Unscarred uterine rupture on anterior wall:

A 27 years old booked pregnant women (Gravida: 3, Para: 1, Live: 1 and Abortion: 1) at 38+5 weeks of gestation reported with complaints of amenorrhea since 9 months, pain in abdomen since one day and leaking per vaginum since 18 hours. On general examination patient was conscious, well oriented to time, place and person. Her blood pressure was 110/70 mm of Hg, pulse rate 110/ min. On per abdominal examination uterus was tense, tender, fetal parts could not be felt, fetal heart rate was slow with 90 beats per minute (bradycardia). On per speculum examination cervical os was open with thick meconium stained liquor seen coming through it. On per vaginal examination cervix was two finger loose 20-30% effaced, membranes absent, liquor meconium stained, presenting part (vertex) high up. Her urgent hemoglobin was 7 gm/dl and bedside ultrasound revealed hemo-peritoneum with small rent on anterior wall of uterus (2-3 cms) with live fetus in-utero. Patient was shifted immediately to operation theatre for emergency LSCS in view of fetal distress and rupture uterus. On opening the abdomen, hemo-peritoneum was seen (1L) with rent of 2-3cms on anterior wall of uterus around 4cms below fundus, with fetal part bulging through it. Immediately baby was delivered out through same rent, baby cried after resuscitation. Uterus was repaired in layers. After achieving complete hemostasis, abdomen was closed in layers. Two units of blood transfused. Baby was put on ventilator support for few days, but survived and was discharged under satisfactory condition. Post-operative period of the patient was uneventful and she was discharged along with the baby on day 21. Patient was counseled not to conceive in future and to use contraception.

Discussion

Uterine rupture is life threatening event during childbirth in which there is breach in integrity of myometrial wall.^(22,23) Rupture of unscarred uterus is very uncommon, but its incidence is increasing all over world, especially in developing countries.⁽²⁴⁾ It is usually associated with higher risk of maternal and neonatal morbidity and mortality as compared to cases with scarred uterine rupture.⁽²⁵⁾ In such case damage to uterus is many a time beyond repair and patient requires hysterectomy. It has been shown in many studies that lower segment is most common site for uterine rupture.^(3,5,26)

Major risk factors for rupture of unscarred uterus include high parity,⁽¹⁵⁾ injudicious use of uterotonic drugs, obstructed labor, placenta percreta. Another important factor is uterine malformations including bicornuate uterus or septate uterus. Pregnancy in bicornuate uterus is usually associated with poor reproductive outcome and requires close monitoring throughout pregnancy.^(27,28) It can rarely lead to uterine rupture during pregnancy.⁽²⁹⁾ It has been reported that rupture of rudimentary horn is associated with very high risk of fetal mortality and long term maternal morbidities, but maternal mortality is usually low around 0.5%.⁽³⁰⁻³³⁾

The diagnosis of pregnancy in rudimentary horn before rupture is very difficult and is mainly done by ultrasonography. Also sensitivity of ultrasound to detect pre-rupture rudimentary horn pregnancy is very poor (30%).⁽³¹⁻³³⁾ Hence this may result in delay in diagnosis, ultimately affecting the overall prognosis of fetal and maternal outcome. Furthermore in most cases, diagnosis of bicornuate uterus is incidental during pregnancy or delivery.^(28,29,34)

The important findings on ultrasound that suggest rudimentary horn pregnancy include; false pattern of an asymmetrical bicornuate uterus; loss of visual continuity of tissue around gestational sac and uterine cervix; presence of myometrial tissue around the gestational sac.^(33,35)

Injudicious use of oxytocics is strongly associated with uterine rupture, especially in developing countries.⁽³⁶⁾ The Cochrane reviews have shown that high misoprostol doses or smaller dosing intervals result in higher incidence of hyper-stimulation and hypersystole.⁽³⁷⁾ Various studies have also shown that low-dose oxytocin (physiologic), and high dose (pharmacologic) oxytocin regimens, when improperly titrated with uterine activity can result in major catastrophic events.⁽³⁷⁾

As uterine rupture in unscarred uterus is very rare, there is always a delay in making diagnosis because of nonspecific clinical signs^(1,2,10) which include variable and nonspecific maternal complaints and fetal status, requiring very high index of diagnostic suspicion.^(8,36) In most cases presenting features include maternal tachycardia, signs of fetal distress, and bleeding per

vagina.^(36,38) Hence, in any gravid woman presenting with features of hypotension, abdominal pain, fetal distress, and vaginal bleeding, one should always suspect of rupture uterus.^(1,8,36)

The maternal and fetal outcomes are most commonly related to time elapsed between diagnosis of uterine rupture and its management. Fetal outcome depending on time loss between diagnosis and delivery ranges from admission to neonatal intensive care unit, severe fetal hypoxia or anoxia to perinatal loss.^(39,40) Maternal consequences include massive blood loss leading to hypovolemic shock, injury to adjacent structures like bladder, need for peripartum hysterectomy, acute renal failure, Adult Respiratory Distress Syndrome (ARDS), disseminated intravascular coagulation (DIC)⁽⁴¹⁾ and even maternal death.

Uterine rupture is rarely associated with maternal death in developed countries as compared to developing countries where it is an important cause of maternal mortality.⁽²⁶⁾ This is mainly due to lack in adequate medical care facilities⁽³⁹⁾ and prompt access to cesarean and instrumental delivery especially for management of obstructed labor.^(2,42-44)

The only ways of preventing rupture of unscarred uterus are by creating awareness amongst general population about regular antenatal check-ups, hospital deliveries, use of contraception, reduction of unwanted and early pregnancies, especially in high parity women; accessibility of obstetric services including caesarean section for obstructed labor,⁽⁴⁵⁾ formulation of guidelines to ensure safe use of misoprostol and oxytocin for labor induction and augmentation. Also training of medical and paramedical staff at periphery for conducting safe deliveries and to identify grave signs and timely referral of patients to higher centres for better management should be enforced.

Conclusion

Hence, present series reveal that there is still a very high prevalence of rupture uterus, that too in unscarred uterus. Most of the risk factors associated with it are easily preventable by spreading health education and awareness about signs and symptoms of rupture uterus, high index of suspicion, counseling about regular antenatal check-ups, need and importance of institutional deliveries. All these measures in long run will help in reducing the overall maternal and fetal morbidity and mortality associated with uterine rupture.

Conflicts of Interest: There are no conflicts of interest.

Acknowledgment: We thank Dr. Namit Kant Singh for his kind advice and support.

References

1. Pinton A, Boudier E, Joal A, Sananes N, Severac F, Langer B, Youssef C. Risk Factors and Clinical

- Presentation of Uterine Rupture in the Unscarred Uterus: A Case Control Study. *J Preg Child Health* 2016;3:284. doi:10.4172/2376-127X.1000284.
2. Hofmeyr GJ, Say L, Gülmezoglu AM. WHO systematic review of maternal mortality and morbidity: the prevalence of uterine rupture. *BJOG* 2005;112(9):1221-8. Review. PubMed PMID: 16101600.
 3. Ofir K, Sheiner E, Levy A, Katz M, Mazor M. Uterine rupture: differences between a scarred and an unscarred uterus. *Am J Obstet Gynecol* 2004;191(2):425-9. PubMed PMID: 15343216.
 4. Ofir K, Sheiner E, Levy A, Katz M, Mazor M. Uterine rupture: risk factors and pregnancy outcome. *Am J Obstet Gynecol* 2003;189(4):1042-6. PubMed PMID:14586352.
 5. Rizwan N, Abbasi RM, Uddin SF. Uterine rupture, frequency of cases and fetomaternal outcome. *J Pak Med Assoc* 2011;61(4):322-4. PubMed PMID:21465963.
 6. Al-Zirqi I, Stray-Pedersen B, Forsén L, Daltveit AK, Vangen S. Uterine rupture: trends over 40 years. *BJOG* 2016;123(5):780-7. doi:10.1111/1471-0528.13394. Epub 2015 Apr 2. PubMed PMID: 25846698.
 7. Tower C. Obstetric emergencies. In: Baker PN, Kenny LC eds. *Obstetrics by Ten Teachers* 19th ed. London: Arnold. 2011:241-57. Available at: <https://www.crcpress.com/Obstetrics-by-Ten-Teachers-19th-Edition/Baker-Kenny/.../9...>
 8. Dow M, Wax JR, Pinette MG, Blackstone J, Cartin A. Third-trimester uterine rupture without previous cesarean: a case series and review of the literature. *Am J Perinatol* 2009;26(10):739-44. doi: 10.1055/s-0029-1223287. Epub 2009 May 18. Review. PubMed PMID: 19452430.
 9. Porreco RP, Clark SL, Belfort MA, Dildy GA, Meyers JA. The changing specter of uterine rupture. *Am J Obstet Gynecol* 2009; 200(3):269.e1-269.e4. DOI: <http://dx.doi.org/10.1016/j.ajog.2008.09.874>.
 10. Zwart JJ, Richters JM, Ory F, de Vries JI, Bloemenkamp KW, van Roosmalen J. Uterine rupture in The Netherlands: a nationwide population-based cohort study. *BJOG* 2009;116(8):1069-78; discussion 1078-80. doi:10.1111/j.1471-0528.2009.02136.x. PubMed PMID: 19515148.
 11. Walsh CA, Baxi LV. Rupture of the primigravid uterus: a review of the literature. *Obstet Gynecol Surv* 2007;62(5):327-34; quiz 353-4. Review. PubMed PMID: 17425811.
 12. Eze JN, Ibekwe PC. Uterine rupture at a secondary hospital in Afikpo, Southeast Nigeria. *Singapore Med J* 2010;51(6):506-11. PubMed PMID: 20658112.
 13. Gupta A, Nanda S. Uterine rupture in pregnancy: a five-year study. *Arch Gynecol Obstet* 2011;283(3):437-41. doi: 10.1007/s00404-010-1357-9. Epub 2010 Jan 28. PubMed PMID: 20107824.
 14. Bhaskar Rao K, Obstructed Labor. In Ratnam SS, Bhaskar Rao K, Arulkumaran S (eds). *Obstetrics and Gynecology for Postgraduates Vol 1*. 1st edn. Madras, Orient Longman. 1992:130-2.
 15. Kalewad PS, Bava A, Nandanwar YS. Pregnancy outcome in cases of rupture uterus: a clinical study. *Int J Reprod Contracept Obstet Gynecol* 2016;5(9):3098-3102. DOI: <http://dx.doi.org/10.18203/2320-1770.ijrcog20162993>
 16. Mishra N, Chandrahara E. Rupture of uterus. In: Warren R et al eds. *Best practice in labour and delivery*. 1st ed. New York Cambridge. 2009: 252-61.
 17. Gardeil F, Daly S, Turner MJ. Uterine rupture in pregnancy reviewed. *Eur J Obstet Gynecol Reprod Biol* 1994;56(2):107-10. PubMed PMID: 7805960.
 18. Pepin M, Schwarze U, Superti-Furga A, Byers PH. Clinical and genetic features of Ehlers-Danlos syndrome type IV, the vascular type. *N Engl J Med* 2000;342(10):673-80. Erratum in: *N Engl J Med* 2001 Feb 1;344(5):392. PubMed PMID:10706896.
 19. Walsh CA, O'Sullivan RJ, Foley ME. Unexplained prelabor uterine rupture in a term primigravida. *Obstet Gynecol* 2006;108(3 Pt 2):725-7. PubMed PMID:17018479.
 20. Sakr R, Berkane N, Barranger E, Dubernard G, Darai E, Uzan S.. Unscarred uterine rupture--case report and literature review. *Clin Exp Obstet Gynecol* 2007;34(3):190-2. PubMed: 17937100.
 21. Khabbaz AY, Usta IM, El-Hajj MI, Abu-Musa A, Seoud M, Nassar AH. Rupture of an unscarred uterus with misoprostol induction: case report and review of the literature. *J Matern Fetal Med* 2001;10(2):141-5. Review. PubMed PMID:11392596.
 22. Gessesew A, Melese MM. Ruptured uterus-eight year retrospective analysis of causes and management outcome in Adigrat Hospital, Tigray Region, Ethiopia. *Ethiop.J.Health Dev* 2002;16(3):241-245. <http://dx.doi.org/10.4314/ejhd.v16i3.9792>
 23. Omole-Ohonsi A, Attah R. Risk Factors for Ruptured Uterus in a Developing Country. *Gynecol Obstetric* 2011;1(1):102. doi: 10.4172/2161-0932.1000102.
 24. Turner MJ. Uterine rupture. *Best Pract Res Clin Obstet Gynaecol* 2002;16(1):69-79. Review. PubMed PMID: 11866498.
 25. Gibbins KJ, Weber T, Holmgren CM, Porter TF, Varner MW, Manuck TA. Maternal and fetal morbidity associated with uterine rupture of the unscarred uterus. *Am J Obstet Gynecol* 2015;213(3):382.e1-6. doi: 10.1016/j.ajog.2015.05.048. Epub 2015 May 28. PubMed PMID: 26026917.
 26. Malik HS. Frequency, predisposing factors and fetomaternal outcome in uterine rupture. *J Coll Physicians Surg Pak* 2006;16(7):472-5. PubMed PMID: 16827959.
 27. Chan YY, Jayaprakasan K, Tan A, Thornton JG, Coomarasamy A, Raine-Fenning NJ. Reproductive outcomes in women with congenital uterine anomalies: a systematic review. *Ultrasound Obstet Gynecol* 2011;38(4):371-82. doi: 10.1002/uog.10056. Review. PubMed PMID: 21830244.
 28. Hefny AF, Kunhivalappil FT, Nambiar R, Bashir MO. A rare case of first-trimester ruptured bicornuate uterus in a primigravida. *Int J Surg Case Rep*. 2015;14:98-100. doi:10.1016/j.ijscr.2015.07.019. PMID: PMC4573601.
 29. Singh N, Singh U, Verma ML. Ruptured bicornuate uterus mimicking ectopic pregnancy: A case report. *J Obstet Gynaecol Res* 2013;39(1):364-6. doi:10.1111/j.1447-0756.2012.01914.x. Epub 2012 Jun 13. PubMed PMID: 22691311.
 30. Nahum GG. Rudimentary uterine horn pregnancy. The 20th-century worldwide experience of 588 cases. *J Reprod Med* 2002;47(2):151-63. PubMed PMID:11883355.
 31. Chopra S, Keepanasseril A, Rohilla M, Bagga R, Kalra J, Jain V. Obstetric morbidity and the diagnostic dilemma in pregnancy in rudimentary horn: retrospective analysis. *Arch Gynecol Obstet* 2009;280(6):907-10. doi:10.1007/s00404-009-1013-4. Epub 2009 Mar 13. PubMed PMID: 19283398.
 32. Jayasinghe Y, Rane A, Stalewski H, Grover S. The presentation and early diagnosis of the rudimentary uterine horn. *Obstet Gynecol* 2005;105(6):1456-67. Review. PubMed PMID: 15932844.

34. Sharma C, Sharma M, Soni A, Soni PK, Gupta A, Verma S. Rupture of Uterus in Mid Trimester of Pregnancy: A Case Series & Review of Literature. *J Preg Child Health* 2015;2(3):163. doi:10.4172/2376-127X.1000163.
35. Jayaprakash S, Muralidhar L, Sampathkumar G, Sexsena R. Rupture of bicornuate uterus. *BMJ Case Rep* 2011 Oct 28;2011. pii: bcr0820114633. doi:10.1136/bcr.08.2011.4633. PubMed PMID: 22675095; PubMed Central PMCID:PMC3207777.
36. Tsafirir A, Rojansky N, Sela HY, Gomori JM, Nadjari M. Rudimentary horn pregnancy: first-trimester prerupture sonographic diagnosis and confirmation by magnetic resonance imaging. *J Ultrasound Med* 2005;24(2):219-23. PubMed PMID:15661954
37. Vernekar M, Rajib R. Unscarred Uterine Rupture: A Retrospective Analysis. *J Obstet Gynaecol India* 2016;66(Suppl 1):51-4. doi: 10.1007/s13224-015-0769-7. Epub 2015 Sep 8. PubMed PMID: 27651577; PubMed Central PMCID: PMC5016409.
38. Wagner M. Misoprostol (cytotec) for labour induction. A cautionary tale. *Midwifery today* 2003;67:31-3. Available at: <https://www.midwiferytoday.com/articles/cytotecwagner.asp>
39. Mazzone ME, Woolever J. Uterine rupture in a patient with an unscarred uterus: a case study. *WMJ* 2006;105(2):64-6. PubMed PMID: 16628979.
40. Smith GC, Pell JP, Pasupathy D, Dobbie R. Factors predisposing to perinatal death related to uterine rupture during attempted vaginal birth after caesarean section: retrospective cohort study. *BMJ* 2004;329(7462):375. Epub 2004 Jul 19. PubMed PMID: 15262772; PubMed Central PMCID: PMC509342.
41. Bujold E, Gauthier RJ. Neonatal morbidity associated with uterine rupture: what are the risk factors? *Am J Obstet Gynecol* 2002;186(2):311-4. PubMed PMID: 11854656.
42. Kwee A, Bots ML, Visser GH, Bruinse HW. Uterine rupture and its complications in the Netherlands: a prospective study. *Eur J Obstet Gynecol Reprod Biol* 2006;128(1-2):257-61. Epub 2006 Mar 10. PubMed PMID: 16530918.
43. Hofmeyr GJ. Obstructed labor: using better technologies to reduce mortality. *Int J Gynaecol Obstet* 2004;85 Suppl 1:S62-72. Review. PubMed PMID: 15147855.
44. Ekpo EE. Uterine rupture as seen in the University of Calabar Teaching Hospital, Nigeria: a five-year review. *J Obstet Gynaecol* 2000;20(2):154-6. PubMed PMID: 15512505.
45. Batra K, Gaikwad HS, Gutgutia I, Prateek S, Bajaj B. Determinants of rupture of the unscarred uterus and the related fetomaternal outcome: current scenario in a low-income country. *Trop Doct* 2016;46(2):69-73. doi:10.1177/0049475515598464. Epub 2015 Aug 13. PubMed PMID: 26275978.
46. Björklund K. Minimally invasive surgery for obstructed labour: a review of symphysiotomy during the twentieth century (including 5000 cases). *BJOG* 2002;109(3):236-48. Review. PubMed PMID: 11950177.