

## An unusual presentation of mammoth pseudo broad ligament leiomyoma with cystic degeneratons and hemorrhages: Case report

B Gowthami Krishna<sup>1\*</sup>, I Indira<sup>2</sup>

<sup>1</sup>Post Graduate Student, <sup>2</sup>Associate Professor, <sup>1,2</sup>Dept. of Obstetrics and Gynaecology, <sup>1,2</sup>Sri Venkateswara Medical College, Tirupati, Andhra Pradesh, India

**Corresponding Author: B. Gowthami Krishna**

Email: [gowthami.shiningstar@gmail.com](mailto:gowthami.shiningstar@gmail.com)

Received: 25<sup>th</sup> February, 2019

Accepted: 15<sup>th</sup> April, 2019

### Abstract

In reproductive age group extensive mass for abdomen may leads to lots of diagnostic difficulties among those ovarian tumors and uterine fibroids are most favourable diagnosis. Huge fibroids are known to arise from the uterus, although very rarely from extra-uterine sites. Among extra-uterine fibroids, broad ligament fibroids generally achieve enormous size and generally present with pressure symptom like bladder and bowel dysfunction. We report a case of false broad ligament fibroid. This case is reported for its rarity and the diagnostic difficulties in differentiating ovarian tumor and benign fibroid with cystic degeneration.

**Keywords:** Pseudo broad ligament fibroid, Cystic and hyaline changes.

### Introduction

Excluding pregnancy, leiomyoma (fibroids) are most common tumors of all pelvic tumors, being present in 20% women in the reproductive age group<sup>1</sup>. Leiomyoma, benign tumors of uterus, are most common indication for hysterectomy.<sup>2</sup> Site of origin for fibroids may be uterine or out of uterus i.e extra uterine sites like cervical and broad ligament etc. Incidence of extra uterine leiomyoma is 1%.<sup>3</sup> Even though overall incidence of broad ligament fibroids are rare, fibroid is most common solid tumor of broad ligament.

Characteristic symptoms of fibroids include menstrual disturbances and dysmenorrhea<sup>1</sup> Symptoms related to pressure caused by the mass like bladder and bowel dysfunction may present.<sup>4</sup> Due to its rarity it's very difficult to differentiate from other differential diagnosis like solid ovarian mass tumor, clinically. This is one of such cases where accurate origin of pathology was got confused clinically and ultrasonographically.

### Case Report

A 40 year old P2L2 women, came to our Gynecol opd with chief complaints of mass per abdomen since one year and got admitted for further management. That mass was insidious in onset and gradually progressive in nature with slow increase in size for last four months. Associated with lower abdomen pain which was dragging in nature. She didn't have H/O bladder and bowel disturbances, loss of weight, loss of appetite and fever. Menstrual history: regular cycles of 8 days/30, heavy flow with dysmenorrhea since one years with LMP 9/7/18. she underwent Tubectomy 18 years back, one week after her last child birth (postpartum sterilization).

### On Physical Examination

Patient was moderately built and nourished with BMI 21.2, she was pallor, no cyanosis, no clubbing, no icterus noted. she was afebrile, and haemodynamically stable.

### On Per Abdominal Examination

Uniform mass of 24 weeks size gravid uterus with well-defined upper border and smooth surface noted. No dilated/engorged veins and visible peristalsis noted. On palpation tumor is of variable consistency like firm at some areas and cystic in remaing, non-tender, and mobile horizontally and with regular margins. Lower pole of mass could not be reached.

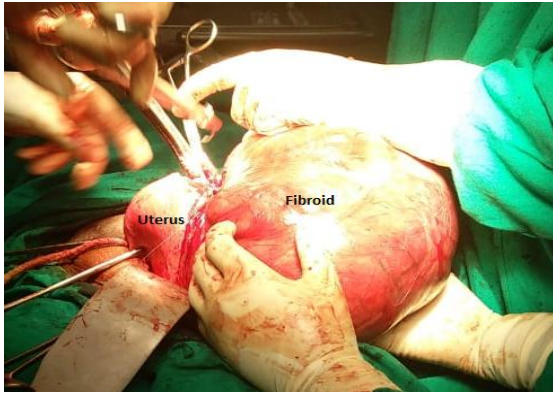
### On per Speculum Examination

Cervix was healthy. It was drawn up anteriorly, visualized with difficulty and it deflected to right. Vagina healthy.

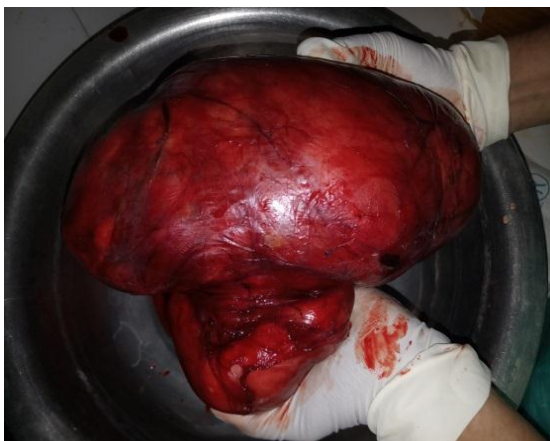### On per Vaginal Examination

Cervix was firm in consistency and deviated to right. Uterus could not made out separately. Cervical movements transmitting to mass and viceversa, left forniceal fullness present. After clinical evaluation provisional diagnosis was made out as large posterior wall fibroid with D/d as left ovarian mass.

Routine blood analysis was within normal limits. Except hb which was 7grm%. Anemia correction done preoperatively by blood trans fusions. USG abdomen pelvis done on 19/8/18 showed a mixed echogenic mass of 14x16cm size, with normal sized uterus. Ovaries not visualized. Final impression of usg scan is? ovarian mass/ uterine fibroid. CA 125 levels were found within normal.



**Fig. 1:** Intra Operative Demonstration of Uterus and Fibroid.



**Fig. 2:** Pseudo Broad ligament Fibroid specimen

#### Intra-operatively

On opening abdomen a 20x16 cms sized mass with variable consistency, completely occupying pelvis noted and thought to be ovarian mass. Later on exploration mass was arising from upper part of lateral wall of uterus extending into layers of broad ligament. Uterus found to be pushed to right and posteriorly with normal size. Bilaterally ovaries were normal. Left fallopian tube and round ligament stretched over the mass. As tumor was distorting pelvic anatomy, we proceeded with careful dissection to prevent ureteric injuries. By careful dissection of left broad ligament, fibroid first separated from uterus and then TAH with BSO done.

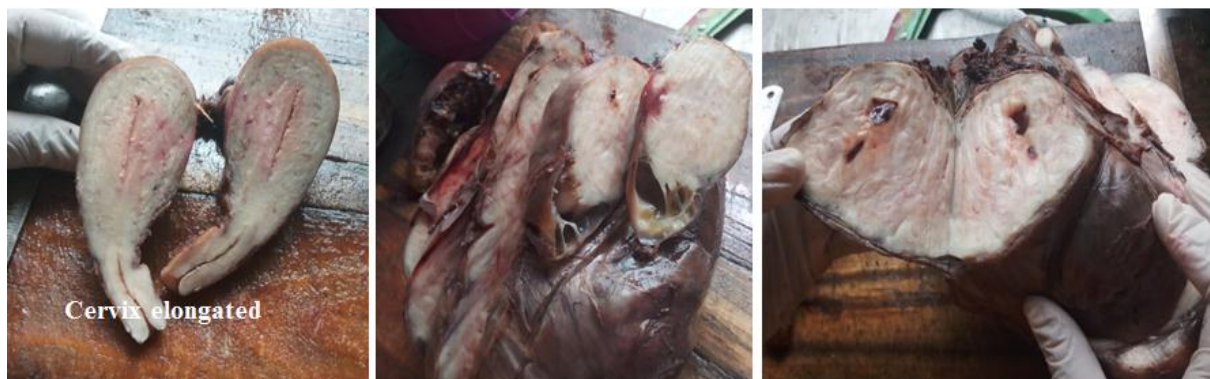Before closing abdomen with the help of urosurgeon we confirmed the integrity of ureter and bladder by cystoscopy and stent. On gross examination 20x16cm solid mass of variable consistency with bossolated surface noted. Cervix elongated. On cut section, small areas of cystic degeneration and hemorrhages noted. Uterine cavity found normal.

#### Histopathology Report

Confirmed leiomyoma of broad ligament origin. Microscopic examination of tumor that was found in the left broad ligament demonstrates parallel and resecting fascicles of smooth muscle cells with scattered thick walled blood vessels, and areas of marked hyalinization and cystic degeneration. No evidence of necrosis/ mitotic activity/atypia/malignancy.

#### Discussion

Broad ligament fibroids are of two types either a uterine tumor which grows into the broad ligament known as false broad ligament tumor but it preserve uterine attachments. Or a primary also known as true broad ligament leiomyoma arising from the sub peritoneal connective tissue of ligaments.<sup>1</sup> True broad ligament tumors lie lateral to ureter and uterine vessels. Whereas false tumor always lies medial to it.<sup>1</sup> In our case fibroid arise from lateral wall of uterus on left side and it occupied almost entire pelvis and altered uterus position so it is a false broad ligament fibroid. Based on location of the fibroid patient presents with varies symptoms. In our case patient presented with abdominal discomfort due to huge fibroid and menorrhagia. The differential diagnosis for broad ligament leiomyoma includes benign or malignant ovarian masses, broad ligament cyst, lymphadenopathy and tubo-ovarian masses.<sup>1</sup> In our case on clinical examination and ultrasonography it was suspicious of an ovarian mass or broad ligament leiomyoma. Further CA 125 levels came as normal. According to rajanna et al,<sup>5</sup> case report, broad ligament fibroid may associated with pseudo meigs syndrome with elevated CA 125 levels hence MRI plays vital role in differentiation of broad ligament fibroids from ovarian tumors. In general broad ligament fibroids are single with regular borders. In our case it is large bossolated mass.



**Fig 3:** Cut sections of Uterus and fibroid specimens showing cystic degenerations and hemorrhages

## Conclusion

As in this case broad ligament fibroid may present in unusual form and mimicking ovarian tumors CECT is preferred to reach accurate diagnosis. And during surgery to prevent ureteral injuries stenting must be done with the help of urologist.

**Conflict of Interest:** None.

## References

1. Kumar P, Malhotra N. Tumors of the corpus uteri. Jeffcoate's Principles of Gynaecology. 7th ed. New Delhi: Jaypee Brothers; 2008:492.
2. Stewart EA. Uterine Fibroids. *Lancet* 2001;357:293- 8.
3. Rajput DA, Gedam JK. Broad Ligament Fibroid: A Case Series. *IJSS Case Rep Rev* 2015;1(11):8-11.
4. Barek JS. Benign diseases of the female reproductive tract. Novack's Gynaecology. 15th ed. New Delhi: Lippincott Williams and Wilkins, *Wolters Kluwer* (India); 2007:470.
5. Rajanna DK, Pandey V, Janardhan S, Datti SN. Broad ligament fibroid mimicking as ovarian tumor on ultrasonography and computed tomography scan. *J Clin Imaging Sci* 2013;3:8.
6. Gowri V, Sudheendra R, Oumachigui A, Sankaran V. Giant broad ligament leiomyoma. *Int J Gynaecol Obstet* 1992;37(3):207-10.
7. Yuel VI, Kaur V. Broad Ligament Fibroid: An Unusual Presentation. *J K Sci* 2006;8:217-8.
8. Asotra S, Kaushik R, Gulati A. Broad ligament fibroid with neurilemoma like pattern. *J K Sci* 2009;11:215.

**How to cite this article:** Gowthami B, Indira I, An unusual presentation of mammoth pseudo broad ligament leiomyoma with cystic degenerations and hemorrhages: Case report. *Indian J Obstet Gynecol Res* 2019;6(2):222-224.