



## Original Research Article

# Autologous platelets rich plasma a potential therapeutic modality for cervical regeneration in erosions and cervicitis prospective observational study in a teaching hospital of central India

Sapna Jain<sup>1</sup>, Vivek Khare<sup>2,\*</sup>, Rashmi Tripathi<sup>1</sup>

<sup>1</sup>Dept. of Obstetrics and Gynaecology, LN Medical College, Bhopal, Madhya Pradesh, India

<sup>2</sup>Dept. of Pathology, LN Medical College, Bhopal, Madhya Pradesh, India

## ARTICLE INFO

## Article history:

Received 19–07-2019

Accepted 06-08-2019

Available online 12-09-2019

## Keywords:

Chronic cervicitis

Autologous PRP

Platelets poor plasma

Growth factors

Infertility

Cancer cervix

## ABSTRACT

**Introduction:** Biological reagent like PRP having strong anti-inflammatory and healing effect due to large number of growth factors and paracrine action thus plays a crucial role in cell protection, repairing and regeneration of epithelial tissues, curing deep seated inflammation thus protecting patient from long term consequences of chronic inflammation. Adult women worldwide are commonly affected by cervicitis, Symptoms of it can be similar to vaginitis with persistent vaginal discharge, itching, heaviness and dyspareunia. It can be caused by sexually transmitted infection as well as due to trauma, frequent douching and chemical irritants. This chronic inflammation of the cervix has a high recurrence rate due to its complex pathophysiology and leads to long term consequences like pelvic inflammatory disease, infertility, ectopic pregnancy, chronic pelvic pain, increased predisposition to HPV & HIV infection and even it can be a precursor of cervical cancer.

**Aim:** To compare post treatment symptom relief and healing of damaged cervix in patient undergoing either conventional or PRP therapy for chronic cervicitis and erosions.

**Materials and Methods:** This study was a single center, prospective observational study conducted at LN Medical college and research centre Bhopal M.P. A total of 120 patients with CC having similar symptoms were enrolled and out of which 60 randomly selected patients were given conventional treatment and remaining 60 were undergone PRP therapy. PRP was prepared from patients own blood in our institutional lab and injected immediately in the targeted areas of cervix at 3- 4 sites and result compared.

**Result:** Better Clinical benefits and healed epithelium were observed on follow up visits in the PRP treated patient as compared to conventional treatment in addition increased perception of recovery in patients within the prp group compared with the conventional group. No complications were reported in both therapy.

**Conclusion:** We have shown that PRP is a biological, safe effective and viable option for the cure of cervicitis as well as protecting patient from its significant consequences due to better regeneration and healing of cervical epithelium without any additional medication.

© 2019 Published by Innovative Publication.

## 1. Introduction

The body's first response to tissue injury is to deliver platelets to the injured area these platelets promote healing through growth factors and other cytokines release: the theory underlying this treatment modality was derived from natural healing processes as a utologous PRP is derived

from an individual's whole blood which was centrifuged to remove red blood cells. The remaining plasma has a 3-5 fold higher concentration of platelets than the whole blood. These activated platelets release growth factors (platelet-derived growth factor, transforming growth factor beta, fibroblast growth factor insulin-like growth factor 1 &2, vascular endothelial growth factor, epidermal growth factor) which have been found to promote natural healing responses and attract stem cells to the site of the injury which helps in

\* Corresponding author.

E-mail address: [drvivekhhare@gmail.com](mailto:drvivekhhare@gmail.com) (V. Khare).

regeneration of tissue. Moving from basic science to clinical practice, PRP injections have been applied to diseased ligaments, tendons, and joints, with superb outcomes in terms of repair [Rachita 8].

Chronic cervicitis is exceedingly common finding affecting adult women's physical and mental health due to its nagging symptoms, recurrence and consequences which predisposes women for HPV, HIV infection and cervical cancer which is the commonest cancer of female.<sup>1</sup> This problem affects women worldwide equally though the etiological factors may be different like non-infective factors - Allergy & irritation by chemical or physical means like IUCD, contraceptive diaphragm, condom, tampon, douches, wash, spermicidal child birth and D&C procedure.<sup>2</sup> Infective causes are - Sexually transmitted diseases like Chlamydia, Gonorrhoea, Trichomonas Vaginalis, viral infections like HSV & HPV. Malnutrition, poor immunity and hygiene, multiple partners, early age of sexual activity. It is clinically manifested as malodorous discharge per vaginum, dyspareunia, feeling of pain, pressure and heaviness in perineum, backache, post-coital bleeding, intermenstrual bleeding, burning and itching in vaginal area and general sense of weakness. Many times patient may not have any symptom or may have more than one symptoms.

Racemose glands and rugose mucus membrane of cervical canal once get infected becomes difficult to eradicate as pathogens enter into the depth of the glands and act as a focal abscess thus making Pathophysiology of cervicitis a complex phenomenon.

Pus and mucus act like chemical irritant leading to inflammation, erosions & ectropion formation. Imbalance in hormonal and bacterial milieu also interferes with the body's ability to maintain healthy cervical tissue. Diagnosis of CC is made by symptoms and direct visualization of cervix. Which shows erythematous, edematous, enlarged cervix with discharge, erosions & Nabothian cyst, old lacerations from child birth. Colposcopy – corroborate above findings, Lugol's iodine negative and no acetic acid uptake shows non-malignant nature of epithelium. Pap smear verifies inflammatory cellular infiltrate. Cervical biopsy confirms chronic inflammatory infiltrates and erosion. Colposcopy showing inflamed eroded cervix.

Treatment options vary from patient to patient and require none to repeated course of local and systemic antibiotics, probiotics, antiviral, antifungal & interventions like cryosurgery, chemical cauterization. Diathermy, laser to destroy abnormal cells, conisation, LEEP, even treatment of partner and eventually hysterectomy in some cases.

Significance of cervicitis is not only due to its troublesome symptoms and recurrence but its long-term serious consequences like PID, infertility, CPP, ectopic pregnancy, it increases predisposition to incidence of HIV, HPV & cervical cancer.<sup>2,3</sup> So the aim of the study was enhancing cervical health and healing by natural method.

## 2. Material and Methods

A prospective observational study, with due ethical consideration, written and informed consent was taken from each Patient after explaining the procedure in detail its beneficial outcome and side effects. After proper history, pelvic examination routine and specific investigations 120 multiparous married women of 25-40 yrs. Age group with diagnosed CC were studied during the period of 12 months from May 2018 till April 2019. Around 10 ml of whole blood was collected by venipuncture in a preloaded anticoagulant syringe and processed by density dependent separation in the laboratory at 1000 rpm at slow spin for 15 minutes RBCs are settled in the lower part with buffy coat & plasma containing platelets over it. Subsequently this supernatant was transferred into the other sterile plain tube for centrifugation at a higher speed [1500 rpm] for 5 minutes to obtain a platelets concentrate. Upper 2/3 is Platelets Poor Plasma zone and lower 1/3 is PRP with platelets pellets at the bottom of the tube. PPP removed and this platelets pellet with 3-4 ml of plasma was injected within 30 minutes under sterile conditions with 18 G needle precisely in the targeted area at 2-4 sites into intra and pericervical tissue in each assigned patients of CC. Two sittings were given at 3-4 wks interval. Patients were instructed for regular follow up first within 30 days then 3, 6 and 12 months interval. Follow up includes subjective assessment of symptoms, clinical examination, colposcopy and PAP smear if needed. It was a day care nonsurgical procedure. Another 60 patients were treated with conventional medical therapy.

### 2.1. Inclusion criteria

Married, multiparous women of 25 to 40 years, post-menstrually & no H/O medical illness.

### 2.2. Exclusion criteria

Platelets dysfunction, Unmarried, prolapse uteri, major medical illness & post-menopausal, precancerous state.

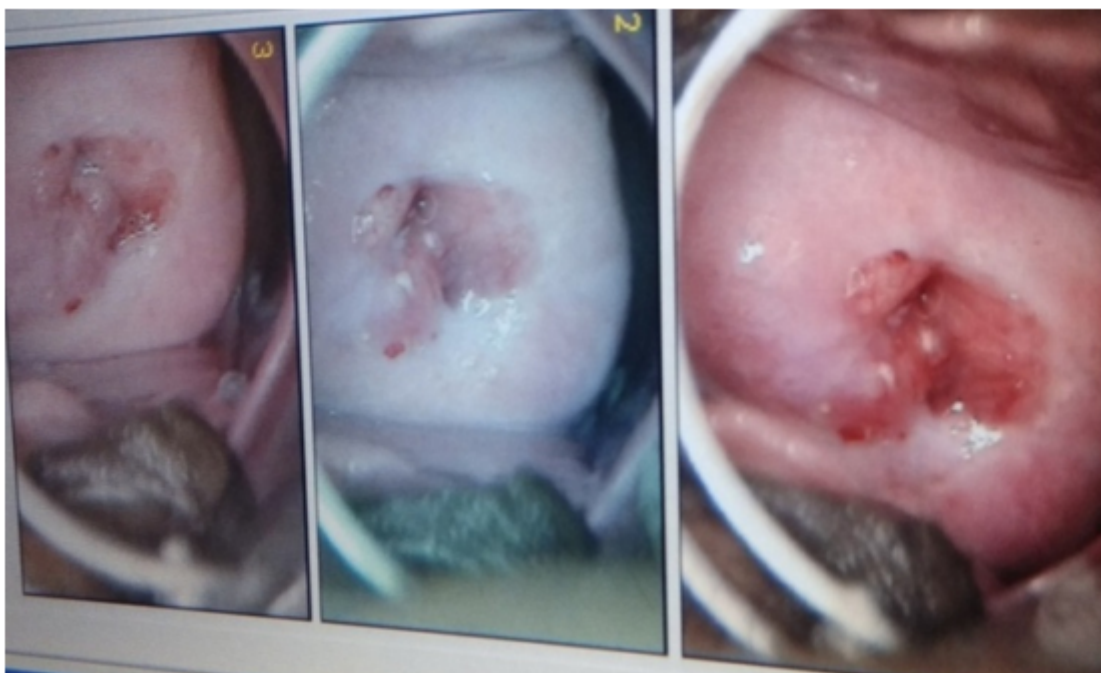### 2.3. Statistical analysis

The data was managed by Microsoft Excel and presented through MS Word. Chi-square test was applied as test of significance considering null hypothesis value of 15% for all variables under study. p value of < 0.05 was taken as level of significance.


## 3. Result

In this study we found that patient treated with PRP showed good relief in symptoms and no recurrence. Our analysis showed following results. Table 1 mean age of patient suffering from CC was 32-34 years in both the groups.

Table 2 showed symptoms of patients treated with conventional therapy 95% patients were having itching in



**Fig. 1:**



**Fig. 2:** 3 ml of concentrated PRP after fast spin  
PRP separated after 1<sup>st</sup> round of low speed centrifugation

**Table 1:** Distribution of patients as per the age

	N	Mean age in years	Std. Deviation	Std. Error Mean	T test	P Value
Conventional treatment group	60	34.00	5.13545	.66298	1.61	0.11
PRP Group	60	32.30	6.36543	.82177		

perineal region, 91.67% patients had white discharge, and dyspareunia as second commonest symptom 73.33% had inter menstrual bleeding 71.67 % patient was suffering from pelvic pain, 68.33% had heaviness in perineum. Only 51.67% patient had post coital bleeding. Itching, discharge PV and dyspareunia were the common symptoms in our observation.

Table 3 in PRP group patient also have almost similar symptom profile with 96.67 % patient having dyspareunia followed by itching in 91.67%, white discharged was observed in 90.0% patients.75% having pelvic pain, 70% having inter menstrual bleeding 63.33% postcoital bleeding, heaviness in perineum in 58.33% patient.

Table 4 On follow up visit clinical benefits were seen, and at 6 months of therapy 76.6% patient were cured completely with PRP as compared to 48.33% in conventional group. In PRP group none of the patient came with recurrence of infection after one year. Significant improvement in vaginal discharge was observed in both the group. All patients were cured for post coital bleeding in PRP group as compared to 50% in CT group. For dyspareunia 90% patients showed improvement with no recurrence of it in PRP group after 1 year of follow up. In pelvic pressure pain and heaviness 8 0% patient showed complete improvement and 2 0% patients had mild improvement in PRP group. All patients improved in their itching and burning. In intermenstrual bleeding 8 6% pt. got complete improvement and 14% patients had moderate relief which improved over the period. Patient who had severely eroded cervix, post PRP results were promising with completely healed cervical epithelium. In conventional group repeated dose of medication was required for better relief. Pap smear was taken at 6 & 12 months interval along with colposcopy showed normal cervical cells. Our results we re similar to Xiolins study which showed better cure with PRP in cervical ectopy.<sup>4,5</sup> When comparing the treatment outcome in both the group we found better cure rate among PRP group [76.67%] as compared to 48.33% in CT group. High cure percentage in PRP group is found to be statistically significant [p = 0.001] as shown in the Table 4 Chi Square value of 10.3, with degree of freedom was one.

No immediate or long term adverse effects were observed though Xiaolin Hua observed in his study some short term immunological reaction like chills, mild fever and headache lasting for few days in 2 patients.

#### 4. Discussion

Management of cervicitis is an unresolved problem and remains one of the commonest cause of morbidity and poor quality of life in women. Local injection of autologous PRP as a noble method with the potential for wound healing, tissue regeneration and prevention of infection<sup>1-3</sup> in chronic cervicitis. Cervicitis is the commonly encountered disease in adult women world over with significant economical burden

as disease is difficult to cure with high recurrence rate due to repeated exposure to aetiology, high risk sexual behaviour, weak immune system, and under treatment.\$

So these disturbing symptoms & long term serious consequences especially predisposition to viral infections and cervical cancer lead to this concept study.

The study finding revealed that most of the patient had one or more symptoms. Symptoms found in this study were itching in perineal region (95 %), irritant, malodorous discharge per vaginum (91%), dyspareunia (96.67%), post coital bleeding (63%) hampering marital health, giving general sense of ill health and poor hygiene. Inter menstrual bleeding (73.33%), Heaviness in perineal region (68%) and Pelvic pain (75 %).

A substantial body of evidence supports that chronic inflammation can pre dispose an individual to cancer. The longer the inflammation persists, the higher the risk of associated carcinogenesis.[4Keibel] Most of the cervical carcinomas are associated with human papilloma-virus (HPV), as rate of HPV & HIV infection in chronic cervicitis cases is much higher as observed by Ealhe<sup>6</sup> increasing broad-spectrum antibiotic usage with associated emergence of antimicrobial resistance reinforces the need for targeted therapies. As our understanding of the aetiology and significance of cervicitis, PRP work as target therapy without needing other medications. So this a lternative modality of treating cervicitis with PRP plays a crucial role in cell protection, rege neration of epithelial tissues, repairing of fibrosed tissue, curing deep seated infection & inflammation by a very natural healing process<sup>7,8</sup> thus improving genital health, hygiene, immunity and general well being. Comparing the results of the present with that of the related studies the findings are more or less consistent in nature. Gao also found that PRP plays a crucial role in regeneration of inflamed, fibrosed epithelial tissue of cervix.<sup>4</sup> We have observed that PRP is a biologically safe, effective and economically viable option to cure the disease and its consequence, Hence A standardized approach to cervicitis research, particularly with consensus of PRP, may facilitate outcomes that can be more generally applied in clinical practice.

#### 5. Conclusion

Autologous PRP therapy can emerge as a potential treatment strategy for chronic cervicitis, with promising result for inflamed and damaged cervical tissue with healing of erosions & better cervical health. PRP is easy to obtain, do not have any immunogenic complication and ethical issues as autologous. This treatment can reverse as well as stop further damage caused to cervix hence prevention from Cervical cancer is expected.<sup>5,9,10</sup> Further clinical studies in this technique is needed to confirm the efficacy and long term results of PRP in CC in a large study population. Which would help to strengthen our observations and enable

**Table 2:** Distribution of patients as per clinical findings who received conventional treatment

S No.	Clinical Finding	Present	%	Absent	%	Total	%
1	White discharge	55	91.67	5	8.33	60	100
2	Itching	57	95.00	3	5.00	60	100
3	Inter menstrual Bleeding	44	73.33	16	26.67	60	100
4	Heaviness	41	68.33	19	31.67	60	100
5	Dyspareunia	55	91.67	5	8.33	60	100
6	Post coital bleeding	31	51.67	29	48.33	60	100
7	Pelvic Pain	43	71.67	17	28.33	60	100

**Table 3:** Distribution of patients as per clinical findings who received PRP treatment

S. No.	Clinical Finding	Present	%	Absent	%	Total	%
1	White discharge	54	90.00	6	10.00	60	100
2	Itching	55	91.67	5	8.33	60	100
3	Inter menstrual Bleeding	42	70.00	18	30.00	60	100
4	Heaviness	35	58.33	25	41.67	60	100
5	Dyspariunia	58	96.67	2	3.33	60	100
6	Post coital bleeding	38	63.33	22	36.67	60	100
7	Pelvic Pain	45	75.00	15	25.00	60	100

**Table 4:** Distribution of patients as per treatment outcome

Treatment given	Treatment outcome				Total	%	P Value
	Cured	%	Not cured	%			
Conventional Treatment	29	48.33	31	51.67	60	100	0.001
PRP Treatment	46	76.67	14	23.33	60	100	

Chi-Square value = 10.3, degree of freedom = 1

practitioners to use this modality clinically to optimize their success rates.

Future of PRP in Ob/GYNE - Prevention of cancer cervix, stress urinary incontinence, SUI, infertility management by regeneration of o vary, endometrial regeneration in Ashermans syndrome, fistula repair.<sup>10</sup>

## 6. Funding

None

## 7. Conflict of interest

None declared

## 8. Ethical approval

We followed the principles expressed in the Declaration of Helsinki, after receiving the approval of the Institutional Ethic Committee.

## References

- Marrazzo JM, H D, Martin. Management of Women with Cervicitis. *Clin Infect Dis*. 2007;44(3):S102–S110. Supplement 3 : S102-S110. Available from: [10.1086/51142301](https://doi.org/10.1086/51142301) April.
- Workowski KA, Berman SM. Centers for Disease Control Prevention) Sexually transmitted diseases treatment guidelines. *MMWR Recomm Rep*. 2010;59(12):1–110.
- Gupta V. Colposcopic evaluation of cervical lesion: A prospective study. *Int J Clin Trials*. 2014;1(3):110–113. Available from: [10.5455/](https://doi.org/10.5455/2349-3259.ijct2014/105)

- [2349-3259.ijct2014/105](https://doi.org/10.1038/nrrheum.2013.141).
- Gao J, Yanling Z, Zhang B, Liu G, Youzhan X, Kang H. Study on treating symptomatic cervical ectopy with platelet-rich plasma. *Chin J Exp Clin Infect Dis*. 2014;.
- Hua X, Zeng Y, Zhang R, Wong H, Diao J, Zhang P. Using platelet-rich plasma for the treatment of symptomatic cervical ectopy. *Int J Gynecol Obstet*. 2012;119(1):26–35. Pub Med. Available from: [10.1016/j.ijgo.2012.05.029](https://doi.org/10.1016/j.ijgo.2012.05.029) Epub.
- Mirzaie-Kashani M, Bouzari M, Talebi A, Arbabzadeh-Zavareh F. Detection of Human Papillomavirus in Chronic Cervicitis, Cervical Adenocarcinoma, Intraepithelial Neoplasia and Squamous Cell Carcinoma. *Jundishapur J Microbiol*. 2014;7(5):e9930.
- Foster TE, Puskas BL, Mandelbaum BR, Gerhardt MB, Rodeo SA. Platelet-rich plasma: from basic science to clinical applications. *Am J Sports Med*. 2009;37(11):2259–2272. Available from: [10.1177/0363546509349921](https://doi.org/10.1177/0363546509349921).
- Andia I, Nicola M. Platelet-rich plasma for managing pain and inflammation in osteoarthritis. *Nat Rev Rheumatol*. 2013;9:721–730. Published online 01. Available from: [10.1038/nrrheum.2013.141](https://doi.org/10.1038/nrrheum.2013.141).
- Tehrani A, Esfehiani-Mehr B, Pirjani R, Rezaei N, S SH. Application of Autologous Platelet-Rich Plasma (PRP) on Wound Healing After Caesarean Section in High-Risk Patients. *Iran Red Crescent Med J*. 2016;18(7):e34449. Available from: [10.5812/ircmj.344494](https://doi.org/10.5812/ircmj.344494).
- Dawood AS, Salem HA. Current clinical applications of platelet-rich plasma in various gynecological disorders: An appraisal of theory and practice. *Clin Exp Reprod Med*. 2018;45(2):67–74. Available from: [10.5653/ceerm.2018.45.2.67](https://doi.org/10.5653/ceerm.2018.45.2.67) PMID: PMC6030616 PMID.

## Author biography

Sapna Jain Professor

**Vivek Khare** Associate Professor

**Rashmi Tripathi** Assistant Professor

**Cite this article:** Jain S, Khare V, Tripathi R. Autologous platelets rich plasma a potential therapeutic modality for cervical regeneration in erosions and cervicitis prospective observational study in a teaching hospital of central India. *Indian J Obstet Gynecol Res* 2019;6(3):382-387.