

# Could Simple Procedures Minimize Hysterectomy in Management of Placenta Accreta?

Shehata A<sup>1,\*</sup>, Hussein N<sup>2</sup>, El-Halwagy A<sup>3</sup>, El Gergawy A<sup>4</sup>

<sup>1,2,3,4</sup>Lecturers, Department of Obstetrics and Gynecology, Tanta University, Tanta, Egypt

**\*Corresponding Author:**

E-mail: ayman.dawood@med.tanta.edu.eg

## ABSTRACT

**Introduction:** *The incidence of placenta accreta (PA) is rising as a consequence of increased number of cesarean sections and advancing maternal age, both being independent risk factors. Severe postpartum hemorrhage (PPH) is a leading direct cause of maternal morbidity and mortality. Major surgical interventions like Hysterectomy, ligation of major pelvic vessels and massive blood transfusions are required to save the maternal life.*

**Patients Methods:** *Fifteen cases of PA were included in the period from August 2014 to may 2015 in Obstetrics and Gynecology Department diagnosed by US and MRI. Preoperative evaluation and Laboratory investigations were done and Cross matched blood were done. Three step simple procedure was applied to all these 15 cases and we assessed its success in minimizing hysterectomy and ligation of major vessels. The procedure include first step: double ligation of uterine artery on both sides before and after placental removal, second step suturing the placental bed and third step is insertion of triple way catheter through the cervix and inflation to 50 cc saline to compress and drain bleeding.*

**Results:** *The 3 step procedure was successful in minimizing major surgical interventions in all patients because neither patients required hysterectomy nor need Vascular interventions at all. There were no need for massive blood transfusions maximum of 3 -4 units of blood and the need of FFP was limited to 4 cases (26.6%) Complications were present in 6 cases (40%) and were: 2 cases (13.3%) of Bladder injury and 2 cases (13.3%) of pyrexia, 1 case (6.66%) of pyometria and 1 case (6.66%) of wound disruption.*

**Conclusions:** *Three step procedure is a simple procedure and successful in minimizing major surgical interventions in PA management.*

**Keywords:** *Placenta, accreta, management*

## INTRODUCTION

Placenta accreta means is described when there is firm adherence of placenta to myometrium because of partial or total absence of the decidua basalis and imperfect development of the fibrinoid or Nitabuch layer. Many risk factors were described such as placenta previa, prior Cesarean section and other uterine operations.<sup>(1)</sup>

The clinical consequence of Placenta Accreta is massive hemorrhage at the time of placental

separation which lead to maternal morbidities (Disseminated intravascular coagulopathy, Adult respiratory distress syndrome and Renal failure) and even maternal mortality.<sup>(2)</sup>

Management options described were hysterectomy, leaving placenta insitu with methotrexate therapy and placental resection with embolization of uterine arteries or internal iliac ligation.<sup>(3)</sup>

Currently there is insufficient evidence to support a firm advice to use of balloon catheter oc-

clusion or embolization for minimizing blood loss and improving surgical outcome and available data are conflicting as regard to its efficacy<sup>(4)</sup> and even some investigators reported significant complications.<sup>(5)</sup>

Conservative management, with leaving the placenta in situ for spontaneous resorption, was associated with severe long-term complications such as hemorrhage and infections, including a 58% risk of hysterectomy later on after delivery.<sup>(3)</sup>

Hysterectomy after delivery had been reported to lower mortality and morbidity rates compared to conservative management became, and still is the recommended treatment option.<sup>(6,7)</sup>

As the patients with placenta accreta become more and more younger due to increasing rates of Cesarean Section delivery, this study was conducted to keep patient's desire for future fertility and we tried simple procedure as a uterine-sparing approach to both reduce the morbidity of peripartum hysterectomy as well as to allow for future fertility .

## PATIENTS AND METHODS

In this prospective study, fifteen cases of placenta accreta prenatally diagnosed with color doppler and MRI at Tanta University hospitals Antenatal Care Unit in the period from August 2014 to May 2015. Surgical details, possible complications, need of ICU, need of Hysterectomy were explained to patients, and written consent was taken.

Age, Parity, Gestational age at delivery, preoperative investigations, Operative time, Intraoperative complications, Need for hysterectomy, Postoperative investigations ,Postoperative complications and Hospital stay duration were gathered and statistically analyzed. Cross matched blood and Fresh Frozen Plasma were prepared. A Urologist and Vascular surgeon were informed to be standby for any surgical necessity.

## Surgical technique

- General anesthesia was used in all cases.
- Bladder dissection and good exposure of the lower uterine segment was the corner stone step in all cases.
- Incise the uterus above the placenta to extract the baby.
- Apply ***the first step*** by uterine artery ligation at the isthmus and at level of uterine incision taking large transverse portion from the lower segment to close both uterine arteries and new vessels before removal of the placenta
- Try to remove the placenta carefully without excessive tissue damage.
- After removal of placenta don't Panic from bleeding as long as the patient is hemodynamic stable.
- ***Second step:*** Apply compression sutures and sew the placental bed.
- ***Third step:*** Close the uterine incision on a triple way catheter for inflated by 50cc saline to apply tamponade effect on placental bed.
- Misoprostol (1000mg)rectal application

Recordings of intraoperative and postoperative complications, number of required blood transfusion products are mandatory.

## RESULTS

In this study 15 placenta accreta patients were enrolled, All were diagnosed prenatally with doppler and MRI. The mean age of patients was (31±4.03). Parity mean was (3.27±0.88). The mean gestational age at delivery was (35.53±1.12). The operative time was (77.33±13.87).Blood transfusion units were required in all cases with mean (3.06.088). Two cases only required fresh frozen plasma. (Table 1).

**Table 1: Results of the study**

	Range	Mean $\pm$ SD
Age	25-39	31.07 $\pm$ 4.03
Parity	2-5	3.27 $\pm$ 0.88
Gestational Age	34-37	35.53 $\pm$ 1.12
Operative time	60-100	77.33 $\pm$ 13.87
Blood transfusion units	2 -4	3.06 $\pm$ 0.88
Hospital stay	2-15	4.53 $\pm$ 4.47
ICU admission	0	0
Readmission	2 (13.6%)	2 cases (pyometra, wound disruption)
Reoperation	1 (6.66%)	Secondary suture

Hemoglobin level before operation ( $10.14 \pm 0.67$ ) was significantly dropped after the procedure ( $8.39 \pm 1.05$ ). (Table 2)

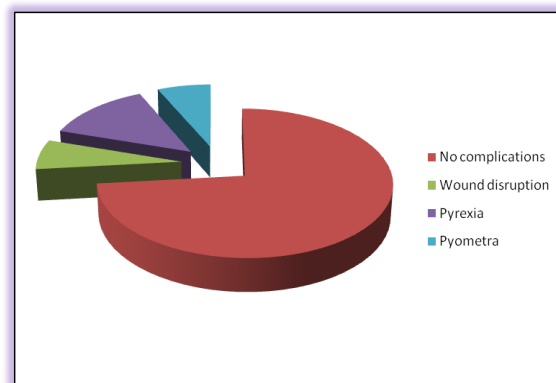
As regard the intraoperative complications were present in two cases (13.3%) and were Urinary Bladder injury and were repaired with Foley catheter placed for 5 days post-operative. (Table 3) The length of hospital stay was ( $4.53 \pm 4.47$ ). There were no need for ICU admission in any case. (Table 4) The post-operative complications were present in 4 cases: one case of pyometra (6.7%), one case of wound disruption (6.7%) two cases of pyrexia (13.3%). (Figure 1)

**Table 2: Hemoglobin before and after Procedure**

	Hemoglobin		Paired t-test	
	Range	Mean $\pm$ SD	t	P-value
Before procedure	8.8-11.2	10.14 $\pm$ 0.67	7.6	<0.001
After procedure	6.6-10	8.39 $\pm$ 1.05		

The cases were managed outpatient for pyrexia and with readmission for the two cases of

pyometra and wound disruption. Pyometra is managed by triple way catheter and irrigation of uterine cavity with saline and parenteral antibiotics. Reoperation is done for one case of the wound disruption with secondary suture.

**Figure 1: Intra-operative complications**

## DISCUSSION

In this study the 15 cases were all placenta accreta, in 13 cases the placenta was located anteriorly and in 2 cases placenta was located posteriorly. In this study we tried simple procedures to evaluate their role in minimizing major surgical intervention especially hysterectomy with its co morbidities. We tried these simple procedures to preserve the uterus as most patients were young (31 years) and minimize psychological trauma of hysterectomy and loss of fertility.

Many approaches for the management of placenta accreta have been described to both reduce the morbidity of peripartum hysterectomy as well as allow for future fertility.<sup>(8,9)</sup> Varying success rates were described for different approaches including uterine artery embolization, methotrexate therapy, hemostatic sutures, pelvic devascularization, and balloon tamponade.<sup>(10)</sup>

When we compare the results of this study to previous studied conducted to assess the outcome of uterine sparing techniques we found that simple procedures of this study had less operative time (77.33) than the procedure of Warshak et al 2010 who reported a  $194 \pm 1.6$  as a mean operative time<sup>(11)</sup> and that of Walker et al 2013 which was 107 minutes<sup>(12)</sup>.

The length of hospital stay in this study was (4.53±4.47) which is less than the results of Warshak et al (7.4±1.8)<sup>(11)</sup>, and similar to Eller et al (4 days)<sup>(13)</sup> and Walker (5 days)<sup>(12)</sup>.

In this study bladder injury occurred in 13.3% which is much lower than that of Warshak et al who reported bladder injury in 23%<sup>(11)</sup>, Walker et al who reported bladder injury in 30%<sup>(12)</sup> and Eller et al who reported bladder injury in 37%.<sup>(13)</sup>

In France, a large study was conducted on 167 patients with placenta accreta, the success rate of that study in preserving uteri was 78%, and the rate of maternal morbidity was 6%.<sup>(6)</sup> In that study, 11% needed hysterectomy early after delivery and 11% required hysterectomy in the next 3 months of delivery due to severe complications (sepsis, vesicouterine fistula, and/or uterine necrosis).<sup>(9,14)</sup>

In China investigators conducted an observational study at Beijing Chaoyang Hospital, Beijing, China, among patients with placenta previa and placenta accreta and they tried a uterine sparing approach on 7 cases and they reported less hemostatic time 4.6 minutes (range 3.0-7.0)<sup>(15)</sup>

Postoperative complications reported in this study was reported in 4 cases: 2 cases with prexia, a case of pyometra and a case of wound disruption and these complications are less than reported by other investigators who reported severe postpartum hemorrhage, postoperative disseminated intravascular coagulopathy, and infection resistant to antimicrobial therapy that may require laparotomy and hysterectomy.<sup>(16)</sup>

In this study no cases require ICU admission and no postpartum hemorrhage so our simple procedures were effective in conservative treatment of placenta accreta, and reducing hysterectomy for these patients. Therefore, this new conservative treatment approach should be tried for women who have strong desire for preserving their future fertility.

## CONCLUSION

Placenta accreta patients getting more and more younger and this nescicate development of new

approaches to preserve fertility and minimize hysterectomy. In this study, we have presented a simple approach as a conservative treatment for placenta accreta cases. Our surgical procedure is effective and useful in the conservative management of patients with placenta accreta, and it can be used as an alternative conservative treatment protocol if it can be supported by larger randomized controlled trials.

## ACKNOWLEDGEMENT

We are thankful greatly to our assistants and residents who helped us to complete this work. We also thankful to statistics collector and analyzers.

## REFERENCES:

1. Benirschke K, Burton, Baergen RN: Pathology of the Human Placenta, 6th ed. New York, Springer, 2012, p 204.
2. Awan N, Bennett MJ, Walters WA: Emergency peripartum hysterectomy: a 10-year review at the Royal Hospital for Women, Sydney. Aust N Z J Obstet Gynaecol 51(3):210, 2011
3. Clausen CI, Lönn L, Langhoff-Roos J. Management of placenta percreta: a review of published cases. Acta Obstet Gynecol Scand. 2014 Feb;93(2):138-43.
4. Butt K, Gagnon A, Delisle MF. Failure of methotrexate and internal iliac balloon catheterization to manage placenta percreta. Obstet Gynecol 2002;99:981-2.
5. Bishop S, Butler K, Monaghan S, Chan K, Murphy G, Edozien L. Multiple complications following the use of prophylactic internal iliac artery balloon catheterisation in a patient with placenta percreta. Int J Obstet Anesth 2011;20:70-3.
6. American College of Obstetricians and Gynecologists: Placenta accreta. Committee Opinion No. 529, July 2012b.
7. Garmi G, Salim R. Epidemiology, etiology, diagnosis, and management of placenta accreta. Obstet Gynecol Int 2012; 2012: Article ID 873929.
8. Alanis M, Hurst BS, Marshburn PB, et al. Conservative management of placenta in creta with selective arterial embolization preserves future fertility and results in a favorable outcome in subsequent pregnancies. Fertil Steril

- 2006; 86:1514.e3–1514.e7. discussion
9. Perez-Delboy A, Wright JD. Surgical management of placenta accreta: to leave or remove the placenta? *BJOG* 2014; 121:163–169.
  10. Doumouchtsis SK, Papageorghiou AT, Arulkumaran S. Systematic review of conservative management of post-partum hemorrhage: what to do when medical treatment fails. *Obstet Gynecol Surv* 2007; 62:540–547.
  11. Warshak CR, Ramos GA, Eskander R, et al. Effect of predelivery diagnosis in 99 consecutive cases of placenta accrete. *Obstet Gynecol* 2010; 115:65–69.
  12. Walker MG, Allent L, Windrim RC, et al: Multidisciplinary management of invasive placenta previa. *J Obstet Gynaecol Can* 35(5):417, 2013.
  13. Eller AG, Bennett MA, Sharshiner M, et al: Maternal morbidity in cases of placenta accreta managed by a multidisciplinary care team compared with standard obstetric care. *Obstet Gynecol* 117(2 Pt 1):331, 2011.
  14. Sentilhes L, Ambroselli C, Kayem G, et al. Maternal outcome after conservative treatment of placenta accreta. *Obstet Gynecol* 2010; 115:526–534.
  15. Zhu L, Zhang Z, Wang H, Zhao J, He X, Lu J. A modified suture technique for hemorrhage during cesarean delivery complicated by complete placenta previa. *Int J Gynaecol Obstet.* 2015 Apr;129(1):26-9.
  16. Paull JD, Smith J, Williams L, et al. Balloon occlusion of the abdominal aorta during caesarean hysterectomy for placenta percreta. *Anaesth Intensive Care* 1995; 23:731–734.