



## Original Research Article

# Study of injection placentrex on ovarian cyst

Kalpana Khandheria<sup>1</sup>, Manish Pandya<sup>1,\*</sup>

<sup>1</sup>Dept. of Obstetrics & Gynecology, Scientific Research Institute, Surendranagar, Gujarat, India



### ARTICLE INFO

#### Article history:

Received 23-10-2019

Accepted 05-11-2019

Available online 06-12-2019

### ABSTRACT

Ovarian cysts are sacs containing fluid or semisolid material that develop in or on the surface of an ovary.<sup>1</sup> Ovarian cysts can develop at any time in a female's life from infancy to puberty to menopause, including during pregnancy

**Method:** Inj. Placentrex 1Amp I/M were given to the patient alternate day for 10 days along with Tab Nimesulide 100mg + Serratiopeptidase 10mg twice a day after meal.

**Results:** 95% patients were cured after the 1<sup>st</sup> course. (Another 5% patients were given another medicine)

**Conclusion:** Inj.placentrex is very effective in treatment of functional ovarian cyst.

© 2019 Published by Innovative Publication. This is an open access article under the CC BY-NC-ND license (<https://creativecommons.org/licenses/by/4.0/>)

## 1. Introduction

1. Ovarian cysts are sacs containing fluid or semisolid material that develop in or on the surface of an ovary.
2. Ovarian cysts are common and the vast majority are harmless.
3. Ovarian cysts should always be checked out as they cause symptoms similar to cancerous ovarian tumors.
4. Ovarian cysts can develop at any time in a female's life from infancy to puberty to menopause, including during pregnancy.

*1.1. Fortunately, most ovarian cysts do not require surgical removal and are not malignant*

There are two types of ovarian cyst

1. Non- Neoplastic ovarian cysts
2. Neoplastic ovarian cysts

*1.2. Neoplastic ovarian cysts*

According to FIGO classification of neoplastic ovarian cysts

\* Corresponding author.

E-mail addresses: [pushpam.jam@gmail.com](mailto:pushpam.jam@gmail.com) (K. Khandheria), [drmanish.pandya@gmail.com](mailto:drmanish.pandya@gmail.com) (M. Pandya).

Germinal epithelial tumors are (A) Serous, (B) Mucinous, (C) Endometrioid, (D) Clear Cell, (E) Undifferentiated.

In serous cyst there are 2 types (a) Serous cystadenomas (b) Simple serous cystomas

*1.3. Serous cystadenomas*

1. 20 to 40% of benign ovarian neoplasms. - Named from the serous fluid they contain.
2. Unilocular/multilocular.
3. Papillary excrescences are common on the interior of the cyst wall

*1.4. Simple serous cystomas*

This cyst is unilocular, filled with thin and clear fluid.

Occurance of the germinal epithelial tumors, is around 75%.

1. Occurrence of the germ cell tumors is 15%.
2. Occurrence of the gonadal stromal tumors is 5%.
3. Occurrence of the miscellaneou is 5%.

The non-neoplastic ovarian cysts are of Frequent occurrence and its types are 1) Follicular cysts, 2) Corpus Luteum Cyst, 3) Theca – lutein cysts , 5) Luteoma of pregnancy.

### 1.5. Follicular cyst

Follicular cysts occur frequently during the years when a woman is menstruating, and are nonexistent in postmenopausal women or any woman who is not ovulating.

This cyst is vary in size from 1 to 5 or 6 cm. This cyst is product of follicle stimulation and excessive intrafollicular fluid formation. Follicular cyst is Thin – walled and smooth consistency. Removal of the cystic ovary is rarely indicated. Needling these small cysts is practiced by some gynecologists.

#### 1.5.1. Corpus luteum cyst

Corpus luteum cysts<sup>2,3</sup> occur occasionally during the menstrual years and during early pregnancy. (Dermoid cysts, which may contain hair, teeth, or skin derived from the outer layer of cells of an embryo, are also occasionally found in the ovary.)

Lutein cells persist in a variable state of preservation. In this cyst wall of fibroblasts is deposited on inner surface of the lutein zone. In older cysts - lutein cells almost completely disappear and fibrous zone is heavy. In recent cysts - a zone of healthy – looking lutein cells with only a little fibrous tissue within.

Distinction between the normally functioning corpus luteum and the cystic corpus luteum

Normally functioning corpus luteum - excessive straw-colored or blood – tinged fluid. Function undisturbed. diameter not over 3cm

### 1.6. The corpus luteum cyst

Size of the corpus luteum cyst is 5 to 6 cm. And in rare instances, an even greater diameter. Occasionally surgery is required because of excessive bleeding, acute appendicitis or tubal pregnancy. C. L. Cyst is commonly associated with a disturbance of or delay in menstruation, but variation is not uniform.

### 1.7. Theca–lutein cysts

Theca-lutein cyst is result of high levels of chorionic gonadotropin that is secreted from trophoblastic tissue. Elevated hormone levels of hcg stimulate the development and luteinization of multiple follicles.

This cyst reach a very large size, depending on the degree of gonadotropin stimulation but it is completely reversible.

### 1.8. Luteoma of pregnancy

Emerges during pregnancy and regresses spontaneously after delivery and is found incidentally during a Cesarean section. Some time produces androgens resulting in maternal and fetal hirsutism and virilization.

The another classification of the ovarian cysts

#### 1.8.1. Functional

Functional cysts form as a normal part of the menstrual cycle. Such cysts may include:

1. Follicular cyst,
2. Corpus luteum cysts
3. Thecal cysts

#### 1.8.2. Non-functional

Non-functional cysts may include:

1. Polycystic ovary syndrome.
2. Chocolate cysts.
3. Hemorrhagic ovarian cyst
4. Dermoid cyst
5. Ovarian serous cystadenoma
6. Ovarian mucinous cystadenoma
7. Paraovarian cyst
8. Cystic adenofibroma
9. Borderline tumoral cysts

## 2. Materials and Methods

Placentex is a product of aqueous extraction from the biochemically enriched fresh human placenta, contain nucleotides, amino acids, peptides and vitamins in natural form.

Each ml. Is derived from 0.1 gm. of fresh human placenta. Total nitrogen content not more than 0.08% w/v benzyl alcohol b.p.

Free fom HIV antibody, HCV antibody hepatitis – B surface antigen

1. Placentex – properties specific anti – inflammatory, tissue repair – wound healing immunomodulatory, melanopoetic.
2. Active ingredients of placenta are 1) DNA, 2) RNA, 3) nucleotide, 4) amino acids - tyrocine & tryptophen, 5) vitamins - in natural form, 6) minerals, 7) peptides.

The randomized & prospective study was conducted on 300 patients of ovarian cyst within the period of 3 years, age group of 20-35 years with the main symptoms of bleeding p/v or irregular bleeding p/v. The study was approved by the institutional ethics committee of the hospital.

Informed consent was obtained from all the patients before enrollment. Medical and obstetric history taking and physical examination were performed at the time of initial recruitment.

Non-symptomatic ovarian cysts are often felt by a doctor examining the ovaries during a routine pelvic exam. Symptomatic ovarian cysts are diagnosed through a pelvic exam and ultrasound.

Sonography is a clinically important imaging modality for assessing whether an adnexal mass is likely benign or possibly malignant. This is important for assessing

the need for surgery and for planning preoperative evaluation/preparation, the type of surgical procedure, and the surgical expertise required.

Computed tomography (CT) scan or magnetic resonance imaging (MRI) are also sometimes used, but less commonly. These imaging tests can also provide information about the cyst's size, location, and other important characteristics.

Ovarian cysts can be diagnosed in female fetuses by transabdominal ultrasound during the mother's pregnancy.

CA 125 is not usually recommended for premenopausal women with ovarian cysts that are small and do not appear suspicious for cancer.

2.1. Blood testing

C.B.C. & Routine blood tests were performed to rule out the medical diseases.

After diagnosis of cyst Inj. Placentrex 1Amp IM were given to the patient alternate day for 10 days along with Tab Nimesulide 100mg + Serratiopeptidase 10mg twice a day after meal.<sup>4</sup>

Patients were called for follow-up on 3<sup>rd</sup> day of 1<sup>st</sup> menstruation after completion of course and sonography was performed for presence or absence of the cyst.

3. Results

Ovarian cyst is more common in between 20-30 years of age with associated symptoms pain in abdomen, white discharge & may be having infertility. According to USG findings most of the cyst were 3-4 cm size and having clear fluid. In 15 patients there was bilateral cyst. Most of the patients tolerate the medicine very well. No adverse effect observed in any patient except mild acidity.

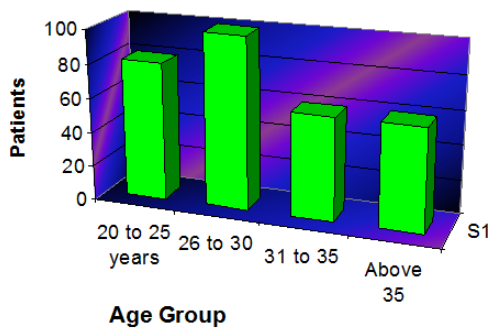


Fig. 1:

On 3<sup>rd</sup> day of 1<sup>st</sup> menses after completion of course. Sonography: No cyst-285 pts

4. Discussion

Our clinical problem for which a variety of measures have been used. Human placental extract has shown

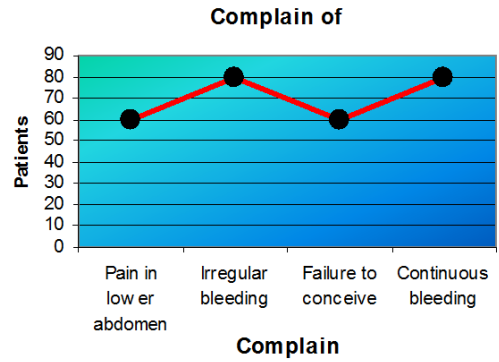


Fig. 2:

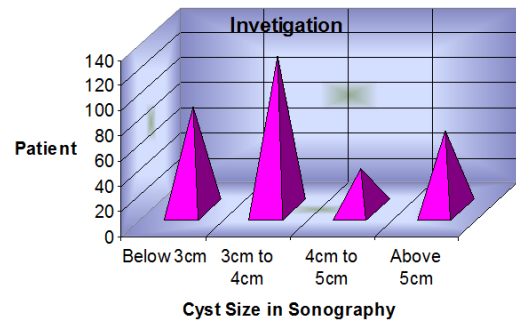


Fig. 3:

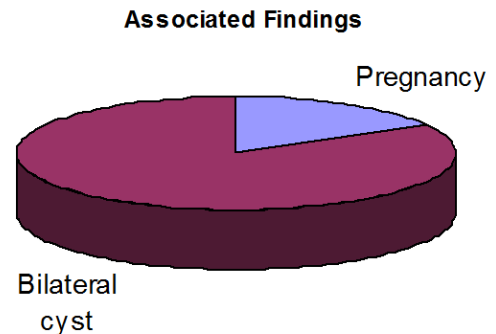


Fig. 4:

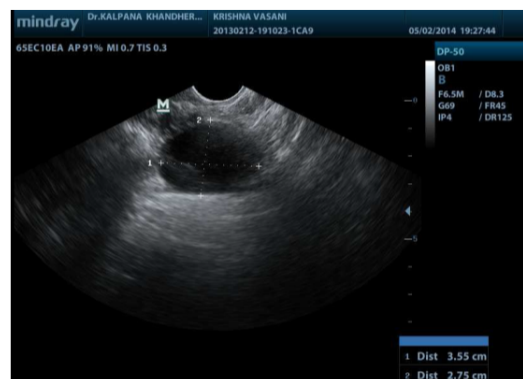

Fig. 5: Before treatment

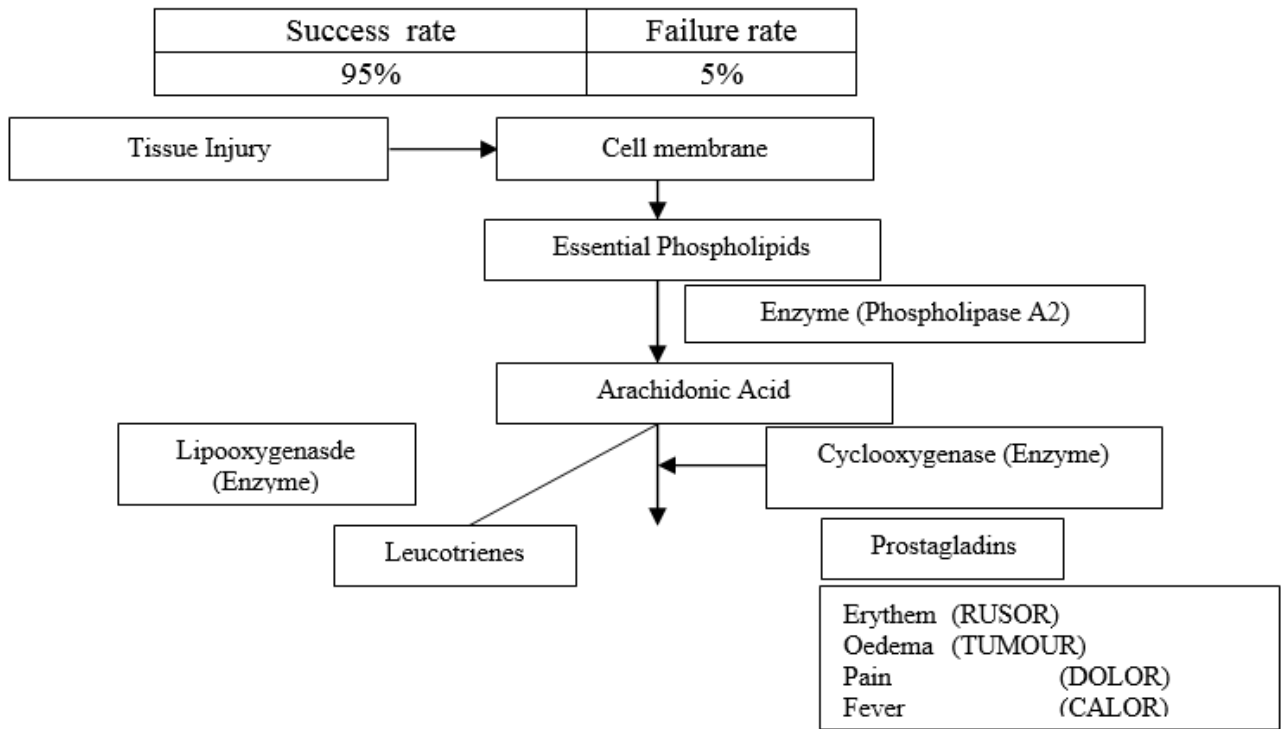


Chart 1: Process of inflammation

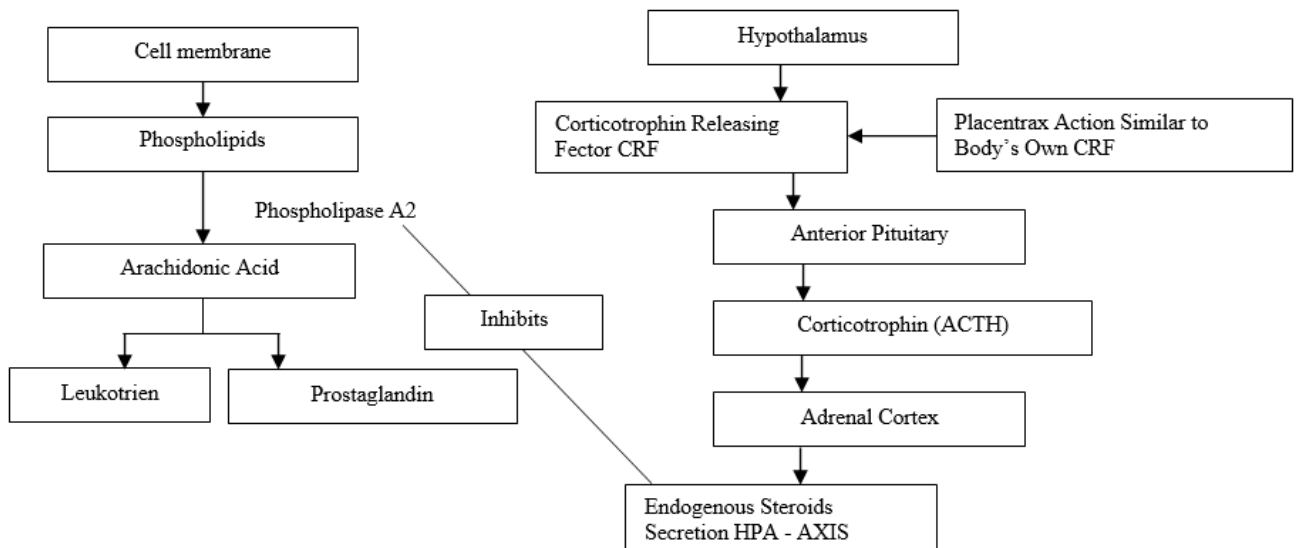
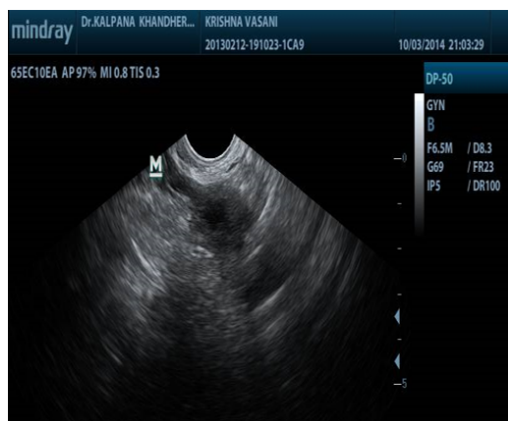


Chart 2: Anti-inflammatory effect of placentre



**Fig. 6:** After treatment

to accelerate healing process.<sup>5</sup> Shaw's text book of gynecology states that placentex (aqueous extract of fresh placenta) 2 ml IM daily or on alternate days (total of 10 inj.) has multipronged, anti-inflammatory action. It also causes tissue regeneration, wound healing, has significant immunotropic action involving both humoral & cellular immunity. The way we find the placental extract therapy today is based on tissue therapy by prof.<sup>6</sup> V. P. Filator a Russian ophthalmologist.<sup>7</sup> David Butlin in his review literature mentioned, placental extract contains peptides similar to hypothalamic factors Shibasaki et al<sup>8</sup> further corroborated this in 1982 reporting that the peptide has CRF- like activity on the release of endogenous steroid, which inhibits phospholipase A2, thus preventing the release of prostaglandins and leukotrienes – the principal chemical mediators of inflammation. About the same time Bianchini et al<sup>9</sup> reported that fraction of a nucleotide in placental extract suppressed the chemical mediators of inflammation derived from plasma, namely the complements, the kinins and coagulation factor. Thus the placental extract has all the potential of being a potent anti-inflammatory agent, wound healer and tissue regenerator.<sup>10</sup> To reinforce these properties the extract also exhibited an increase of both cell mediated as well as humoral immunity. This was evidenced by increased levels of IgG, IgM and also increase in number of T-lymphocytes.<sup>11</sup> Clinically placental extract has significant anti-inflammatory effect in PID and tubal blockade also.

The result of the present study demonstrate that INJ.PLACENTREX is very effective in treatment of functional ovarian cyst. 95% patients were cured after

the 1<sup>st</sup> course. (Another 5% patients were given another medicine). NSAID given along with inj. placentex augment the anti-inflammatory effect. Many clinician are of opinion that functional cyst do not require any treatment it will be vanished by its own within 1-3 cycle. But as evidence base study is available why to wait for 3 month with irregularity of menstrual & abdominal pain? Non surgical treatment is always preferable than surgical treatment because of less adverse effect & less financial burden.

## 5. Conflict of interest

None.

## References

1. Ovarian Cysts: What You Need to Know about an Ovarian Cyst and PCOS.
2. Timmerman L, Valentin TH, Bourne WP, Collins H, Verrelst, Vergote. Terms, definitions and measurements to describe thesonographic features of adnexal tumors: a consensus opinion from the International Ovarian Tumor Analysis &#8209;IOTA) group. *Ultrasound in Obstet Gynecol.* 2000;16(5):500–505.
3. Ovarian cysts: Causes". Mayo Clinic.
4. Agarwal N, Kulshrestha V, Kriplan A. Clinical efficacy of placentex injection in pelvic inflammatory disease. *J Indian Med Assoc.* 2010;108(2):117–118.
5. Kaushal V, Verma K, Manocha S, Hooda HS, Das BP. Clinical evaluation of human placental extract (placentex) in radiation-induced oral mucositis. *Int J Tissue React.* 2001;23(3):105–110.
6. Shaw textbook - PID (pelvic inflammatory disease).
7. Filator PVP. A Russian ophthalmologist – tissue therapy.
8. Butlin D. Peptides similar to hypothalamic factors.
9. Shibasaki. 1982 peptide has crf - like activity on the release of endogenous steroid, which inhibits phospholipase a2, prevent the release of prostaglandins and leukotrienes - principal chemical mediators of inflammation.
10. Bianchini. Fraction of a nucleotide suppress the chemical mediators of inflammation - complements, kinins, coagulation factor derived from plasma.
11. Potent anti - inflammatory agent, wound healer and tissue regenerator.

## Author biography

**Kalpana Khandheria** Professor

**Manish Pandya** Professor and HOD

**Cite this article:** Khandheria K, Pandya M. Study of injection placentex on ovarian cyst. *Indian J Obstet Gynecol Res* 2019;6(4):536-540.