

Pregnancy outcome in a patient with Moyamoya Disease

Maya Menon^{1,*}, T. A. Sridevi²

¹Associate Professor, ²Professor, Dept. of Obstetrics and Gynaecology, ESIC Medical College & PGIMSR, K. K. Nagar Chennai

*Corresponding Author:
E-mail: mayasree@gmail.com

ABSTRACT

Moyamoya disease is a rare cerebrovascular occlusive disorder characterised by bilateral stenosis of terminal portion of the internal carotid artery near circle of Willis. This is a case of 28 yrs primigravida diagnosed as childhood stroke secondary to Moyamoya disease with left hemiparesis on antiepileptic drugs booked under combined care of obstetrician and neurologist was started on anticoagulant along with iron, calcium and folic acid. Antenatal period was uneventful. Patient had spontaneous on set of labour and had a assisted vaginal (vacuum) delivery, alive female baby was delivered with Apgar score of 8/10. Care was taken to avoid dehydration and hypotension during the peripartum period. There are no prospective trials that address the safest mode of delivery for women with MMD. Pregnant patient should be counselled about the risk and potential benefit of medical and surgical treatment and managed by multidisciplinary team of obstetrician, neurologist, neurosurgeon and anesthesiologist.

BACKGROUND

Moyamoya disease is a rare cerebrovascular occlusive disorder characterised by bilateral stenosis of terminal portion of internal carotid artery near circle of Willis. Moyamoya is Japanese for puff of smoke & describe the appearance of resultant network of abnormal small collateral vessels seen on angiography. This was recognised in Japan in 1960. The incidence in Japan is 0.35 per 100,000 compared to USA 0.08 per 100,000^[1]. There are limited studies that review the presence of MMD in pregnancy³. Pregnancy is associated with an increased risk of thrombosis due to elevated level of estrogen, decreased fibrinolytic activity and increased plasma volume. The cerebrovascular events in patients with MMD is as high as 50-75%^[1]. Imaging techniques like CT Angiogram, Magnetic Resonance Angiogram, gold standard being Digital Subtraction Angiogram help in the diagnosis of Moyamoya disease and the abnormal vascular networks in the vicinity^[2]. Cerebrovascular events like headache, stroke, hemiparesis, seizure, speech deficits & vision problem can occur. It is important to

control blood pressure and avoid preeclampsia during pregnancy^[3].

CASE

28 yrs primigravida diagnosed as childhood stroke secondary to Moyamoya disease with left hemiparesis on antiepileptic drugs, was under the combined care of obstetrician & neurologist from 1st trimester. Patient had undergone Contrast CT Scan followed by CT Angiogram prior to her pregnancy, to exclude development of new collateral vessels. She was started on prophylactic anticoagulant therapy along with iron, calcium, folic acid & antiepileptic drugs. Antenatal period was uneventful. Patient was admitted at 39wks of pregnancy, with spontaneous on set of labour pains, and had vacuum assisted vaginal delivery. Alive female baby, weighing 2.77kg with Apgar score of 8/10 was delivered. Care was taken to avoid dehydration and hypotension during the peripartum period. Patient was started on low molecular weight Heparin after 12 hours and continued for 5 days. She was discharged and advised to continue antiepileptic drugs.

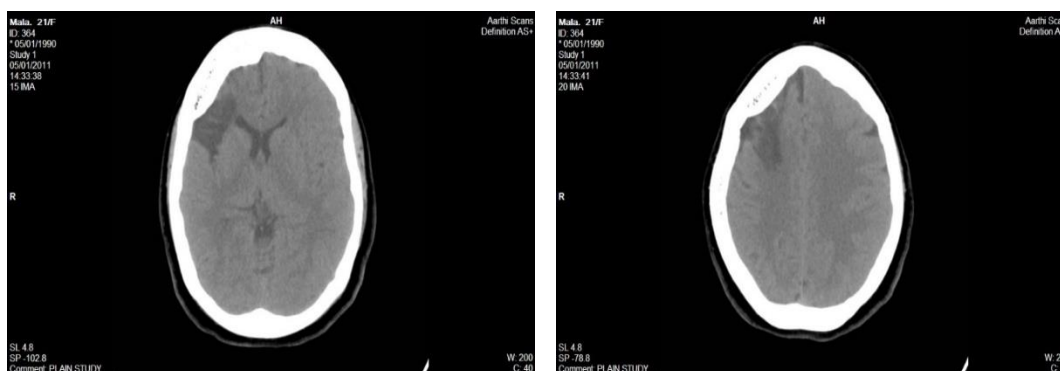


Fig. 1: Wedge Shaped Region of Hypo Density in the Cerebro Frontal Hemisphere – Suggesting Infarct

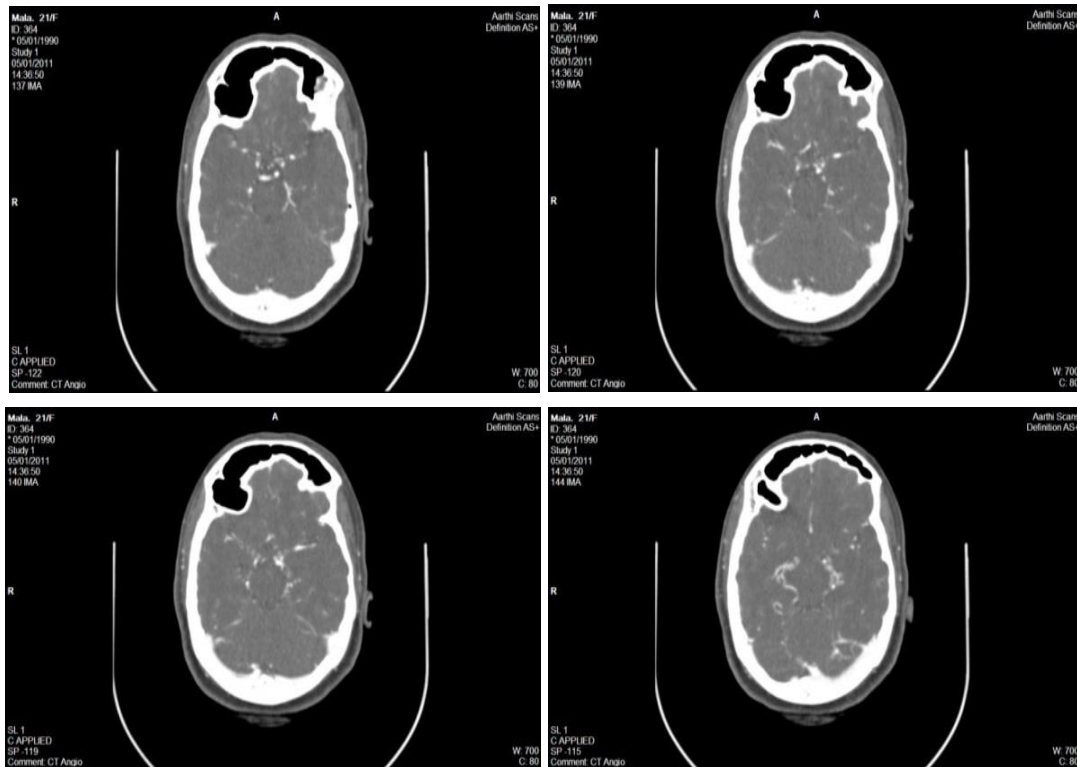


Fig. 2: Multiple collateral channel in the circle of Willis

DISCUSSION

There are limited studies that review association of Moyamoya disease during pregnancy. The challenges encountered in managing these cases during pregnancy and labour are increased risk of thrombosis, hypervolemia, increased intracranial pressures and hypocapnia^[2]. Moyamoya disease is characterised by presence of luminal thrombosis, hyperplasia of smooth muscle cells, thinned media and weakend arterial wall. In response to occlusion of distal internal carotid artery fragile collateral blood vessels and small microaneurysms develop which are due to changes in circulatory pattern and sheer stresses at bifurcation at the base of the brain^[3]. Haemorrhagic stroke is due to the fragility of the collateral vessels and is more common in adults than children with MMD. The physiologic changes during pregnancy may affect the natural history of the disease. There is evidence that development of collateral vessels is due to upregulation of proangiogenic enzymes in response to increase blood flow^[1]. Pregnancy is associated with 34% increased risk of stroke. Cerebrovascular events occurring in patients diagnosed with Moyamoya disease is as high as 50-75%^[1]. There are few trials regarding the safest mode of delivery of women with MMD. During labour, Valsalva and increased intracranial pressure can cause hemodynamic stresses on fragile cerebral blood vessels, predispose patient to haemorrhagic stroke. Hyperventilation, alkalosis, and hypocapnia

predisposes to ischemic stroke^[4]. Neuroaxial anesthesia with prior sedation is recommended as the anesthetic choice over general anesthesia^[5,6]. There is no curative treatment for MMD. Surgical intervention is palliative rather than definitive and to be performed 6 months prior to planning the pregnancy^[3]. Surgical treatment includes extracranial-intracranial revascularization (EC-IC bypass) through either direct or indirect method. The success of surgery is dependent on the development of neovascularization, it takes 3-6 months and this reduce the risk of intracranial haemorrhage during pregnancy. Direct method is bypass between the superficial temporal artery and the middle cerebral artery (STA-MCA). Indirect method includes Extradural arteriosynangiosis (EDAS), Encephalomyoar-teriosynangiosis (EMS) and pial synangiosis. Medical management with antiplatelet drugs (aspirin and dipyridamole) decrease the risk of microemboli as risk of thrombosis is increased during pregnancy^[3]. Calcium channel blockers and magnesium sulphate have vasodilatory properties and can be used as antihypertensive drugs in pregnancy with MMD^[1]. Patients with MMD contemplating pregnancy should be advised regarding the potential risks of pregnancy. This condition should be managed by multidisciplinary team consisting of obstetrician, neurologist, neurosurgeon and anesthesiologist.

CONCLUSION

The safest mode of delivery of women with MMD is not clear... During pregnancy Careful management of increased blood volume and prevention of thrombosis are essential. It is important to control blood pressure to avoid pre-eclampsia during pregnancy. During labour, increased intracranial pressure and hypocapnia are to be managed effectively Pregnant patient should be counselled about the risk & potential benefit of medical & surgical treatment & managed by multidisciplinary team of obstetrician, neurologist, neurosurgeon and anaesthesiologist. Either Caesarean section or vaginal delivery can be accomplished safely with special attention given to avoid hypocapnia, hypotension and hypertension. Oral contraceptives should be avoided in the postnatal period.

REFERENCES

1. Scott R, Smith E. Moyamoya disease and moyamoya syndrome. *New Eng. J of Med.*2009;360:1226-1237.[PubMed] DOI: 10.1056/NEJMra0804622
2. Komiyama M, Yasui T, Kitano S. Moyamoya disease and pregnancy: Case report and review of the literature. *Neurosurgery.*1998;43:360-368.[Pubmed] DOI: 10.1097/000006123-199808000-00114
3. Jacklyn C Ma, MSIV and Janet M Burlingame. Moyamoya Disease in Pregnancy: A Case Series and Review of Management Options. *Hawai Med J.*2011 Aug; 70 (8):161-163.
4. Yamashita T, Shibuta S: Two patients with Moyamoya Disease underwent emergency caesarean delivery resulted in opposite outcomes *J Anaesth Clinic Res* 2:159.2011;4172/2155-6148.1000159.
5. Dutta B, Dehran M, Sinha R: Anaesthetic management of a parturient with moyamoya disease; *Singapore Med J* 2011;52 (6):108.
6. Kato R, Terui K, Yokota K, Nakagawa C, Uchida J, et al. Anaesthetic management for caesarean section in moyamoya disease: a report of five consecutive cases and a mini –review. *Int J Obstet Anaesth* 2006; 15:152-158.