



Case Report

Successful pregnancy outcome after fetal reduction in a woman with quadruplet pregnancy to twin pregnancy

Geetha Krishnamoorthy¹, Koduri Dhruvitha^{1,*}, P Amutha¹

¹Dept. of Obstetrics and Gynaecology, Vinayaka Missions Medical College, Karaikal, Puducherry, India



ARTICLE INFO

Article history:

Received 03-03-2020

Accepted 09-04-2020

Available online 15-06-2020

Keywords:

Total reduction

Multifetal pregnancy

IVF

Transvaginal embryo reduction

PPROM

ABSTRACT

First trimester transvaginal embryo reduction is an effective alternative for the management of multifetal pregnancy in assisted reproduction and is done by performing an intracardiac embryo puncture until a systole is verified.

A 32-year-old G2 A1 conceived through in vitro fertilization (IVF) at 10 weeks of gestation. Ultrasonography confirmed quadruplet pregnancy with viability of all four fetuses with minimal sub chorionic hemorrhage. The couple was counselled about all potential complications and were counselled to undergo fetal reduction of quadruplets to twins. She underwent fetal reduction and pregnancy was uneventful in first and second trimesters with regular antenatal check-ups. In third trimester the woman with 35 weeks of gestation with twin breech presented with premature preterm rupture of membranes (PPROM), delivered by emergency lower section caesarean section (LSCS) with first twin as breech and second twin as vertex. First twin was delivered with birth weight 1.75 kg and second twin with birth weight 1.75 kg.

© 2020 Published by Innovative Publication. This is an open access article under the CC BY-NC license (<https://creativecommons.org/licenses/by-nc/4.0/>)

1. Introduction

Multifetal pregnancy constitutes a common iatrogenic outcome of ovarian stimulation with fertility drugs and assisted reproductive technique, quadruple pregnancy is considered as very high-risk pregnancy due to potential complications with increased perinatal, neonatal and infant mortality rate.¹⁻³ Multifetal pregnancy reduction is defined as first trimester or early second trimester procedure for reducing the total number of foetuses in multifetal pregnancy by one or more selective reduction foetus are chosen based on health status by ultrasonography by foetus with abnormality or disease risk is chosen for reduction.^{4,5} Reduction of quadruplets to twin pregnancy improves perinatal morbidity and mortality.⁶

2. Case Report

32 years old female was admitted in the department of Obstetrics and Gynaecology at Vinayaka Missions Medical College and Hospital, Karaikal, Pondicherry with obstetric score of G2 A1 conceived by IVF and resulted in quadruplet pregnancy (Figure 1).

It was decided to reduce the fetuses to twin pregnancy at 10 weeks in view of the early pregnancy losses. Selective fetal reduction was carried out trans vaginally under ultrasound guidance using potassium chloride (KCl) with a separate needle for each fetus.

Under strict aseptic precautions, a 22G needle of 15cm was introduced under ultrasound guidance into the thoracic cavity of foetuses to be reduced. Two ml of KCl was injected into the thoraces of fetuses C and D. Cessation of fetal cardiac activity and movements were noted in fetuses C and D. Post reduction, other two foetuses A & B showed normal cardiac activity and movements (Figure 3). A reconfirmation of absent cardiac activity in the reduced fetuses and presence of cardiac activity in other two foetuses

* Corresponding author.

E-mail address: dhruvithak@gmail.com (K. Dhruvitha).

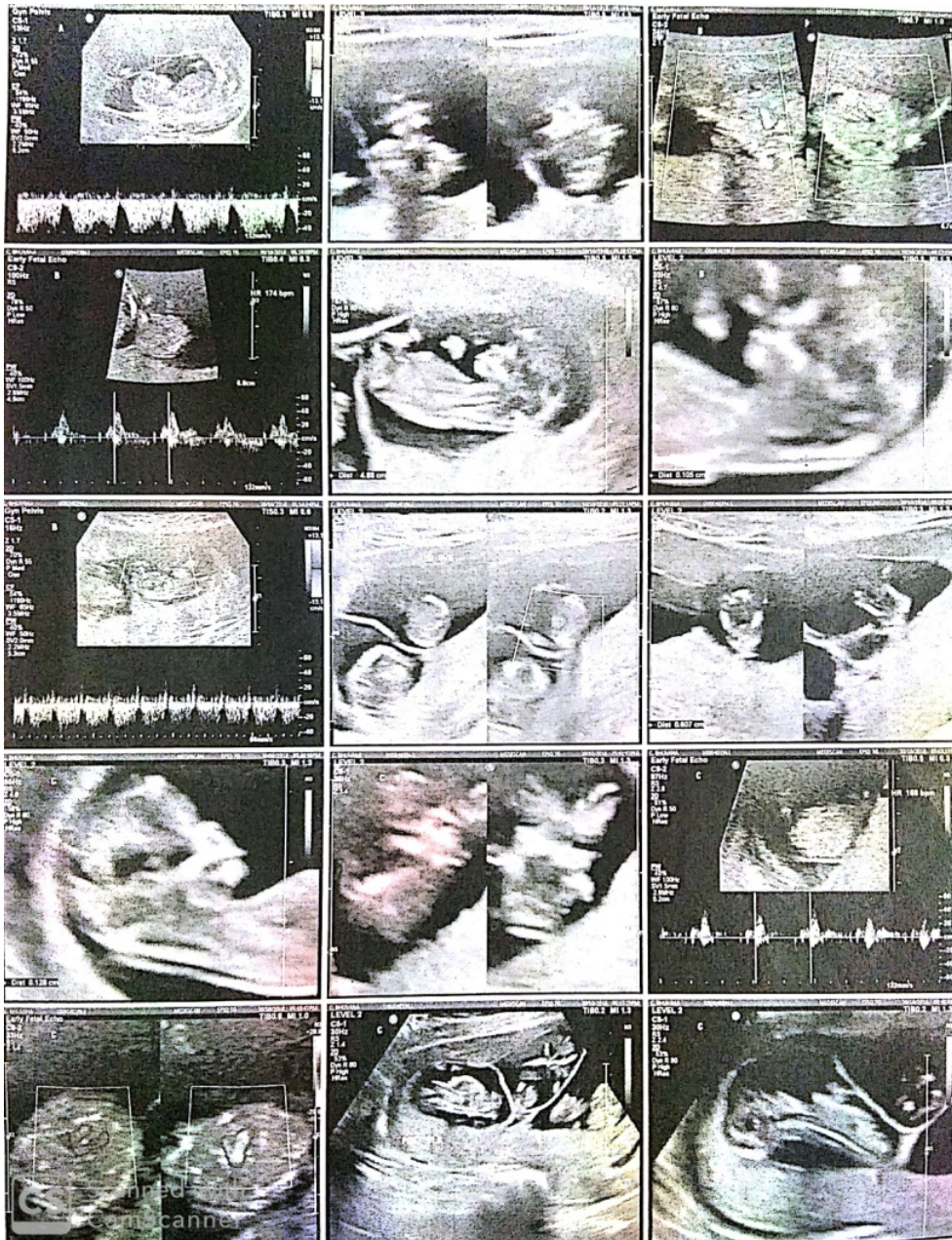


Fig. 1: Shows quadri chorionic quadri amniotic quadruplet gestation with gestational age of 11 weeks with subchorionic hemorrhage before fetal reduction (Before Reduction)

was done after 3 hours (Figure 2). Patient is advised to take rest for next 24 hours. Repeat scan was done at 22 weeks of gestation and was normal (Figure 4). The pregnancy was uneventful. In third trimester at 35 weeks of gestation, she presented with complaints of leaking per vaginam and pain in lower abdomen, underwent emergency LSCS (indication being PPROM with twin breech) delivered first baby as breech and second baby as vertex. Birth weight of first twin (girl baby) 1.7 kg and second twin (boy baby) 1.6 kg respectively. The APGAR scores of first-born twin were

6/10 at 5 min and 8/10 at 10 min and APGAR scores for second born twin were 8/10 at 5 min and 9/10 at 10 min. Both infants were admitted to neonatology department because of low birth weight for 10 days for observation.

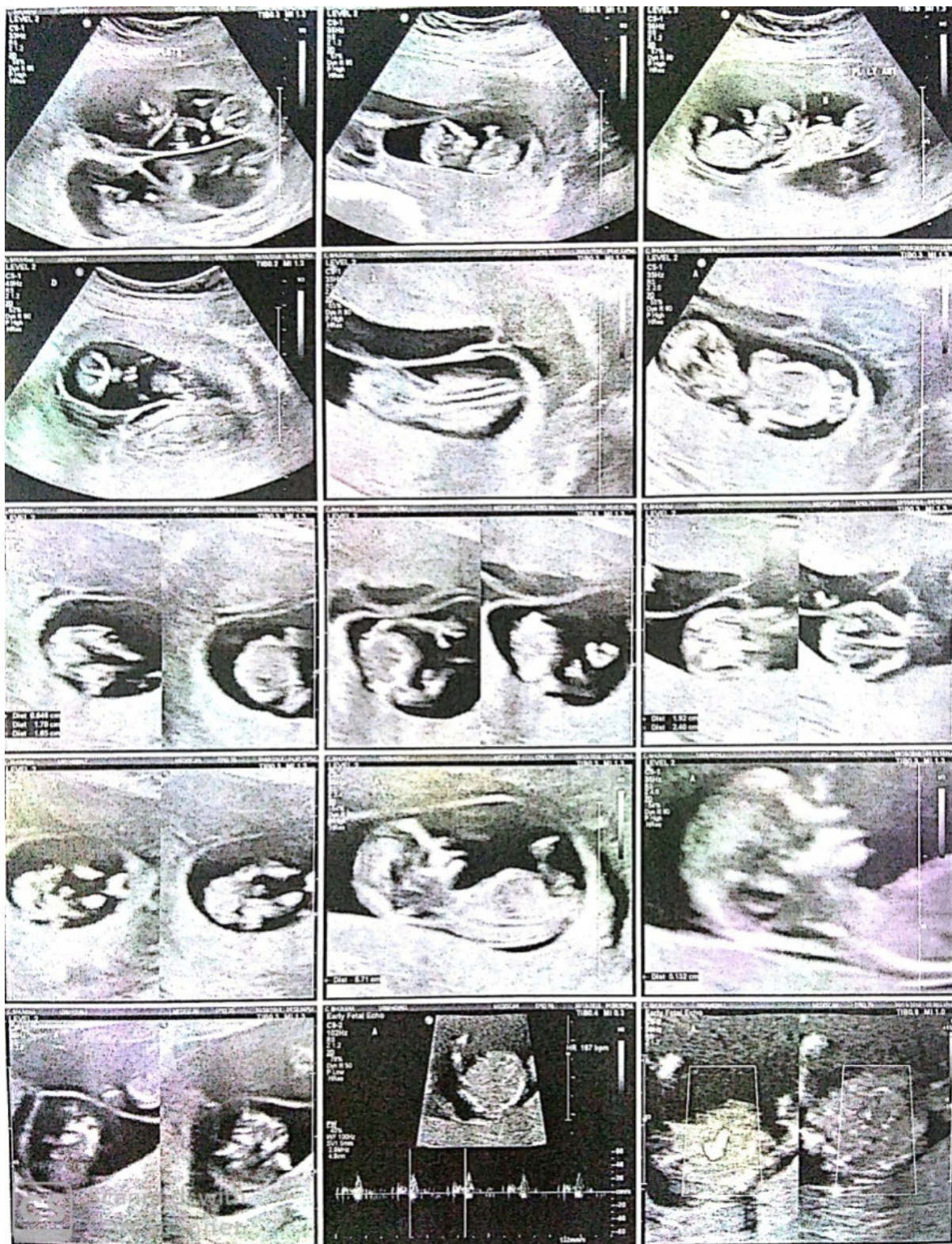


Fig. 2: Shows fetus C and D with a systole after fetal reduction (after reduction)

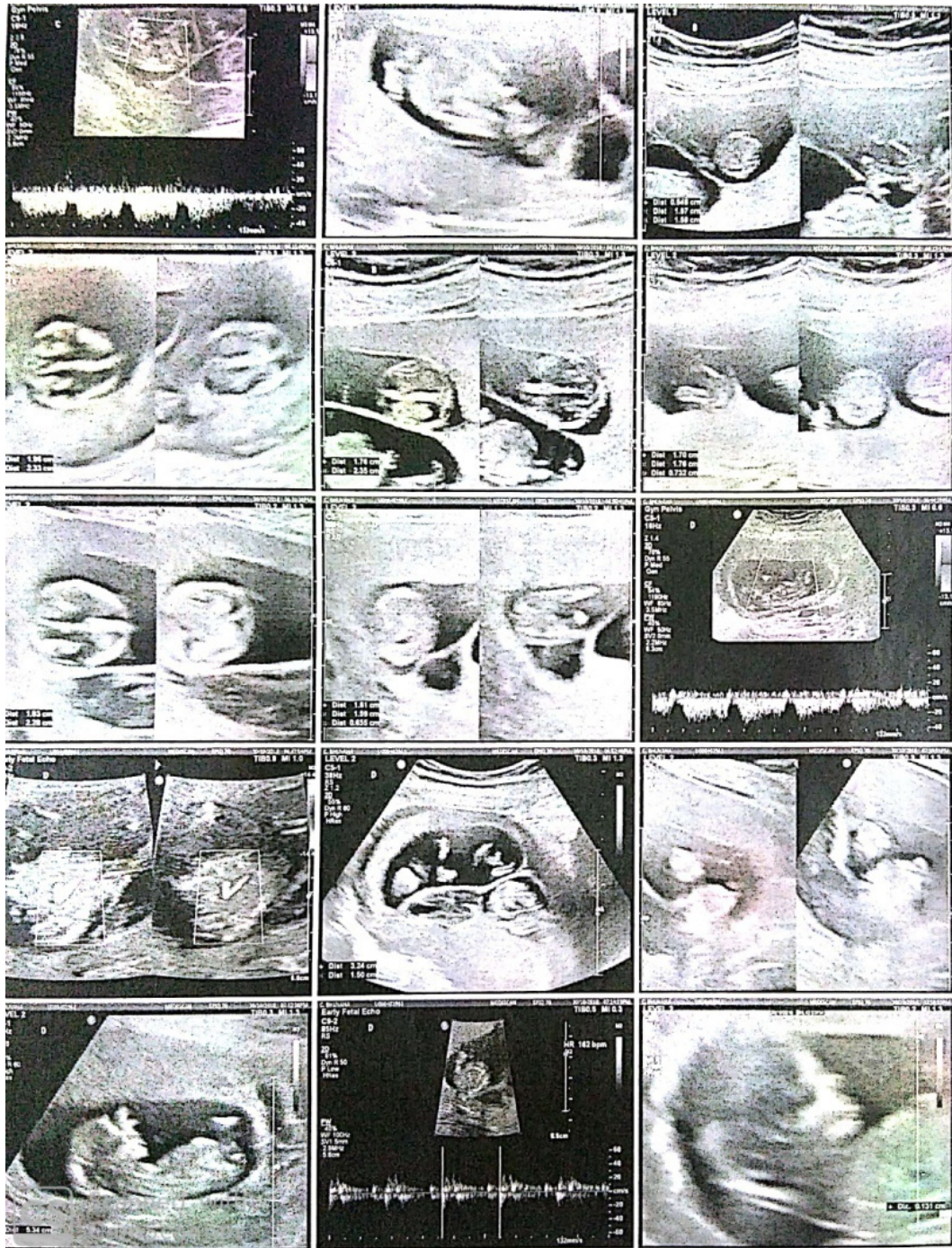


Fig. 3: Shows normal cardiac activity of fetus A and B after reduction

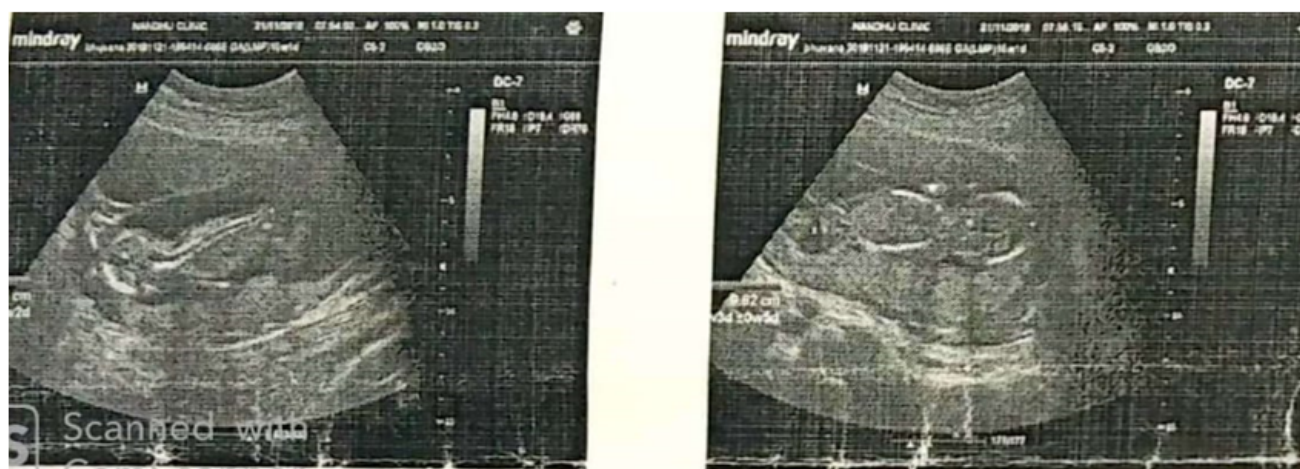


Fig. 4: Shows twin gestation at 22 weeks. (Follow up scan)

3. Discussion

The incidence of multifetal pregnancies may be as high as 8% of all pregnancies resulting from use of ovulation induction drugs and as high as 53% after the use of gonadotropin.⁷ In vitro fertilisation and embryo transfer also increase the incidence of multifetal pregnancies upto 30%.⁸ In our case, patient was counselled about the risk of higher spontaneous abortions and preterm labour rates in multiple pregnancies and was offered the option of fetal reduction.⁹ The risks of procedure was explained to the patient and informed consent was obtained.¹⁰

Haiyan et al., reported a case of triplet pregnancy, during first trimester management options included fetal reduction of two twins by fetal intracardiac injection of KCl by ultrasound guided trans abdominal procedure.¹¹ In our case the patient underwent ultrasound study that confirmed viability of all four foetuses with quadri chorionic quadri amniotic quadruplet gestation. We performed quadruplet pregnancy foetal reduction through transvaginal ultrasound guided injection of KCl into thoraces of both foetuses C and D. Cessation of fetal cardiac activity and movements were noted in fetuses C and D.

Van de Mheen et al., showed that if fetal anomaly for chromosomal or structural malformation were suspected, the fetal reduction would be performed selectively on that fetus.¹² If no fetal anomaly was suspected then the smallest sac or the sac proximal to the uterine fundus would be selected. Selective termination can be done when fetal reduction used for significant developmental abnormality between 12 and 14 weeks of gestation and was showed that success rates were higher with abdominal than vaginal approach.¹³

Fawaz et al., reported that compared with twin pregnancies triplet and quadruplet gestation are more likely to be diagnosed with PPROM delivered at less than 29 weeks of gestation.¹⁴ The gestational age at delivery for

quadruplets varied in different reports, ranging from 28 weeks to 31 weeks. Compared to the above, our case got delivered at 35 weeks of gestation with twin breech PPROM delivered by emergency LSCS.

4. Conclusion

High order multiple pregnancies are associated with increased incidence of pregnancy complications like abortions, pre-eclampsia, preterm delivery and fetal death.¹⁵ Fetal reduction is increasingly common in context of infertility treatments for multiple fetal pregnancies.¹⁶ Fetal reduction procedure improves perinatal outcomes.

5. Source of Funding

None.

6. Conflict of Interest

None.

References

1. Talwar P, Sharma RK, Sandeep K, Sareen S, Duggal BS. Embryo reduction: our experience. *Med J Armed Forces India.* 2011;67(3):241–4.
2. Boulot P, Vignal J, Vergnes C, Dechaud H, Faure JM, Hedon B. Multifetal reduction of triplets to twins: a prospective comparison of pregnancy outcome. *Human Reprod.* 2000;15(7):1619–23.
3. Mansour RT, Aboulghar MA, Serour GI, Sattar MA, Kamal A, Amin YM. Multifetal pregnancy reduction: modification of the technique and analysis of the outcome. *Fertil Steril.* 1999;71(2):380–4.
4. Committee Opinion No. 719. *Obstet Gynecol.* 2017;130(3):158–63.
5. Iberico G. Embryo reduction of multifetal pregnancies following assisted reproduction treatment: a modification of the transvaginal ultrasound-guided technique. *Human Reprod.* 2000;15(10):2228–33.
6. Lee J, Ku S, Jee B, Suh C, Kim K, Kim S. Pregnancy Outcomes of Different Methods for Multifetal Pregnancy Reduction: A Comparative Study. *J Korean Med Sci.* 2008;23(1):111.
7. Tadin I, Roje D, Banovic I, Karelavic D, Mimica M. Fetal Reduction in Multifetal Pregnancy: Ethical Dilemmas. *Yonsei Med*

- J.* 2002;43(2):252.
8. Smith MJ, Lana D. Ethical Considerations for the Reduction of Multifetal Pregnancies; 2015.
 9. Dey M, Saraswat M. Outcomes of multifetal reduction: A hospital-based study. *J Obstet Gynecol India.* 2018;68(4):264–9.
 10. Liu C, Lu X, Xi H, Xu J, Su W, Zhao J. The value of fetal reduction in IVF dichorionic triplets: A retrospective controlled study. *Clin Surg.* 2019;4:2445.
 11. Lin H, Wen Y, Li Y, Chen X, Yang D, Zhang Q. Early fetal reduction of dichorionic triplets to dichorionic twin or singleton pregnancies: a retrospective study. *BioMedicine Online.* 2016;32(5):490–5.
 12. van de Mheen L, Everwijn SMP, Knapen MFCM, Haak MC, Engels MAJ, Manten GTR, et al. Pregnancy outcome after fetal reduction in women with a dichorionic twin pregnancy. *Human Reprod.* 2015;30(8):1807–12.
 13. Fetal reduction. *Fertil Steril.* 2007;87(4):44–6.
 14. Edris FE. Trichorionic Quadruplet Delivered Beyond 36 Weeks of Gestation: A Case Report and Literature Review. *Case Rep Obstet Gynecol.* 2011;2011. doi:10.1155/2011/181034.
 15. Liu Y, Wang XT, Li HY, Hou HY, Wang H, Wang YY. Effect of selective second trimester multifetal pregnancy reduction and its timing on pregnancy outcome. *Int J Clin Exp Med.* 2017;10(3):5533–7.
 16. & Joann MVR, Pinkerton V. Elective fetal reduction: The ultimate elective surgery. *J Contemp Health L Poly.* 1997;13(1):53–77.

Author biography

Geetha Krishnamoorthy Associate Professor

Koduri Dhruvitha Post Graduate

P Amutha Professor and HOD

Cite this article: Krishnamoorthy G, Dhruvitha K, Amutha P. Successful pregnancy outcome after fetal reduction in a woman with quadruplet pregnancy to twin pregnancy. *Indian J Obstet Gynecol Res* 2020;7(2):267-272.