



Case Report

Pemphigoid gestationis – A rare case report

Tarun Joseph^{1,*}, Rekha Kurian¹, Kurian Joseph¹, Sivashankari¹,
Vasanthi Balamurugan¹

¹Dept. of Obstetrics and Gynaecology, Joseph Hospitals, Chennai, Tamil Nadu, India



ARTICLE INFO

Article history:

Received 28-01-2020

Accepted 15-02-2020

Available online 15-06-2020

Keywords:

Pemphigoid gestationis
Autoimmune dermatosis
vesicobullous lesion
Prednisone
Azathioprine

ABSTRACT

A number of physiologic cutaneous changes occurs during pregnancy due to immunologic, hormonal or metabolic factors. Pathologic skin lesions are rare but its important to distinguish due to potentially detrimental effects on both mother & fetus. Pemphigoid gestationis is a rare pruritic autoimmune dermatosis associated with several adverse fetal outcomes. 30yrs old primigravida at 22weeks gestation presented to us with an intensely pruritic vesicobullous lesion which was further diagnosed as pemphigoid gestationis. Hence patient was started on Prednisone & Azathioprine, then gradually tapered to appropriate maintainance dose. Patient had preterm rupture of membranes and delivered a healthy baby vaginally. Proper management of this dermatological condition requires a suitable drug therapy, close monitoring and multi disciplinary team approach which is essential to reduce maternal and neonatal morbidity and to achieve favourable obstetric outcome.

© 2020 Published by Innovative Publication. This is an open access article under the CC BY-NC license (<https://creativecommons.org/licenses/by-nc/4.0/>)

1. Introduction

Pemphigoid gestationis is a rare dermatological condition, most commonly presented in the second trimester of pregnancy with itching as the key complaint. Since its a common complaint, we tend to miss the diagnosis and treatment at the appropriate time leading to preterm birth and neonatal pemphigoid gestationis.¹ Hence this case is being presented to increase the awareness regarding the diagnosis of pemphigoid gestationis in pregnant women with itching.

2. Case Report

A 29 year old booked primigravida presented to the obstetric department with complaints of itching at 22 weeks which further progressed to hive like rashes over abdomen around umbilicus and later spreading on to arms and thighs within a week, not subsiding with antihistamines. At 24 weeks, patient started having intense itching along with tense

fluid filled vesicobullous lesions for which dermatologist opinion was obtained.

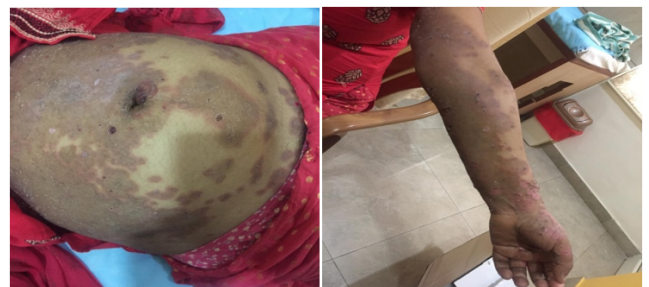

Fig. 1: Hive like rashes over abdomen & arms

2.1. Investigations

In order to confirm the diagnosis Bullous Pemphigoid Antibody titre was done which showed positive at high range (>200U/ml). Following which Skin biopsy and immunofluorescence were done to confirm the diagnosis.

* Corresponding author.

E-mail address: tarunjoseph2000@gmail.com (T. Joseph).

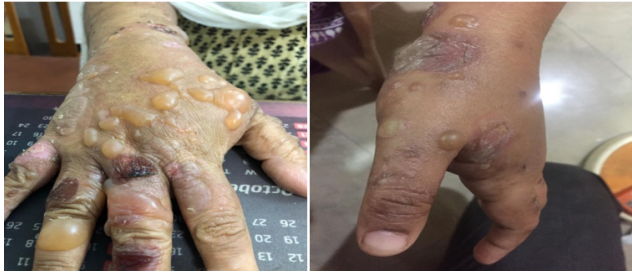

Fig. 2: Progressed to bullous lesions

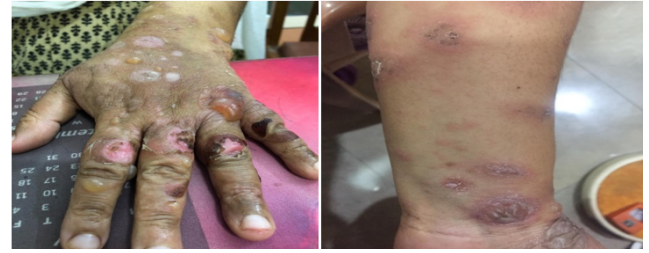

Fig. 5: Healing lesions

2.2. Skin biopsy

Subepidermal clefting with Eosinophil rich leukocytic infiltrate

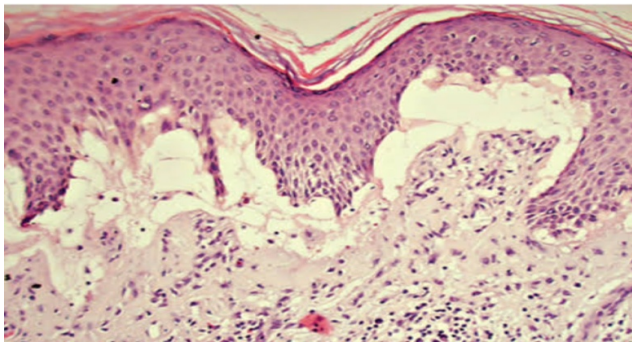


Fig. 3:

2.3. Immunofluorescence

IgG/C3 deposition- Linear Fluorescence seen in the dermo epidermal Junction

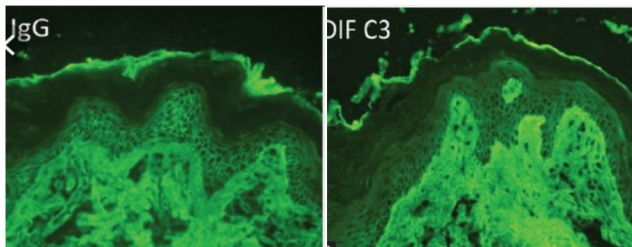


Fig. 4:

2.4. Treatment

Patient was started on Prednisolone 20mg/day at 24weeks and dose was slowly stepped upto 60mg/day. Since patient continued to have new lesions, Azathioprine 100mg/day was added at 28weeks. Following which patient was symptomatically better.

2.5. Outcome & follow up

Patient was admitted with preterm premature rupture of membranes at 33wks, progressed spontaneously and delivered a healthy male baby weighing 2.3Kgs. Postnatally baby was completely normal and patient continued to be on tapering doses of steroids and Azathioprine was stopped. Bullous pemphigoid Antibody was repeated which showed a declining trend. As the lesions were severe, postnatal recovery took 6 months.

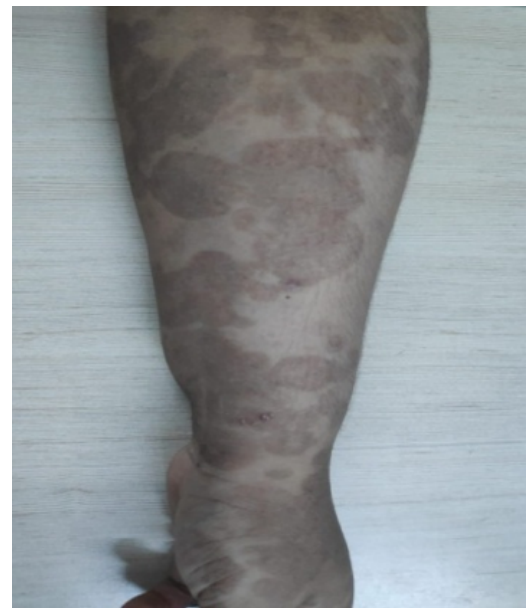

Fig. 6: After 2 months

3. Discussion

Pemphigoid gestationis is clinically similar to pemphigoid group of autoimmune blistering skin disorders. It occurs in approximately 1 in 50000 pregnancies,² usually after the second trimester. Women are at high risk of developing graves disease.³ It is an autoimmune response preventing adherence between dermis and epidermis because of different hemidesmosomal proteins. Basement membrane protein 180 is the key structural protein in the placenta which cross reacts with the same protein on the skin

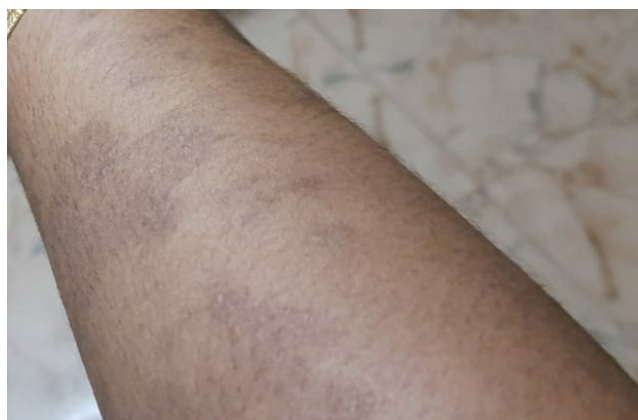

Fig. 7: After 6 months

producing autoimmune response and complement activation which further leads to deposition of immune complex and chemo attraction of eosinophil granulocytes, leading to tissue damage and blister formation.⁴ This condition usually starts with intense itchy erythematous papules and plaques around umbilicus then spreads to abdomen, back, chest and extremities, sparing the face, mucosal membranes, palms and soles, later leading to blisters formation.⁵ Symptoms in early stage resembles pruritic urticarial plaques and papules of pregnancy (PUPP) and Polymorphic Eruptions of Pregnancy (PEP) which lacks both blisters and autoimmune response thus differing from pemphigoid gestationis.⁶

Classical histopathological findings are urticarial lesions characterised by subepidermal edema with perivascular infiltrate of lymphocytes, histiocytes and eosinophils. The presence of eosinophils is the most constant feature of histopathological appearance of pemphigoid gestationis.⁷ Direct immunofluorescence demonstrates linear deposition of complement 3(C3) and IgG autoantibodies at the dermoepidermal junction.^{8,9} Bullous Antibody by ELISA shows circulating IgG antibody against BP180 which correlates with disease severity with sensitivity of 86-97% and specificity of 94-98%.¹⁰

Treatment of pemphigoid gestationis starts with topical emollients and antihistamines. In severe cases, systemic steroid therapy and immunosuppressants like Azathioprine, cyclosporine can be used.¹¹ If these treatments are ineffective intravenous immunoglobulin, plasmapheresis and immunoadsorption techniques can be used.¹² In a study from UK with 69 patients, 13(19%) were treated with topical corticosteroids, 56(81%) required systemic corticosteroids. Most patients experienced remission with systemic corticosteroids, but 15(22%) required additional treatment with immunosuppressants.¹³

Generally, this condition tends to exacerbate postpartum in 75% of patients. Duration of active disease ranges from 2 weeks to 12 years postpartum.¹³ Recurrence of disease might happen with women on oral contraceptive pills or during menstruation.^{14,15} Recurrence in subsequent

pregnancies is almost 90%, occurs early in pregnancy and more severe.¹⁶

3.1. Fetal concerns

Fetal prognosis is generally good, but risks being small for gestational age babies and premature birth.² Shornick et al in his observation showed that 16% of patients with Pemphigoid gestationis delivered before 36 weeks, while its 2% in uncomplicated pregnancies.¹⁶ Low birth weight babies which is one of the complication is due to the immune response between placental antigens and antibodies leading to placental insufficiency.¹³ Neonatal pemphigoid occurs due to passive transfer of antibodies from mother to fetus. About 10% of newborns may develop urticarial or vesicular skin lesions. These lesions are self limiting, subsides within few days to weeks when the antibody levels decreases.¹⁷ There is no role of induction of labour but needs close monitoring by regular ultrasound in case of low birth weight babies and it is important to be aware of the risks of preterm birth.¹

4. Conclusion

Pemphigoid gestationis is a self limiting condition, needs appropriate diagnosis and treatment. The prognosis is usually good except for the complications like small for gestational age, low birth weight babies and preterm birth. Patients should be counselled regarding the prognosis, treatment possibilities, relapse after delivery and subsequent pregnancies.

5. Source of Funding

None.

6. Conflict of Interest

None.

References

1. Lardenoije CMJG, van de Water M, Mertens HJMM, Gondrie ETCM. Pemphigoid gestationis. *BMJ Case Rep.* 2011;doi:10.1136/bcr.01.2010.2623.
2. Shornick JK, Black MM. Secondary autoimmune disease in herpes gestationis. *J Am Acad Dermatol.* 1992;26:563–6.
3. Dupont C. Herpes gestationis with hydatidiform mole. *Trans St Johns Hosp Dermatol Soc.* 1974;60:103.
4. Warshafsky C, Tron VA, Robertson D, Kives S. Pemphigoid Gestationis: A Case Presentation. *J Cutan Med Surg.* 2018;22(4):435–8.
5. Seidel R, Lavi N, Chipps L. Pemphigoid gestationis. A case report and review of management. *J Drugs Dermatol.* 2015;14(8):904–7.
6. Kwon EJ, Ntiamoah P, Shulman KJ. The utility of C4d immunohistochemistry on formalin fixed paraffin embedded tissue in the distinction of polymorphic eruptions of pregnancy from pemphigoid. *Am J Dermatopathol.* 2013;35(8):787–91.
7. Ambros-Rudolph CM. Dermatoses of pregnancy – clues to diagnosis, fetal risks and therapy. *A Dermatol.* 2011;23(3):265–75.

8. Lipozencic J, Ljubojevic S, Bukvic Mokes Z. Pemphigoid gestationis. *Clin Dermatol*. 2012;30(1):51–5.
9. Intong LRA, Murrell DF. Pemphigoid Gestationis: Pathogenesis and Clinical Features. *Dermatol Clin*. 2011;29(3):447–52.
10. Sitaru C, Powell J, Messer G, Bröcker EB, Wojnarowska F, Zillikens D. Immunoblotting and Enzyme-Linked Immunosorbent Assay for the Diagnosis of Pemphigoid Gestationis. *Obstet Gynecol*. 2004;103(4):757–63.
11. Rodrigues C, Filipe P, Solana M, de Almeida L, de Castro J, Gomes MM. Persistent Herpes Gestationis Treated with High-dose Intravenous Immunoglobulin. *Acta Dermato-Venereologica*. 2007;87(2):184–6.
12. Jones V, Hern S, Nelson-Piercy, Seed PT, Black MM. A prospective study of 200 women with dermatoses of pregnancy correlating clinical findings with hormonal and immunopathological profiles. *Br J Dermatol*. 1999;141(1):71–81.
13. Jenkins, Hern, Black. Clinical features and management of 87 patients with pemphigoid gestationis. *Clin Exp Dermatol*. 1999;24(4):255–9.
14. Lynch FW. Homonal factors in herpes gestationis. *Arch Dermatol*. 1966;93(4):446–7.
15. Hönigsman H, Stingl G, Holubar K, Wolff K. Herpes Gestationis: Fine Structural Pattern Of Immunoglobulin Deposits In The Skin In Vivo. *J Invest Dermatol*. 1976;66(6):389–92.
16. Shornick JK. Dermatoses of pregnancy. *Semin Cutan Med Surg*. 1998;17(3):172–81.
17. Jenkins RE, Shornick J. *Obstetric and gynaecologic Dermatology* 3rd edition. Elsevier; 2008.

Author biography

Tarun Joseph Consultant

Rekha Kurian Consultant

Kurian Joseph Consultant

Sivashankari Consultant

Vasanthi Balamurugan Senior Resident

Cite this article: Joseph T, Kurian R, Joseph K, Sivashankari , Balamurugan V. Pemphigoid gestationis – A rare case report. *Indian J Obstet Gynecol Res* 2020;7(2):276-279.