



Case Report

Primary degenerated ovarian leiomyoma – A case report

Sendhil Coumary A^{1,*}, Moshina Basheer¹, Bhavani², Syed Habeebullah¹

¹Dept. of Obstetrics and Gynecology, Mahatma Gandhi Medical College and Research Institute, Pondicherry, India

²Dept. of Pathology, Mahatma Gandhi Medical College and Research Institute, Pondicherry, India



ARTICLE INFO

Article history:

Received 15-04-2020

Accepted 11-05-2020

Available online 12-09-2020

Keywords:

Ovarian leiomyoma

Degenerated

Solid ovarian mass

ABSTRACT

Ovarian leiomyomas are rare tumors seen in the reproductive age group. They are usually asymptomatic and diagnosed incidentally. Because of their solid nature, ovarian leiomyomas mimic malignant tumours. It needs to be distinguished from other solid tumors of the ovary like fibroma and thecoma. The origin of the tumour is still controversial. Here we present an ovarian leiomyoma with degenerative changes.

© 2020 Published by Innovative Publication. This is an open access article under the CC BY-NC license (<https://creativecommons.org/licenses/by-nc/4.0/>)

1. Case Report

A 24 year old lady, married for 3 months presented with irregular menstrual cycles for the last 3 cycles which was associated with heavy flow and dysmenorrhoea. Her previous cycles were regular with normal flow and no dysmenorrhoea. Patient also gave history of pain during micturition for the last 3 months. There was no history of dyspareunia. There was no history of any co-morbid factors.

On examination, she was of normal BMI and her vitals were stable. Abdomen examination revealed a suprapubic, firm to hard, non-tender midline mass of size 6 x 6 cm arising from the pelvis. On per speculum examination, cervix and vagina appeared healthy. Bimanual examination revealed a normal sized, retroverted uterus which was nontender. A hard, non-tender, globular mass of size 6x6 cm felt through the anterior fornix. There was no forniceal tenderness. A clinical diagnosis of a solid functional ovarian tumor was made.

Investigations revealed that her hemogram was normal. Her CA-125 was 14.42 U/L, CEA – 3.64 ng/mL, LDH – 209 U/L and AFP – 2.38 ng/ml. Ultrasound abdomen showed a left ovarian cyst of size 6.6 x 6.1 cm with areas of

calcification seen and right ovary could not be visualised. A provisional diagnosis of left ovarian dermoid cyst was made and planned for cystectomy.

Intra operatively, uterus was normal size. There was a left ovarian mass of size 6 x 7 cm, hard in consistency with the left fallopian tube adherent to it. Right ovary and tube were normal. There was no free fluid. The abdomen was systematically examined and found to have no deposits. Left salpingo oophorectomy was done. Cut section showed a solid yellowish mass with areas of calcifications (Figure 1). Sample was sent for histopathological examination.

Histopathological examination revealed tumor composed of ovarian stroma on the surface with underlying proliferation of smooth muscles arranged in interlacing fascicles, bundles surrounded by hyalinised myxoid and edematous stroma, few foci were showing osseous metaplasia. Attached ovarian tissue showed ovarian stroma with multiple follicular cyst. Tube showed normal histology. A diagnosis of ovarian leiomyoma with osseous, hyaline and myxoid change was made (Figures 2 and 3). Immunohistochemistry for smooth muscle actin to prove the presence of smooth muscle was done which was strongly positive.

* Corresponding author.

E-mail address: sendhilcoumary1975@yahoo.in (S. Coumary A).

Patient was followed up monthly for three months. She had resumed her regular monthly cyclicality and had no post-operative complications. She was discharged to a three monthly follow up.

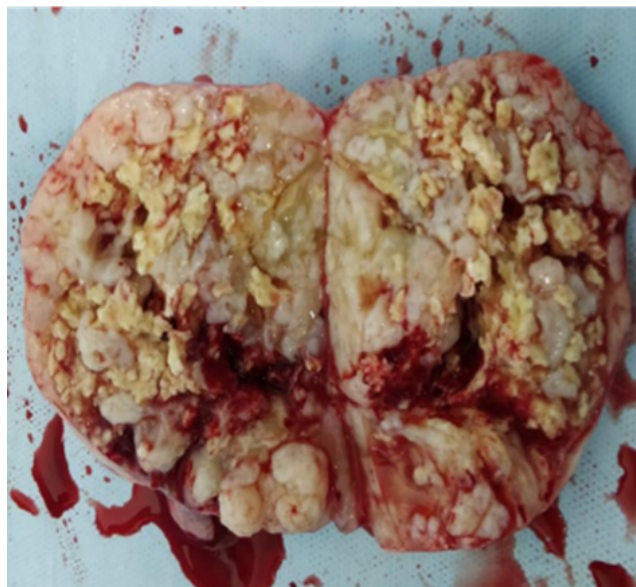


Fig. 1: Cut section of ovary showing areas of hyaline degeneration

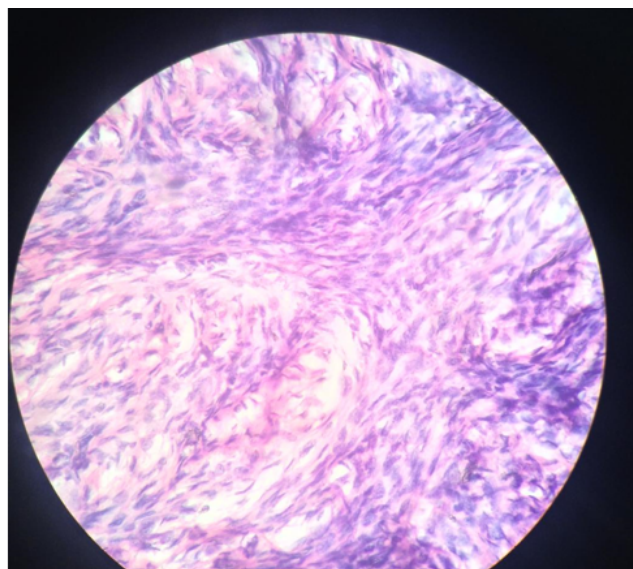


Fig. 2: Ovarian stroma on the surface with underlying proliferation of smooth muscles arranged in interlacing fascicles

2. Discussion

Uterine leiomyomas are the most common benign smooth muscle tumors of the female genital tract. 5-20% of women in the reproductive age group have leiomyomas.^{1,2} Primary ovarian leiomyoma is a very rare benign tumor accounting

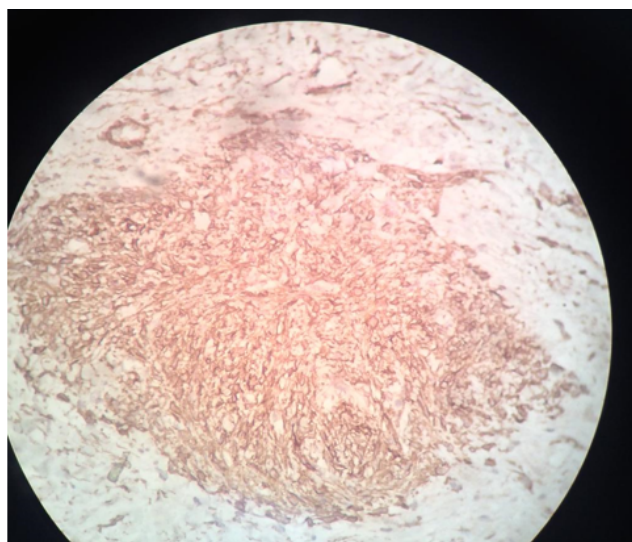


Fig. 3: Immunohistochemistry for smooth muscle actin is strongly positive

for less than 1 percent of all benign ovarian tumors. The first case of ovarian leiomyoma was described by Sangali in 1862.³ Most ovarian leiomyomas are associated with uterine leiomyomas.⁴ Around 78 percent of the ovarian leiomyomas were associated with uterine leiomyomas. Like uterine leiomyomas ovarian leiomyomas are common in premenopausal women.⁴ The exact incidence of ovarian leiomyoma is not known as it is usually misdiagnosed as fibroma.

Ovarian leiomyoma can be classified into 2 types: primary and secondary. Primary ovarian leiomyoma is mainly derived from ovarian tissues, and the vast majority of scholars have considered that it is derived from smooth muscle cells in the walls of ovarian vessels. Other theories have stated that it is derived from smooth muscle cells in the ovarian ligament, the smooth muscle cells in the ovarian stroma, the undifferentiated reproductive cells and cortical smooth muscle cells. Secondary ovarian leiomyoma arises from extra-ovarian tissues like the broad ligament or uterus and later attaches to the ovary.

The tumor usually causes no clinical symptoms and the discovery of lower abdominal masses during physical examination is incidental or even during an autopsy. Large masses may cause compression of the ureter may lead to hydronephrosis.⁴ Also the may be accompanied by pleural effusion and ascites, and elevated CA125 levels. The cause of ascites may be similar to the pathogenesis of Meigs syndrome.⁵ Furthermore, the tumor may cause acute abdomen if it undergoes torsion.

Pre-operative imaging and diagnosis is often very difficult due to the rare nature and variability of ovarian leiomyoma and the diagnosis mainly depends on postoperative pathology and immunohistochemistry.

Typical imaging methods include ultrasonography, computed tomography and magnetic resonance imaging. Ultrasonography suggests that these leiomyomas are similar to solid pelvic tumors, but which has an echo similar with the myometrium of the uterus. Therefore, it is difficult to distinguish an ovarian leiomyoma from a pedunculated subserous leiomyoma or a solid ovarian mass.

MRI is the main preoperative diagnostic method of ovarian leiomyoma.⁶ The tumors are usually well circumscribed with low signal intensity mass on T1 weighted imaging with mixed signal intensity on T2 weighted imaging. When MRI reveals solid ovarian tumors similar to uterine leiomyoma, ovarian leiomyoma should be considered. MRI can also help distinguish between benign and malignant tumors. In addition, some scholars have suggested that frozen section histology should be performed during laparoscopic surgery, in order to understand the nature of the tumor and determine the scope of the surgery. The tumor is generally solid, and may be accompanied by secondary damage such as hyaline degeneration, bleeding, calcification, and cystic degeneration.⁷ The pathology reported by mostly is similar to that of ordinary uterine leiomyoma. Myxoid degeneration is rare but has also been reported in ovarian leiomyomas.⁸ The present case showed three types of degeneration, hyaline, myxoid and calcareous degeneration making it a rare presentation.

Microscopically, the tumour needs to be differentiated from that of an ovarian fibroma which is comprised of bundles of spindle shaped cells with pointed nuclei and often exhibit storiform pattern rather than the fascicular pattern. Masson Trichrome helps to distinguish smooth muscle cells from fibrous tissue.⁹ Other differential diagnosis include a cellular thecoma which is usually comprised of lipid laden theca cells in a fibrous stroma, in which the tumour cells are stained with oil red O.

Immunohistochemistry is confirmatory in doubtful cases. Desmin, α -SMA (Alpha-Smooth Muscle Actin) and inhibin helps in differentiating leiomyomas from fibromatous tumour. Diffuse desmin positivity for tumour cells favours leiomyomas over fibromatous tumours, which are typically negative or may show focal positivity. SMA is often positive in both these tumours hence it is not helpful in differentiating the both. Thecomas are strongly positive for α -inhibin and does not express SMA. Leiomyoma also needs to be differentiated from the leiomyosarcoma by considering features such as mitotic activity, tumour necrosis and cytological atypia.

Surgery is the mainstay of treatment.¹⁰ An attempt to preserve the remanant ovarian tissue must be done especially in young patients. However in cases where the ovary is completely involved, oophorectomy is indicated

as in the present case. In situations where both the ovaries are involved, ovarian preservation should be attempted only after ruling out malignancy which is much more common than the ovarian leiomyoma, in which case, a frozen section will be essential.

3. Source of Funding

None.

4. Conflict of Interest

None.

References

1. Baird DD, Dunson DB, Hill MC, Cousins D, Schectman JM. High cumulative incidence of uterine leiomyoma in black and white women: Ultrasound evidence. *Am J Obstet Gynecol.* 2003;188(1):100–7.
2. Sparic R, Mirkovic L, Malvasi A, Tinelli A. Epidemiology of Uterine Myomas: A Review. *Int J Fertil Steril.* 2016;9(4):424–35.
3. Stewart EA, Cookson CL, Gandolfo RA, Schulze-Rath R. Epidemiology of uterine fibroids: A systematic review. 2017;doi:10.1111/1471-0528.14640.
4. Khaffaf N, Khaffaf H, Wuketich S. Giant ovarian leiomyoma as a rare cause of acute abdomen and hydronephrosis. *Obstet Gynecol.* 1996;87(5):872–3.
5. Kurai M, Shiozawa T, Noguchi H, Konishi I. Leiomyoma of the ovary presenting with Meigs' syndrome. *J Obstet Gynaecol Res.* 2005;31(3):257–62.
6. Tamada T, Sone T, Tanimoto D, Higashi H, Miyoshi H, Egashira N, et al. MRI appearance of primary giant ovarian leiomyoma in a hysterectomised woman. *Br J Radiol.* 2006;79(946):126–8.
7. Agrawal R, Kumar M, Agrawal L. Keshav Kumar Agrawal ; A huge primary ovarian leiomyoma with degenerative changes - an usual. *J Clin Diagn Res.* 2013;7(6):1152–4.
8. Moulla A, Magdy N, El-Bahrawy M. Ovarian leiomyoma with myxoid stroma. *Pathol.* 2017;109(4):389–91.
9. Doss BJ, Wanek SM, Jacques SM, Qureshi F, Ramirez NC, Lawrence WD. Ovarian leiomyomas: clinicopathologic features in fifteen cases. *Int J Gynecol Pathol.* 1999;18(1):63–8.
10. Kim M. Laparoscopic management of a twisted ovarian leiomyoma in a woman with 10 weeks' gestation: Case report and literature review. *Med (Baltimore).* 2016;95(44):5319.

Author biography

Sendhil Coumary A Professor

Moshina Basheer Post Graduate

Bhavani Associate Professor

Syed Habeebullah Professor and HOD

Cite this article: Coumary A S, Basheer M, Bhavani , Habeebullah S. Primary degenerated ovarian leiomyoma – A case report. *Indian J Obstet Gynecol Res* 2020;7(3):445-447.