



## Case Report

# A case series of ovarian ectopic pregnancy at a rural tertiary care hospital

Kratika Kamath<sup>1</sup>, Gomathy E<sup>1,\*</sup>

<sup>1</sup>Dept. of Obstetrics and Gynecology, Sri Devaraj Urs Medical College, Sri Devaraj Urs Academy of Higher Education and Research (SDUAHER), Kolar, Karnataka, India



### ARTICLE INFO

#### Article history:

Received 22-07-2020

Accepted 04-08-2020

Available online 07-12-2020

#### Keywords:

Ovarian ectopic pregnancy  
Intrauterine contraceptive device use  
Adnexal mass

### ABSTRACT

Ovarian ectopic pregnancy (OEP), is one of the variants of the non-tubal ectopic pregnancy, which varies one in 7,000–16,000 deliveries, and its prevalence is 1-3% among ectopic pregnancy.

OEP is a complication which occurs when implantation and embryo development happens outside of the uterus. Usually, 91% of OEP terminates with rupture before the end of 1<sup>st</sup> trimester and it can lead to pregnancy complications such as hemorrhage and hypovolemic shock. Clinical presentation of OEP is lower abdominal or pelvic pain, or both. In addition to this, other symptoms include nausea, vomiting, and constipation.

In this, we present 3 cases of OEP who reported to our hospital as adnexal mass for evaluation, who came with acute abdomen and was subsequently confirmed at surgery and proven on histopathology or USG detected adnexal mass with hemoperitoneum with suspicion of ectopic pregnancy. Judicious use of ultrasound in an appropriate clinical setting can thus prevent mishaps and enable better management of such conditions.

© This is an open access article distributed under the terms of the Creative Commons Attribution License (<https://creativecommons.org/licenses/by/4.0/>) which permits unrestricted use, distribution, and reproduction in any medium, provided the original author and source are credited.

## 1. Introduction

Ovarian ectopic pregnancy (OEP), is one of the variants of the non-tubal ectopic pregnancy, which varies one in 7,000–16,000 deliveries, and its prevalence is 1-3% among ectopic pregnancy. The incidence of OEP increases following the use of ovulation-inducing agents and also increased usage of assisted reproductive techniques and intrauterine device.<sup>1,2</sup>

OEP is a complication which occurs when implantation and embryo development happens outside of the uterus. When such ectopic pregnancy occurs in ovary, it is known as an OEP. The Spiegelberg criterion is used for diagnosing ovarian pregnancies. Usually, 91% of OEP terminates with rupture before the end of 1<sup>st</sup> trimester, 5.3% end in second trimester, and 3.7% end in the third trimester and it can lead to pregnancy complications such as hemorrhage and hypovolemic shock.<sup>3</sup> Clinical presentation of OEP is lower

abdominal or pelvic pain, or both. Pain being the common symptom and varies according the severity. In addition to this, other symptoms include nausea, vomiting, and constipation.<sup>4</sup>

The risk factors of OEP are history of intrauterine contraceptive device use (IUCD), pelvic inflammatory disease (PID), sexually transmitted infections (STIs), use of assisted reproductive technologies, prior pelvic surgery, endometriosis, previous ectopic pregnancy, advanced maternal age and multi-parity.<sup>5</sup> The pre-operative diagnosis of OEP is challenging, despite the enhanced modern sonographic techniques and is most often made at the time of surgery.

In this, we report here a series of 3 cases of ovarian ectopic pregnancy who reported to hospital as adnexal mass for evaluation, who came with acute abdomen and was subsequently confirmed at surgery and proven on histopathology or USG detected adnexal mass with hemoperitoneum with suspicion of ectopic pregnancy. Judicious use of ultrasound in an appropriate clinical setting

\* Corresponding author.

E-mail address: [egomathy5@gmail.com](mailto:egomathy5@gmail.com) (Gomathy E).

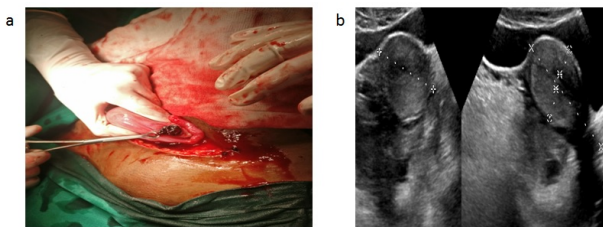
can thus prevent mishaps and enable better management of such conditions.

## 2. Case 1

A 28-year-old with history of previous LSCS came with complains of sudden onset pain abdomen, with no aggravating or relieving factors, associated with 2 episodes of vomiting to casualty. Clinically her vitals were stable. Her systemic examination was within normal limits. She had missed her regular periods for one month, and her urine pregnancy test was positive.

Ultrasound of her abdomen showed uterus of about 10-12 weeks size with endometrium was about 8 mm thick (Figures 1 and 2). No intrauterine or extrauterine gestational sac was seen.<sup>5,6</sup> For better visualization of the uterus, and adnexal TVS scan was performed. A normal left ovary was demonstrated. To our surprise, a large irregular heterogenous lesion of about 410cc was noted in right adnexa, extending up to the POD. The right ovary was not visualized separately from the lesion. Thus, in this clinical context, diagnosis of ruptured OEP was offered.

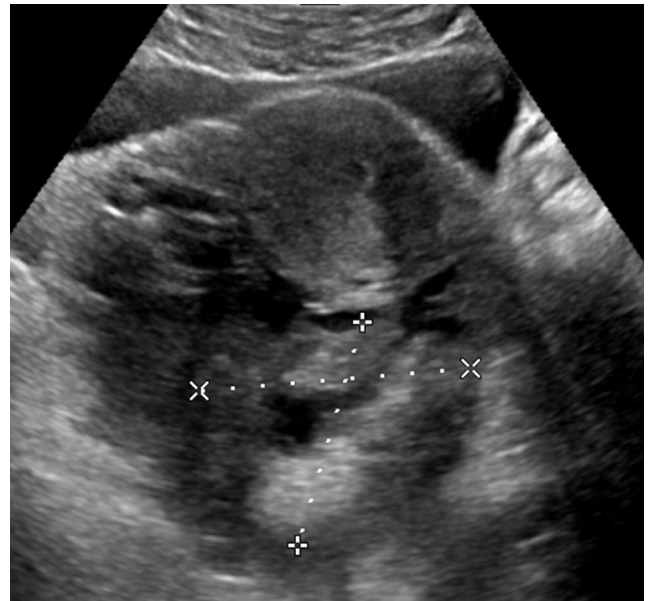The patient was planned for exploratory laparotomy, where right ruptured ectopic pregnancy was observed, and right salpingoophorectomy was done. Samples were sent to histopathological analysis, which demonstrated the presence of trophoblastic tissue with chorionic villi in the ovarian tissue and confirmed this to be a case of right ruptured ovarian ectopic pregnancy (Figure 3).



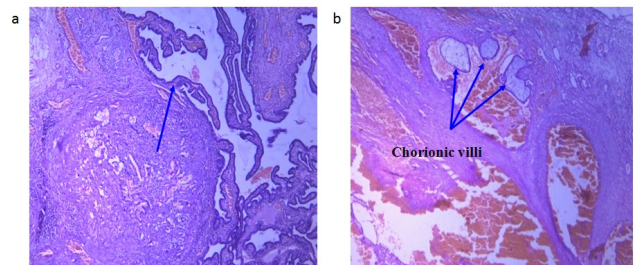
**Fig. 1:** (a):Intraoperative finding in an exploratory laparotomy. (b): USG grey scale images of pelvis show uterus are normal, endometrium measured ~ 8 mm. No evidence of sac/ decidual reaction in the endometrium. Right adnexa showed large irregular heterogenous lesion, extending to pouch of douglas

## 3. Case 2

A 29-year-old, with Copper T insitu came with complains of pain abdomen since 1 day, sudden in onset with history 4 episodes of vomiting. Clinically her vitals were stable. Her systemic examination was within normal limits. Her last menstrual cycle was 1 month back, with positive urine pregnancy test. On ultrasound abdomen, her uterus had copper T insitu, with collection in POD of about 170ml, likely clots, with right ovary visualized



**Fig. 2:** USG grey scale images of pelvis show uterus is normal, endometrium measured ~ 8 mm. No evidence of sac/ decidual reaction in the endometrium. Right adnexa showed large irregular heterogenous lesion ~ 10.1 x 9.3 x 8.2 (410 cc) with internal anechoic cystic areas extending to pouch of douglas (POD).



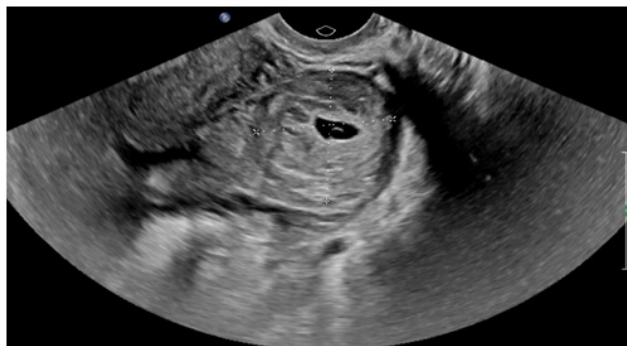**Fig. 3:** Histopathological examination of ovarian tissue (a): Demonstrated the presence of trophoblastic tissue; (b): Shows chorionic villi and confirmed this to be a case of right ruptured ovarian ectopic pregnancy

within the clot with adjacent focal hyperechoic collection-representing-sentinel clot sign. On exploratory laparotomy and proceed, intraoperatively, right ovary was found to have a bleeding point? Ruptured ectopic pregnancy was suspected. Moderate hemoperitoneum was found. Copper T was removed at the end of the procedure.

## 4. Case 3

A 20 year old, came with complains of pain abdomen since 1 day, sudden in onset with history 3episodes of vomiting. She also gave history of 1 and half months of amenorrhea and urine pregnancy test was found to be positive. On ultrasound abdomen, it was observed that round heterogenous lesion with central anechoic gestational

sac and yolk sac like structure in left adnexa which was well defined. The lesion showed increased surrounding vascularity giving a ring of fire appearance. Left ovary was not separately visualized (Figure 4).



**Fig. 4:** Shows a well-defined round heterogenous lesion with central anechoic gestational sac and yolk sac like structure in left adnexa

## 5. Discussion

OEP is an very rare form of ectopic pregnancies and it can be either primary or secondary to ruptured tubal pregnancy.<sup>6</sup> The mechanisms involved in the development of the OEP are fertilization which occurs normally and implantation in the ovary follows reflux of the conceptus from the tube and disturbances in the release of ovum may be responsible for the abnormal implantation.

However, the exact cause of OEP needs to be explored.<sup>7</sup>

It was reported that, reflux of the conceptus following a normal fertilization from the uterus, which is unable to free the ovum from ruptured follicle, with the changed tubal motility and inflammatory changes in tunica albugenia may be the cause for ovarian implantation. However, the clinical presentation of OEP is similar to other ectopic pregnancies such as mild-to-moderate pelvic pain, vaginal bleeding, abnormal  $\beta$ -hCG concentrations, and a palpable adnexal mass.<sup>8</sup>

Ghasemi Tehrani et al. in their case study of OEP in 30 year old parous women with 2 previous cesarean sections with pain abdomen for evaluation. During surgery, it was identified as ruptured OEP and HPR examination confirmed it to be an OEP.<sup>9</sup>

Ovulatory medication, ART, PID, IUCD, endometriosis are common risk factors which are associated with OEP, even without any antecedent risk factors it may occur. In our case series, we have not observed any of the associated risk factors from the given history. In this above cases, the patients presented with the classical triad of amenorrhoea, abdominal pain, bleeding PV. In addition to this, other conditions such as tubal ectopic, ruptured corpus luteal cyst leading to hemorrhage, ovarian torsion, or endometriosis in

the ovary leading to cyst can present in a similar fashion.<sup>10</sup>

OEP management usually done by surgical route, as most of the patients present to the hospital with the shock due to profuse bleeding, and diagnosis is usually made intraoperatively.

In most cases, partial oophorectomy or cystectomy is done, either by laparotomy or laparoscopy. Sometimes, oophorectomy may be necessary. The conservative treatment especially for unruptured OEP is methotrexate or prostaglandin therapy is still controversial.<sup>11</sup>

## 6. Conclusion

OEP is a rare form of ectopic pregnancy, but its incidence is certainly underestimated. Ovarian pregnancy typically shows a hyperechogenic white ring in the ovary in comparison to surrounding tissue, containing a yolk sac or fetal parts which is the key indicator in ultrasound; however an embryo is rarely seen. The closest differentials of ovarian pregnancy are a hemorrhagic ovarian cyst, a corpus luteal cyst, tubal ectopic pregnancy. But the clinical context often enables the differentiation. Maternal morbidity and mortality, however, depends on early diagnosis and definitive treatment of this condition.

## 7. Source of Funding

Nil.

## 8. Conflict of Interest

Nil.

## 9. Acknowledgement

We would like to thank the authorities of Sri Devaraj Urs Academy of Higher Education and Research (SDUAHER), Kolar, Karnataka, India for supporting this study.

## References

- Bontis J, Grimbizis G, Tarlatzis BC, Miliaras D, Bili H. Intrafollicular ovarian pregnancy after ovulation induction/intrauterine insemination: pathophysiological aspects and diagnostic problems. *Hum Reprod.* 1997;12(2):376–8. doi:10.1093/humrep/12.2.376.
- Kraemer B, Kraemer E, Guengoer E, Juhasz-Boess I, Solomayer E, Wallwiener D, et al. Ovarian ectopic pregnancy: diagnosis, treatment, correlation to Carnegie stage 16 and review based on a clinical case. *Fertil Steril.* 2009;92(1):392.e13. doi:10.1016/j.fertnstert.2009.04.014.
- Sotelo C. Ovarian Ectopic Pregnancy: A Clinical Analysis. *J Nurse Pract.* 2019;15(3):224–7. doi:10.1016/j.nurpra.2018.12.020.
- Itil IM, Ozcan O, Terek MC, Aygul S. Primary ovarian pregnancy: a case report and review of literature. *Ege Tip Dergisi.* 2004;43(2):113–5.
- Roy J, Babu AS. Ovarian pregnancy: Two case reports. *Australas Med J.* 2013;6(8):406–14.
- Valenzano M, Anserini P, Remorgida V, Brasca A, Centonze A, Costantini S. Transabdominal and Transvaginal Ultrasonographic Diagnosis of Ectopic Pregnancy: Clinical Implications. *Gynecol Obstet Invest.* 1991;31(1):8–11. doi:10.1159/000293092.

7. Zhu Q, Li C, Zhao WH, Yuan JJ, Yan M, Qin GJ, et al. Risk factors and clinical features of ovarian pregnancy: a case–control study. *BMJ Open*. 2014;4(12). doi:10.1136/bmjopen-2014-006447.
8. Kadau JV. Sonographic Detection of Ovarian Ectopic Pregnancy. *J Diagnostic Med Sonography*. 2016;32(5):299–3. doi:10.1177/8756479316663163.
9. Middleton WD, Kurtz AB, Hertzberg BS. *Ultrasound: The Requisites*. St Louis: Mosby; 2004.
10. Tehrani HG, Hamoush Z, Ghasemi M, Hashemi L. Ovarian ectopic pregnancy: A rare case. *Iran J Reprod Med*. 2014;12(4):281–4.
11. Siddiqua SF, Abbasi S, Rijvi S, Hasan AS. Ovarian Pregnancy- A Rare Case Report. *Anwer Khan Modern Med Coll J*. 2019;10(2):183–5. doi:10.3329/akmmcj.v10i2.44134.

### Author biography

**Kratika Kamath**, Post Graduate Student

**Gomathy E**, Professor

**Cite this article:** Kamath K, Gomathy E. A case series of ovarian ectopic pregnancy at a rural tertiary care hospital. *Indian J Obstet Gynecol Res* 2020;7(4):600-603.