



Case Report

Placental chorioangioma – An infrequent cause for polyhydramnios

Sajeetha Kumari R^{1,*}, Shubhashree Thiruselam¹, Prema Arumugam¹

¹Dept. of Obstetrics & Gynecology, SRM Medical College Hospital & Research Centre, Kanchipuram, Tamil Nadu, India



ARTICLE INFO

Article history:

Received 05-05-2019

Accepted 11-06-2020

Available online 07-12-2020

Keywords:

Chorioangioma

Placenta

Polyhydramnios

Tumour

ABSTRACT

Placental chorioangioma is the commonest tumour of the placenta arising from the vascular tissue. It is benign in nature. It is reported in about 0.5–1% of deliveries. Chorioangiomas, if large can affect both the mother and the fetus. We report a case where the mother presented with polyhydramnios with a chorioangioma arising from the placenta. Caesarean section was done for fetal distress. Many a times, placental chorioangioma is detected by routine antenatal scan before other clinical features sets in. In some situations, similar to ours, it may be detected only postnatally. Hence, antenatal ultrasound should mention the placental composition apart from the placental location. This would help in identifying chorioangioma enabling regular monitoring, timely intervention and delivery of such cases.

© This is an open access article distributed under the terms of the Creative Commons Attribution License (<https://creativecommons.org/licenses/by/4.0/>) which permits unrestricted use, distribution, and reproduction in any medium, provided the original author and source are credited.

1. Introduction

Placental abnormalities often lead to fetal distress. Placental insufficiency is identified as the commonest cause among them. Other rare placental causes which affect the fetus are partial mole, chorioangioma etc. Chorioangioma is the commonest tumor of the placenta which is non-trophoblastic in nature.¹

2. Case Report

A 25-year old 2nd gravida with a previous full term normal vaginal delivery presented to us in our antenatal clinic at 35 weeks of gestation. She was on irregular antenatal checkup from a local hospital where the routine antenatal investigations and anomaly scan were found to be normal. Her past medical and surgical history was not significant. There was no family history of any placental or fetal anomalies in the family. On examination her vitals were stable. On abdominal examination uterus was corresponding to 36 weeks gestation with increased liquor. The fetal parts were difficult to palpate because of polyhydramnios. Fetal

heart rate was good. Patient was admitted and evaluated for polyhydramnios. Admission NST was reassuring. All antenatal blood investigations including Oral Glucose Challenge Test was done and found to be normal. Patient was kept under observation with fetal surveillance. Injection Betamethasone was given for fetal lung maturity. Two days after admission she complained of reduced fetal movements. NST was non reassuring with fetal heart decelerations. Emergency caesarean section was done for fetal distress and a preterm female baby of weight 2.647 kg was delivered. Apgar was 8/10, 9/10. Liquor was found to be clear and increased. There was an enlarged placenta weighing 1.5 kg with a nodule of 6X5 cm on the fetal surface. (Figure 1). The placenta was sent for histopathological examination. Microscopy revealed features suggestive of placental chorioangioma with extensive degenerative changes (Figure 2). Postoperative period was uneventful. Both mother and baby were discharged on postoperative day 8 after suture removal.

3. Discussion

Placental chorioangioma is the commonest tumour of the placenta arising from the vascular tissue. It is benign in

* Corresponding author.

E-mail address: sajeethaprabhakar@gmail.com (S. Kumari R).

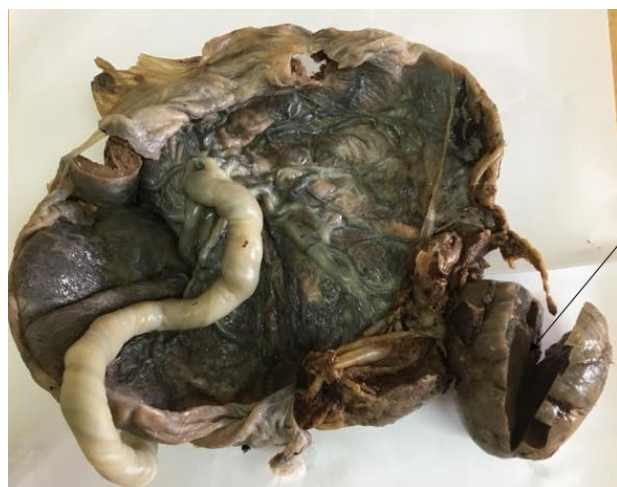

Fig. 1: Placenta and the cut chorioangioma

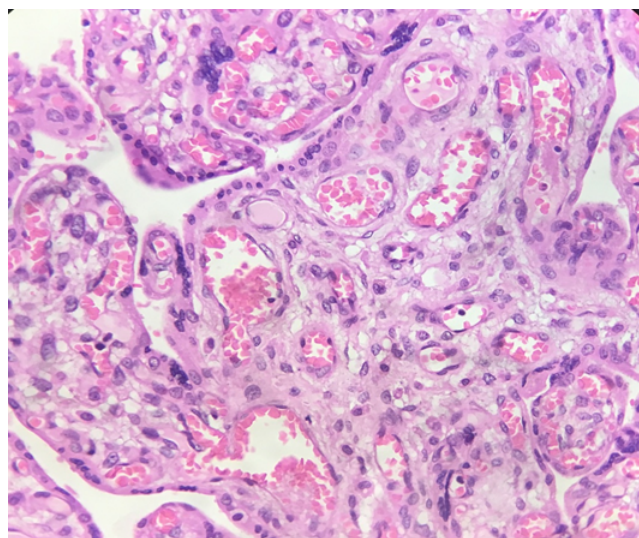


Fig. 2: Microscopy of the placental chorioangioma

nature.² It is reported in about 0.5–1% of deliveries and is commonly associated with elderly mothers, hypertension, diabetes, multiple pregnancies and female babies.^{3–5} It was first reported by Clarke in 1798.⁶ The exact pathology of chorioangioma is still not clear. It may be a malformation of the primitive angioblastic tissue of the placenta, usually on the fetal side of the placenta. There are many authors who refer it as a benign neoplasm while some consider it as a hamartoma.⁷ Marchetti has described three histopathological patterns– angiomatous, cellular and degenerate of which angiomatous is the most common. Microscopy shows numerous small areas of endothelial tissue, capillaries and blood vessels surrounded by placental stroma.^{8,9} Majority of placental chorioangiomas are asymptomatic unless they grow to large sizes. Many a times, placental chorioangioma is

detected by routine antenatal scan before other clinical features sets in. In some situations, similar to ours, it may be detected only postnatally.¹⁰ Usually it is seen near the umbilical cord insertion site and projects into the amniotic cavity. When they grow to size more than 4-5 cm, they can affect both mother and fetus. Maternal complications include polyhydramnios, preeclampsia, preterm delivery, placental abruption, malpresentations, postpartum hemorrhage etc.¹¹ Many theories have been put forth regarding the mechanism of polyhydramnios in placental chorioangioma. One which is commonly accepted is that the tumour near the umbilical cord insertion obstructs the blood flow thereby increasing the intravascular pressure. This may increase transudation into the amniotic cavity. Growth restriction, nonimmune hydrops, cardiac failure, microangiopathic hemolytic anemia and thrombocytopenia, fetal demise or neonatal death are some of the fetal complications.¹² Chorioangiomas of smaller size usually resolve spontaneously without causing any complications, but of larger size can undergo changes like necrosis, calcification, hyalinization or myxomatous degeneration. Chorioangiomas are usually detected by ultrasonogram. It is often seen as a mass near the chorionic plate with complex echogenicity, separate from the surrounding normal placental tissue.¹¹ The investigation of choice for placental chorioangioma is doppler ultrasound. Differential diagnosis for chorioangioma are placental teratoma, blood clot and leiomyoma.¹³ In doubtful cases, one may resort to magnetic resonance imaging. Computed tomography is not advisable during pregnancy because of radiation. Alpha-fetoprotein levels have been found to be raised in both serum and/or amniotic fluid, but it is not considered specific for placental chorioangioma.¹⁴

Usually, chorioangioma is managed conservatively. Asymptomatic tumours are serially monitored using ultrasound for early detection of complications. Monitoring with ultrasound is recommended every 6-8 weeks for small tumours and every 1-2 weeks for large tumours.¹⁵ If chorioangioma present with complications before the period of fetal viability, intervention is required. Indomethacin has been tried in case of polyhydramnios. Amnioreduction also helps in massive polyhydramnios.^{16,17} Steroids are indicated for fetal lung maturity before 34 weeks. Feeding vessels can be laser ablated or embolised with micro coils or glue materials like Enbucrilat. Alcohol injection into the tumour and endoscopic surgical devascularisation have also been reported.^{18–20}

There has been conflicting reports regarding its malignant potential. Even though some report that there are no malignant potential, rare cases of choriocarcinoma has been reported.^{11,21} This is especially seen in cases where atypical trophoblast with high mitotic activity was noted. Hence, maternal follow up is essential.

4. Conclusion

A routine antenatal ultrasound should include not only the placental location, but the placental composition as well to exclude chorioangiomas. Regular monitoring of such cases helps in timely intervention and fetal delivery.

5. Source of Funding

None.

6. Conflict of Interest

The author(s) declare(s) that there is no conflict of interest.

References

- Miliaras D, Anagnostou E, Papoulidis I, Miliara X. Non-trophoblastic tumor of the placenta with combined histologic features of chorangioma and leiomyoma. *Placenta*. 2011;32(1):102–4. doi:10.1016/j.placenta.2010.10.013.
- Vaidyanathan G, Bai A, Perchani J, Said HE, Lakhtakia R. Placental Chorioangioma: Usual Presentation and Alternate Treatment Options. *J Case Rep*. 2016;7(1):30–2. doi:10.17659/01.2017.0008.
- Amer HZM, Heller DS. Chorangioma and related vascular lesions of the placenta—a review. *Fetal Pediatr Pathol*. 2010;29(4):199–206. doi:10.3109/15513815.2010.487009.
- Guschmann M, Henrich W, Dudenhausen JW. Chorioangiomas – new insights into a well-known problem II. An immuno-histochemical investigation of 136 cases. *J Perinat Med*. 2003;31(2):170–5. doi:10.1515/jpm.2003.023.
- Hirata GI, Masaki DI, Toole O, Medearis M, Platt AL, D L. Color flow mapping and Doppler velocimetry in the diagnosis and management of a placental chorioangioma associated with nonimmune fetal hydrops. *Obstet Gynecol*. 1993;81(5):850–2.
- Jaffe R, Siegal A, Rat L, Bernheim J, Gruber A, Fejgin M. Placental chorioangiomas—a high risk pregnancy. *Postgrad Med J*. 1985;61(715):453–5. doi:10.1136/pgmj.61.715.453.
- Kuhnel P. Placental chorioangioma. *Acta Obstet Gynecol Scand*. 1933;13:143–5.
- Marchetti AA. A consideration of certain types of benign tumors of the placenta. *Surg, Gynecol Obstet*. 1939;68:733–43.
- Kirkpatrick AD, Podberesky DJ, Gray AE, McDermott JH. Placental Chorioangioma. *RadioGraphics*. 2007;27(4):1187–90. doi:10.1148/rg.274065207.
- Bashiri A, Furman B, Erez O, Wiznitzer A, Holcberg G, Mazor M. Twelve cases of placental chorioangioma. Pregnancy outcome and clinical significance. *Arch Gynecol Obstet*. 2002;266(1):53–5.
- Kodandapani S, Shreshta A, Ramkumar V, Rao L. Chorioangioma of Placenta: A Rare Placental Cause for Adverse Fetal Outcome. *Case Rep Obstet Gynecol*. 2012;2012:1–3. doi:10.1155/2012/913878.
- Fan M, Skupski DW. Placental chorioangioma: literature review. *J Perinat Med*. 2014;42(3):273–9. doi:10.1515/jpm-2013-0170.
- Bromley B, Benacerraf BR. Solid masses on the fetal surface of the placenta: differential diagnosis and clinical outcome. *J Ultrasound Med*. 1994;13(11):883–6. doi:10.7863/jum.1994.13.11.883.
- Abdalla N, Bachanek M, Trojanowski S, Cendrowski K, Sawicki W. Placental tumor (chorioangioma) as a cause of polyhydramnios: a case report. *Int J Womens Health*. 2014;p. 955. doi:10.2147/ijwh.s72178.
- Harris RD, Cho C, Wells WA. Sonography of the placenta with emphasis on pathological correlation. *Semin Ultrasound, CT MRI*. 1996;17(1):66–89. doi:10.1016/s0887-2171(96)90045-1.
- Hagen AKAP, Webb JB, Dona. Therapeutic amniocentesis in chorioangioma. *J Obstet Gynaecol*. 1997;17(2):169–70. doi:10.1080/01443619750113799.
- Indomethacin therapy in the treatment of polyhydramnios due to placental chorioangioma. *J Obstet Gynaecol Res*. 2001;27(5):245–3.
- Babic I, Tulbah M, Kurdi W. Antenatal embolization of a large placental chorioangioma: a case report. *J Med Case Rep*. 2012;6(1):183. doi:10.1186/1752-1947-6-183.
- Ercan CM, Coksuer H, Karasahin KE, Alanbay I, Baser I. Combined Approach in a Large Placental Chorioangioma Case with Intratumoral Alcohol Injection, Cordocentesis, IU Transfusion, and Amnioreduction. *Fetal Pediatr Pathol*. 2012;31(6):374–8. doi:10.3109/15513815.2012.659402.
- Mendez-Figueroa H, Papanna R, Popek EJ, Byrd RH, Goldaber K, Moise KJ, et al. Endoscopic laser coagulation following amnioreduction for the management of a large placental chorioangioma. *Prenatal Diagn*. 2009;29(13):1277–8. doi:10.1002/pd.2400.
- Faes T, Pecceu A, Calenbergh SV, Moerman P. Chorangiocarcinoma of the placenta: A case report and clinical review. *Placenta*. 2012;33(8):658–61. doi:10.1016/j.placenta.2012.04.012.

Author biography

Sajeetha Kumari R, Professor

Shubhashree Thiruselam, PG Student

Prema Arumugam, Professor

Cite this article: Kumari R S, Thiruselam S, Arumugam P. Placental chorioangioma – An infrequent cause for polyhydramnios. *Indian J Obstet Gynecol Res* 2020;7(4):611-613.