



## Case Report

# A case of fetus papyraceous in twin pregnancy

Manish R Pandya<sup>1,\*</sup>, Bhaumik G Shah<sup>1</sup>, Khushbu Patel<sup>1</sup>, Jeel Modesara<sup>1</sup>

<sup>1</sup>Dept. of Obstetrics & Gynecology, Scientific Research Institute Mahavir Hospital, Surendranagar, Gujarat, India



### ARTICLE INFO

#### Article history:

Received 30-11-2020

Accepted 03-12-2020

Available online 07-12-2020

#### Keywords:

Fetus Papyraceous

Fetus Compressus

Multiple Pregnancy

Intrauterine Death

### ABSTRACT

A case of fetus papyraceous (Fetus Compressus) found at delivery or Earlier by ultrasound examination of fetus describing dead fetus which is flattened, mummified and compressed between membranes of living fetus and uterine wall. It may occur in both varieties of twins, but more common in monozygotic twins.<sup>1</sup> This is the state which occurs if one of fetuses dies early. Fetus Papyraceous is a rare condition an associated with obstetric complications. Searching for a Fetus Papyraceous should be a routine part of placental examination.

© This is an open access article distributed under the terms of the Creative Commons Attribution License (<https://creativecommons.org/licenses/by/4.0/>) which permits unrestricted use, distribution, and reproduction in any medium, provided the original author and source are credited.

## 1. Introduction

Fetus Papyraceous or Fetus Compressus is the dead fetus which is mummified, flattened, compressed which remains in utero after death, it is parchment like remains of dead fetus.<sup>2</sup> It is partially or completely reabsorbs, therefore termed as 'vanishing twin' also.<sup>3</sup> It is dry and papery because the amniotic fluid, fluid content of dead fetal tissues gets absorbed. It is compressed and flattened between membranes of living fetus and uterine wall.<sup>4</sup> It may occur in both varieties of twins, but more common in monozygotic twins.<sup>1</sup> It is very rare condition. It's incidence reports as one in 12,000 pregnancies<sup>5</sup> and between 1:184 and 1:200 in twin pregnancies.<sup>6</sup> We present a case of twin pregnancy with the single live intrauterine normal fetus and with fetus papyraceous formation of other twin.

## 2. Case Presentation

A 21 years old gravida 3, abortion 2 came with complain of secondary infertility and past history of 2 missed abortions in 2 years. So we treated her for same cause and started ovulation induction by giving clomiphene citrate from 5<sup>th</sup>

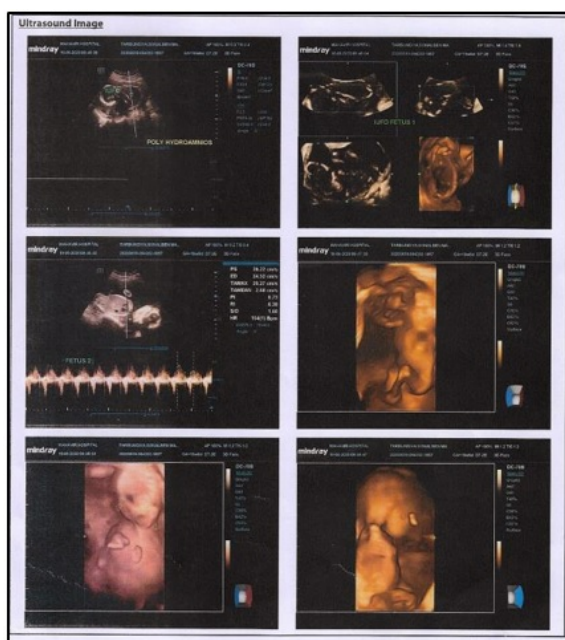
day of her last menstrual period (LMP) date. She was asked to come at 12<sup>th</sup> day of her LMP for USG, In USG there were presence of 3 large follicles on left ovary and 5 large follicles on right ovary. She came with complain of 1 month 3 days of amenorrhea, her LMP was 01/02/2020; on USG pregnancy was confirmed on 03/03/2020, then she was advised to come after 15 days for check-up. On 16/03/2020 USG was done which shows two intrauterine G sacs with two separate yolk sacs and two separate fetal poles, she was advised to visit regularly for check-up. In the early 2<sup>nd</sup> trimester, at 14 weeks of gestation, her USG report showed 14 weeks DCDA twin pregnancy, lamda sign seen, both fetuses are of same biometry with adequate liquor.

On 19/06/2020 in 2<sup>nd</sup> trimester, at 19 weeks of gestation, her USG report showed DCDA twin pregnancy; one live and active fetus of 19 weeks 6 days with polyhydramnios and other was dead with severe oligohydramnios. [Figure 1]

The patient and relatives were counselled regarding the condition and risks related with this condition were explained. Conservative management was done with sonography every three weeks. After diagnosis of IUFD baby, weekly Inj. Hydroxyprogesterone Caproate 250 mg given to prevent preterm labour till one week before delivery. She was in regular follow up. In 3<sup>rd</sup> trimester, at

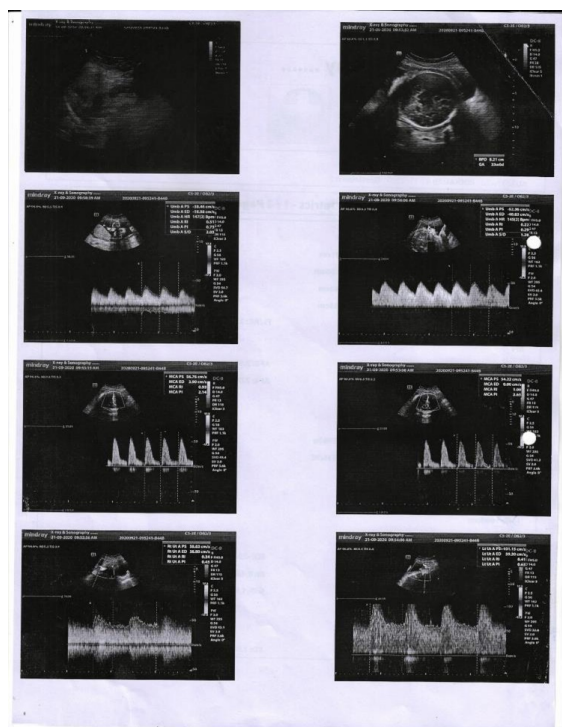
\* Corresponding author.

E-mail address: [drmanish.pandya@gmail.com](mailto:drmanish.pandya@gmail.com) (M. R. Pandya).



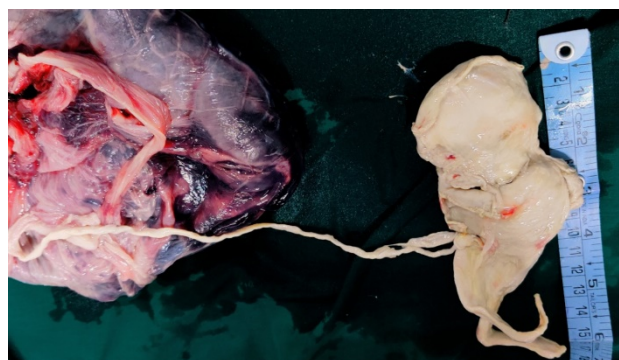
**Fig. 1:** USG 19 weeks

33 weeks of gestation, her USG report showed single viable intrauterine fetus with maturity of 33 weeks 2 days with adequate liquor with fetal heart rate of about 169/min and EFW is about 2.26 kg. [Figure 2]



**Fig. 2:** USG at 33 weeks

She presented with complain of lower abdominal pain; at the time of admission, General Physical Examination was normal. Obstetric examination showed fundal height corresponding to term gestation, single fetus with cephalic presentation with fetal heart rate of 152/min. Per vaginal examination done which showed cervical dilatation of 1 finger dilatation. Trial of labour was given but there was no further cervical dilatation seen indicating non progress of labour. Emergency caesarean section was performed; a live term female child of 2.670 kg was delivered. On examination of the placenta, two cords were noticed and it was identified as diamniotic dichorionic placenta with a fetus papyraceus with an attached single threaded like cord. The fetus papyraceus had a crown-rump length of 9.5 cm. [Figure 3].



**Fig. 3:** Fetus papyraceus

### 3. Discussion

Fetus papyraceus can occur in both monochorionic and dichorionic twin pregnancies, but more common in monochorionic twin pregnancy. Fetus papyraceus can be diagnosed early by imaging studies like ultrasonography during ante natal care visits,<sup>7,8</sup> but some patients never had an ultrasonography in her prenatal visits which may diagnosed intrapartum. In our patient, one intrauterine fetal death was diagnosed on 2<sup>nd</sup> trimester presented with severe oligohydroamnios and one live fetus with 19 weeks of maturity with polyhydroamnios. We tried for normal vaginal delivery but there was non progress of labour therefore we opted for caesarean operation.

Etiology of it remains largely unknown. Velamentous cord insertion; lethal nuchal cords are some of the factors causing fetus papyraceus. Maternal age, parity or gravidity has no association with this. Maternal complication can occur in some which includes maternal infection, unexplained postpartum haemorrhage (PPH). In second and third trimester severe complications such as preterm labour, haemorrhage, sepsis due to retention of dead fetus, consumptive coagulopathy, labour dystocia may present. These complications are more severe in monochorionic

than in dichorionic twins, In our case it was dichorionic gestation hence there was no such complication. Maternal consumptive coagulopathy due to retention of dead fetus has more theoretical value, although there may be transient rise in fibrin degradation products with hypofibrinogenemia, risk of clinically significant maternal coagulopathy in nil, as in our case. Live fetus also can be affected in some; complications may occur are as follows: prematurity, intrauterine growth retardation, even it may lead to death, death may occur in the second trimester in most of the cases.<sup>9</sup> Above mentioned complications may become severe when there is monochorionic placenta rather than dichorionic placenta.<sup>7</sup> Congenital anomalies can occur due to thrombi or other clotting factors which are released from dead fetus, which embolizes to live fetus to produce vascular occlusive lesions.<sup>10</sup> In case of monochorionic twin pregnancy, one fetal death may lead to perinatal mortality and neurological impairment risks to surviving live fetus.

With the help of ultrasonography its diagnosis we can make diagnosis early, which helps in close surveillance of fetus and mother.<sup>4,6</sup> Both monochorionic and dichorionic twin pregnancies must be monitored by Non stress test (NST) and Biophysical Profile (BPP) in case of single fetus demise. It could be possible, if we perform serial ultrasonography preferably every 2 to 3 weeks and also monitoring of coagulation profile every fortnight.

Systematic review by Ong et al of prognosis for co-twin showed the odds of IUD of co-twin, neurological abnormality and preterm labour among survivor as 6, 4 and 2 times higher in monochorionic as compared to dichorionic twins, in our case there was no such complication in surviving twin.<sup>11</sup>

Prognosis of surviving fetus in twin pregnancy depends on factors-No. Of fetuses, gestational age at time of death, cause of death, chorionicity, length of time between demise and delivery if surviving fetus. Prognosis is relatively better in dichorionic versus monochorionic twins.<sup>12</sup>

Legal importance of documenting the IUD of one of the fetuses for legal protection against allegation of malpractice and causing neurological damage to child during birth.

The management of such cases include following details like, information on chorionicity, sonographic evaluation of fetal anomalies and close fetal surveillance, Hydroxyprogesterone Caproate supplementation, steroid prophylaxis in case of preterm delivery, counselling and support, management in tertiary care centre with competent neonatal support.

#### 4. Conclusion

Fetus papyraceus' primary concern is the effects of its on surviving fetus and on mother. Serial ultrasonography examinations demonstrate the course of events, so it is mandatory for intrauterine diagnosis of fetus papyraceus

and for routine placental examination to search fetus papyraceus. The dead fetus may be associated with minor malformations of the surviving fetus. New-born's detailed check-up and histopathological examination of the placenta is essential after delivery of fetus papyraceus and living twin. Ultrasonography examination, haematological and biochemical monitoring of mother in antenatal period and also after delivery to assess for maternal infection and consumptive coagulopathy.

#### 5. Source of Funding

The authors declare that there is no conflict of interest.

#### 6. Conflict of Interest

None.

#### References

1. Dutta DC. DC Dutta's Textbook of Obstetrics. 9th ed.; 2018.
2. Landy HJ, Weiner S, Corson SL, Batzer FR, Bolognese RJ. The "vanishing twin": Ultrasonographic assessment of fetal disappearance in the first trimester. *Am J Obstet Gynecol.* 1986;155(1):14–19. doi:10.1016/0002-9378(86)90068-2.
3. Pelega D, Ferber A, Orvieto R, Bar-Hava I. Single intrauterine fetal death (fetus papyraceus) due to uterine trauma in a twin pregnancy. *Eur J Obstet Gynaecol Reprod Biol.* 1988;80:175–6.
4. Upadhyaya I, Pradhan M, Sharma R. Twin Pregnancy with Fetus Papyraceus. *J Nepal Med Assoc.* 2009;48(175):246–58. doi:10.31729/jnma.195.
5. Rathi BA, Rathi S. Fetus Papyraceous - a case report. *J Obstet Gynaecol India.* 2003;53:188.
6. Woo HH, Sin S, Tang LC. Single foetal death in twin pregnancies: review of the maternal and neonatal outcomes and management. *Hong Kong Med J.* 2000;6:293–300.
7. Dahiya P, Bains R. Conservative Management of Fetus Papyraceus: A Report of Two Cases. *Oman Med J.* 2014;29(2):132–4. doi:10.5001/omj.2014.32.
8. Sutkin G, Mamluk V. Fetus Papyraceus. *New Engl J Med.* 2004;350(16):1665. doi:10.1056/nejmicm020196.
9. Csecei K, Toth Z, Szeifert GT, Papp Z. Pathological consequences of the vanishing twin. *Acta Chir Hung.* 1988;29:173–82.
10. Daw E; Fetus papyraceus-11 cases. *Postgrad Med J.* 1983;59:598–600.
11. Ong SSC, Zamora J, Khan KS, Kilby MD. Prognosis for the co-twin following single-twin death: a systematic review. *Int J Obstet Gynaecol.* 2006;113(9):992–8. doi:10.1111/j.1471-0528.2006.01027.x.
12. Fusi L, Gordon H. Twin pregnancy complicated by single intrauterine death. Problems and outcome with conservative management. *Br J Obstet Gynaecol.* 1990;97(6):511–6.

#### Author biography

**Manish R Pandya**, Professor and HOD

**Bhaumik G Shah**, Assistant Professor

**Khushbu Patel**, Junior Resident

**Jeel Modesara**, Junior Resident

**Cite this article:** Pandya MR, Shah BG, Patel K, Modesara J. A case of fetus papyraceous in twin pregnancy. *Indian J Obstet Gynecol Res* 2020;7(4):619-622.