

## An Analysis of Efficacy of Uterine Artery Embolization in Obstetrics and Gynaecology - A study in a Rural Medical College & General Hospital

K GangadharaRao<sup>1</sup>, K Prabha Devi<sup>2</sup>, K Lakshminarayana<sup>3</sup>, K Ramalingam<sup>4</sup>,  
Biju Govind<sup>5</sup>, D Ankamma Rao<sup>6</sup>

<sup>1,3,4</sup>Professor, <sup>2</sup>Professor & HOD, Department of Obstetrics & Gynaecology,

<sup>5</sup>Professor, Department of Cardiology,

<sup>6</sup>Professor, Department of Radio Diagnosis,

NRI Medical College & General Hospital, Chinakakani Mangalagiri Mandal,  
Guntur District, Andhra Pradesh, India

**\*Corresponding Author:**

E-mail: profkgr@gmail.com

### Abstract

**Objectives:** To evaluate the success of uterine artery embolization (UAE) in Obstetric Hemorrhage and heavy menstrual bleeding with Gynaecological disorders.

**Methods:** Uterine artery is accessed by catheterizing femoral artery. First contra lateral and then ipsi lateral uterine artery is catheterized and embolization done with gel foam / poly vinyl alcohol (PVA)/ pellets/coils. All these patients with obstetric haemorrhage and Gynaecological cases with heavy menstrual bleeding, during the period January, 2008 to September, 2015 were included. Those patients with cancer, poorly controlled diabetes mellitus, with active infection, history of radiation, patients with renal disease, allergy to contrast media were excluded from this study.

**Results:** We performed 15 cases of uterine artery embolization out of which 5 cases were pseudo aneurysm (secondary PPH) of uterine artery. Mean age of the patient was 24 years and one case among them required hysterectomy. The other indications were cervical ectopic pregnancy (1), cervical molar pregnancy (1), Fibroids (6), AV malformations (2) of uterus.

**Conclusion:** Uterine artery embolization is very effective method to control haemorrhage and hysterectomy can be avoided to preserve fertility or in any other conditions.

**Key words:** Uterine artery embolization, Haemorrhage.

Access this article online	
Quick Response Code:	Website: www.innovativepublication.com
	DOI: 10.5958/2394-2754.2016.00012.6

### Introduction

Uterine artery embolization has been described over more than 20 years for controlling haemorrhage following delivery, abortion<sup>(1)</sup>, ectopic or cervical pregnancy, gestational trophoblastic disease, carcinoma cervix, fibroids<sup>(2,3)</sup>. It is not effective for adenomyosis cases.

In 1995 RAVINA et al<sup>(4)</sup> noted several women with symptoms with leiomyomata who underwent UAE as a pre hysterectomy treatment and had significant clinical improvement to an extent that hysterectomy was no longer used. McLucas and Goodwin and colleagues in Los Angeles published the first reports from the United States in 1996 and 1997<sup>(5,6)</sup>.

It is now estimated that more than 10,000 UAE procedures may have been performed so far for the treatment of fibroids. In 1979, brown et al reported first case of UAE for successful treatment for PPH

following failure of surgical methods. In 1990 - Lobel used UAE for cervical ectopic pregnancy.

### Aim of Study

To show the effect of UAE in controlling bleeding in fibroids, and post partum haemorrhage and cervical ectopic pregnancy.

### Materials and Methods

The patients with obstetric haemorrhage and gynaecological cases with heavy menstrual bleeding, during the period January, 2008 to September, 2015 were included. Those patients with pregnancy, cancer, poorly controlled diabetes mellitus, with active infection, history of radiation, patients with renal disease, coagulopathy, allergy to contrast media were excluded.

Secondary PPH cases due to Pseudo aneurysms were diagnosed by color doppler studies. Yin - Yang type of flow seen in the aneurysms with swirling of blood due to bidirectional flow. An anechoic area of 1-3cm size was present at incision line of uterus in 4 cases except in one case it was 5cm which required hysterectomy.

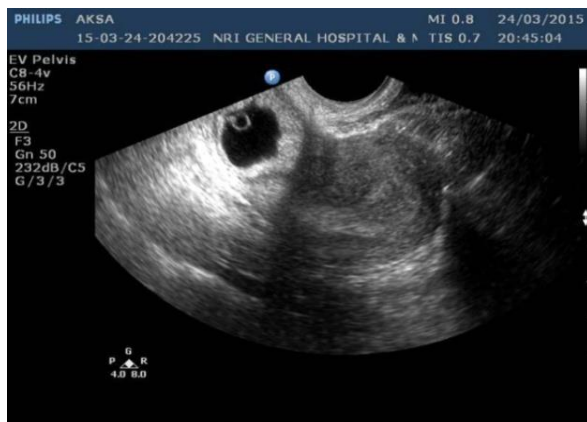
This procedure was done in our Hospital with an over night stay post procedure. Serum creatine was checked in every patient to prevent intravenous contrast related nephropathy. The patient was sedated during the procedure. The uterine arteries were most easily

accessed from the femoral artery. Initially a needle was used to enter the artery to provide access for the catheter. Local anaesthesia was used for analgesia. The catheter was advanced over the branch of the aorta and into the uterine artery on the side opposite the puncture.

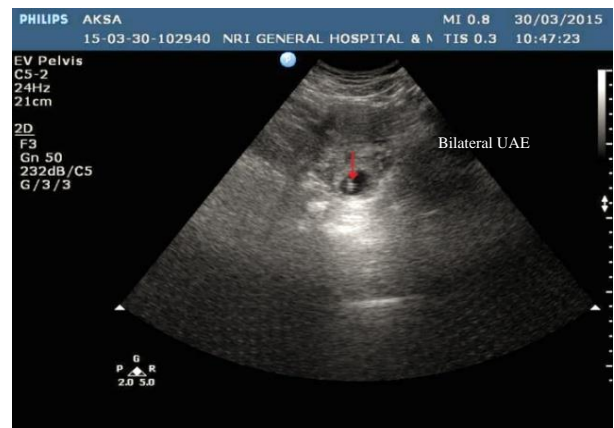
**Particles of PVA blocking UA**

The catheter angiogram was done through transfemoral approach with non ionic contrast medium, depending on the indication. In general PVA / gel foam/ coils were used for UAE. The particles of size of granules of sand go to fibroid feeding vessels first. The branches of the uterine arteries which were feeding to fibroids were blocked. The embolization procedure continued until the flow was blocked completely to the fibroids. Both uterine arteries were embolized to ensure the entire blood supply to the fibroids was blocked. After the procedure, check angiogram was taken. Arterial flow to other parts of uterus was there, but the flow to the fibroids was blocked with PVA. For pseudo aneurysm - coils / gel foam / coils + gel foam were used

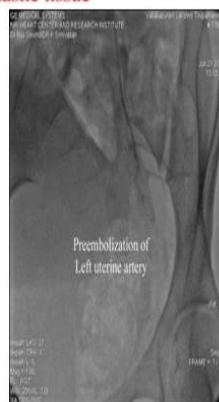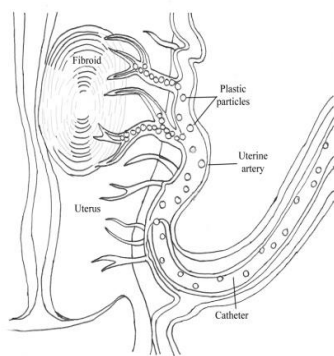
and for cervical ectopic, gel foam was used. The duration of procedure took nearly 1½-2 hours and then Particles of PVA blocking UA bleeding was stopped almost immediately except in one case which was ended with hysterectomy. Cervical ectopic pregnancy confirmed with transvaginal ultrasonography, β-hCG estimation, color Doppler, pulse wave Doppler. As the β-hCG values were very high (96,000iu), Injection Methotrexate 1mg/kg body weight IM, was given The β-hCG values instead of going down showed for the rise after 48 hours of Inj. Methotrexate, the vascularity of trophoblast was not decreased. So, the second injection of Methotrexate was given into the gestational sac under ultrasound guidance. Even then, the vascularity and β-hCG values not declined. Hence, Injection KCl given into the gestational sac under USG guidance. Again the vascularity of trophoblast was checked with color Doppler. Neither the vascularity nor hCG values decreased. Hence, this case was subjected for UAE.



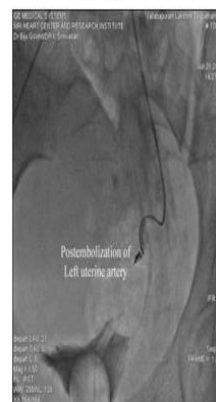
Gestational Sac With Yolk Sac FHS below internal OS with thick trophoblastic tissue



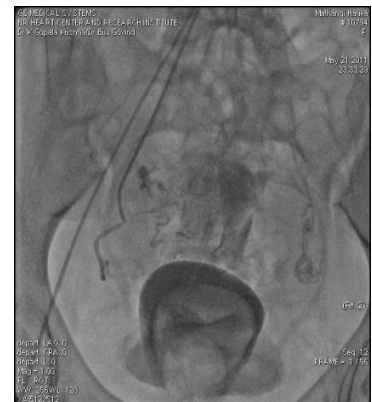Needle position at the time Inj Kcl into amniotic sac



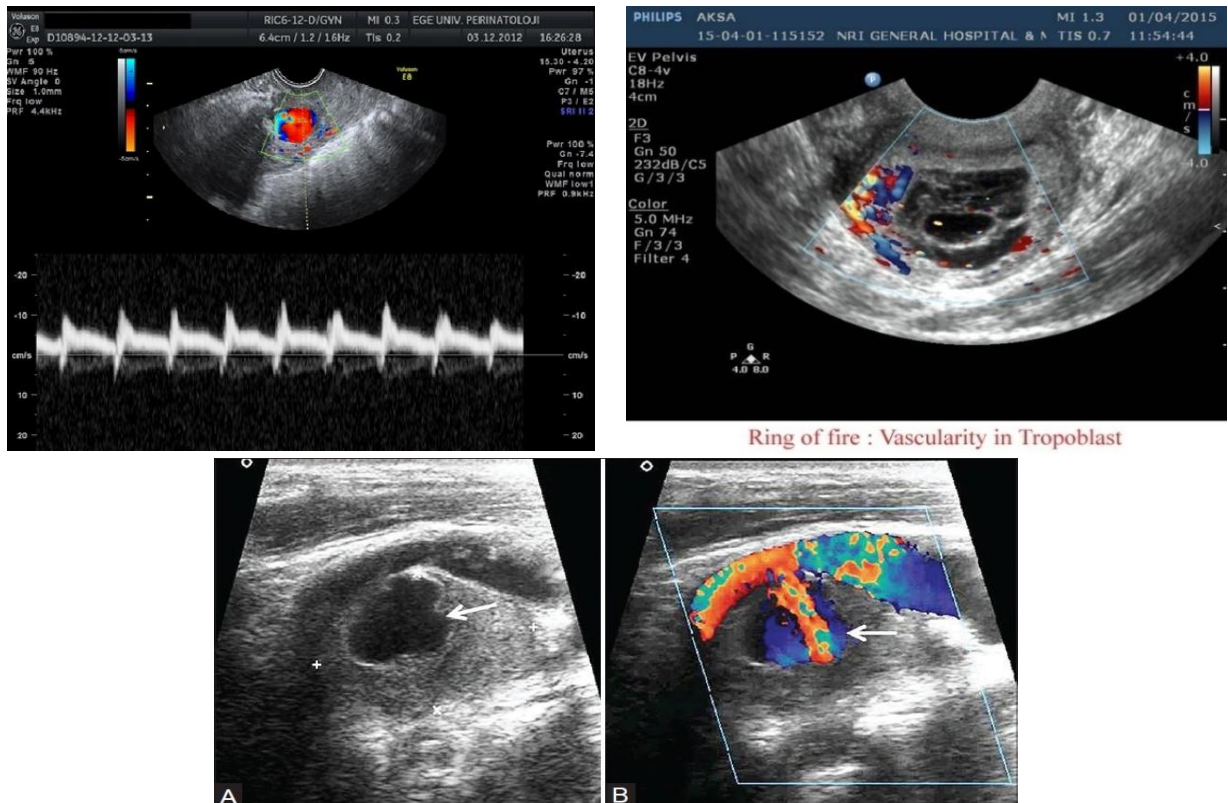
Preembolization of Left uterine artery



Postembolization of Left uterine artery



**Colordoppler study showed uterine pseudoaneurysm with yin –yang type of flow with spectrum.**



Ring of fire : Vascularity in Trophoblast

Colordoppler study showed uterine pseudoaneurysm with yin –yang type of flow.

**Results**

We treated secondary PPH due to pseudo aneurysm in 6 cases.

- Unilateral UAE – 4
- Bilateral – 1
- Uncontrolled PPH – emergency hysterectomy – 1 (without UAE)
- Note- UAE followed by emergency hysterectomy – 1
- UAE for cervical ectopic – 1
- Cervical hydatid mole – 1
- UAE for fibroids – 6
- AV malformations – 2

There were 6 cases of pseudo aneurysm of UA following lower segment caesarean section done outside. The onset of bleeding was from 3<sup>rd</sup> day to maximum 42 days. Number of bouts of bleeding average was 3-4. Most of the patients had massive haemorrhage. Average need of blood & blood products per each patient- 9 units. Out of six cases of pseudo aneurysm of uterine artery one case subjected direct emergency hysterectomy to save the life. The other one required hysterectomy even after UAE with 4 coils + gel foam.

The success rate following UAE in obstetric haemorrhage technically was 100% but clinically 87%. Among gynaecological cases clinical & technical success was 100%. (Technical Success – able to pass

catheter successfully).(Clinical Success – obviates need of hysterectomy)

**Fibroids:**

- Big fibroids
- >20wks size-2
- <10wks size – 4
- Heavy bleeding P/V – 5
- Infertility – 1

Post procedure evaluation was done by evaluation of signs and symptoms, pelvic USG & MRI, Pap smear, endometrial biopsy (EB), allergies and other medical problems if any.

**Post Procedure complications (UAE for fibroids):**

1. In 66% (4/6) Patients experienced pain abdomen and fever who responded to NSAIDS
2. Maximum stay in hospital was 4days average duration was 2 days for the same.

One case with infertility had regular follow up with multi modality approach, myomectomy, UAE, drugs (Mifepristone 50mg/weekly x 3 months). Then Uterus resumed to normal size even after 2 years with persistent amenorrhoea.

## Discussion

In a study by Suvranu Ganguli et al<sup>(7)</sup> an overall clinical success rate of UAE was 95% (98% for primary PPH, 88% for secondary PPH, and 94% for PPH associated with caesarean section) and an overall complication rate of 4.5%. Diagnosis of secondary PPH is best confirmed by ultrasonography, color Doppler and pulse wave Doppler, computed tomography, MRI, and later supported by angiogram. Pseudoaneurysm of UA and AV malformations of uterus (AV fistula) (Congenital or acquired) are best treated by UAE, described in 1979. One case required hysterectomy after UAE. The reasons for that was (1) inability to recognize the feeding vessels to the aneurysm of UA (Uterine Artery), (2) the size of the pseudo aneurysm >5 cm.

On review of literature, it was mentioned that the feeding vessels may be from ovarian artery, inferior epigastric artery or a branch from the opposite uterine artery. But, in our study one case, the feeding vessel was not identified by the angiogram.

**Fibroids:** with Hysterectomy an overall complication rate is 17% to 23%, and is unsuitable for patients wishing to remain fertile. There will be psychological effects of hysterectomy on women who undergo it. Myomectomy is done less frequently than hysterectomy because of certain disadvantages like bleeding, recurrence (5.7%-57%).

Investigators advised MRI before and after UAE procedure. Before UAE, use of MRI is to exclude adenomyosis and to know the size, site, number and volume of fibroids. After UAE procedure MRI is used to measure how much fibroid volume regressed at 3months and 1year period. In our study the volume reduction in fibroids varied between 27%-55% and there was no correlation between regression of symptoms and volume of fibroid.

As mentioned by some authors there were major complications (<1%), like bladder necrosis, rupture uterus. In our study, all our patients were parous-women, hence there was no question of infertility or rupture uterus during pregnancy. On post procedure (UAE) evaluation for fibroids, Overall, major complications typically occur in fewer than 4% of patients and minor complications occur in fewer than 23%<sup>(8)</sup>. Clinically, sloughing and expulsion of fibroids may be accompanied by abdominal pain and fever, particularly when secondary infection occurs<sup>(9)</sup>.

**Post-embolisation syndrome (PES):** It is one of the commonest side effects of transarterial embolisation (UAE) and its manifestations are fever, nausea/vomiting and pain. It usually occurs within the first 72 hours after embolisation (uterine fibroids) and then starts to subside after 72 hours. Infection should be suspected if the fever is of long duration and more than

104<sup>0</sup>F. This condition is more often associated with large fibroids after UAE.

**Radiographic Features:** Intra lesional gas (ultrasound or CT) following embolisation may be mistaken for abscess without additional factors. We found more than 30% of the cases suffered from fever, pain abdomen and responded to NSAIDS, Tremadal Inj (Narcotics) or combination of both. The other problems mentioned by Authors were radiation injury, pulmonary embolism, and necrosed fibroid tissue passage requiring intervention, sexual dysfunction and ovarian failure. one year follow up is required to identify any case of ovarian failure following UAE procedure.

**Treatment and Prognosis(PES):** Treatment is symptomatic relief; analgesia, IV fluids. It is normally self limited. Prophylactic use of antipyrexial and antiemetic therapy may be considered prior to embolisation of large tumors,

**Cervical Ectopic Pregnancy (CP):** In our study, the case presented not only with embryonic cardiac activity but also the characteristic peritropoblastic flow high peak systolic velocity and low impedance to flow.

The options for cervical pregnancy may be divided into five categories.

1. Tamponade with Foley's catheter
2. Reduction of blood supply: by cervical circlage, vaginal ligation of cervical arteries, by laparoscopic uterine artery & internal iliac ligation, and angiographic embolization of the cervical, uterine and internal iliac arteries.
3. Surgical excision of tropoblast: Curettage & Hysterectomy are the classic methods for surgical excision of tropoblast. With only curettage there will be always complication like haemorrhage. It has to be used in conjunction with medical or mechanical methods.
4. Intra amniotic feticide: Ultrasound guided intra amniotic instillation of potassium chloride / methotrexate has been used as a conservative approach of CP. Both these procedures require skill and expertise.
5. Systemic chemotherapy: The most commonly used agent is Methotrexate, used in a single dose or multiple doses, with or without folinic acid<sup>(10,11)</sup>. However, Methotrexate may be associated with bone marrow suppression, gastro intestinal disturbances and elevation of hepatic enzymes.
6. Combination methods:
  - I. Combination of medical and surgical methods.
  - II. Combination of laparoscopy assisted uterine artery ligation, followed by

hysteroscopic resection endocervically to remove CP has been described as fertility preserving alternative therapy<sup>(12)</sup>.

To start with we have done conservative treatment with Inj. Methotrexate IM followed by second dose Inj. Methotrexate in to the gestational sac. Even then, as cardiac activity was present, Inj. Potassium Chloride was given intra amniotically<sup>(13,14)</sup>. As fertility is important in this case we have planned to conserve the uterus by doing UAE to reduce the vascularity.

After UAE only, arterial supply was reduced, but venous flow was present (pulse wave Doppler study). Hence, we injected vasopressin into cervix<sup>(15)</sup> (Inj. Vasopressin is a potent vasoconstrictor to reduce the bleeding and also causes uterine contractions to expel the products of conception). Later suction evacuation (SE) was done. There was no bleeding following SE. Uterus was found empty after the procedure which was confirmed by check ultrasound.

**Cervical Ectopic (Molar):** In literature, there are only four cases recorded as molar cervical ectopic pregnancies. Out of 4, two cases partial mole and other two cases complete mole. Transvaginal ultrasound is the method of choice for establishing diagnosis early in the first trimester<sup>(16)</sup>. Diagnosis is based on a wide range of clinical, ultrasound and pathological criteria. The most widely accepted clinical criteria are those of Paalman and McElin<sup>(17)</sup> which stated that there must be profuse but painless vaginal bleeding in a woman with amenorrhoea, a softened and disproportionately enlarged cervix equal to or longer than the corporeal portion of the uterus, the presence of conception in the cervix, a closed internal os and a partially opened external os. Histopathological criteria for diagnosis requires the presence of chorionic villi within endocervical stroma. The attachment of placenta to the cervix must be intimate with the whole portion of placenta situated below the peritoneal reflection of the anterior and posterior surface of the uterus. Fetal elements must not be present in the corpus uteri. In our study one case was partial mole treated by UAE and suction evacuation. Post procedure, there was no bleeding and after 8 weeks follow up  $\beta$ -hCG decreased to normal ( $< 5$  mIU/ml).

**AV Malformations (AVM):** Durbreuil and Loubat reported the first case of uterine AVM in 1926. To date, there are fewer than 100 cases reported in the literature. AVM consists of proliferation of arterial and venous channels with fistula formation and a mixture of capillary like vessels. Distinction between arteries and veins is difficult because secondary intimal thickening occurs in the veins due to increased intra luminal pressure. Ultrasound can detect the presence of multiple tubular or "spongy" anechoic or hypoechoic areas within the myometrium of a normal endometrium.

Timmerman et al. presented 10 cases that demonstrated uterine AVM features by color Doppler US; of these, six cases spontaneously resolved<sup>(18)</sup>, causes include curettage and GTD. AVM persist in 10–15% of cases of GTD in remission after chemotherapy. The similar appearance may present in retained products of conception, hemangioma, multilocular ovarian cysts, or hydrosalpinx.

A normal myometrial signal will show a PSC of 9–44 cm/s and RI of 0.6–0.8. In addition, uterine AVM will exhibit intensely vascular and multidirectional flow (regions of juxtaposed reds and blues caused by multiple tortuous vessels of varying orientations). Spectral Doppler US will show high velocity (mean PSV: 136 cm/s), low resistance (mean RI: 0.3) flow, low pulsatility of the arterial waveform, and pulsatile high velocity venous waveform<sup>(4,5)</sup>. Differentiation between the venous and arterial waveform is often difficult, and the pelvic veins distal to the AVM may show pulsatile flow instead of the normal monophasic flow.

UAE was performed for uterine AV malformation in two cases. It was 100% success, as bleeding was completely stopped.

## Conclusion

Though hysterectomy is the final treatment to treat heavy menstrual bleeding for gynaecological indications and obstetric causes, we can think of UAE for conservative treatment of choice especially, whenever fertility is to be preserved. We should counsel the patients regarding long term and short term problems and other risks due to UAE.

**Conflict of Interest: None**

**Source of Support: Nil**

## References:

1. J Clin Imaging Sci. 2011;1:14. doi: 10.4103/2156-7514.76692. Epub 2011 Feb 11. Pseudoaneurysm of uterine artery: a rare cause of secondary postpartum hemorrhage, managed with uterine artery embolisation. Nanjundan P1, Rohilla M, Raveendran A, Jain V, Khandelwal N.
2. Oliver JA, Lance JS. Selective embolization to control massive hemorrhage following pelvic surgery. Am J Obstet Gynecol 1979;135:431–2.
3. Vedantham S, Goodwin SC, McLucas B, Mohr G. Uterine artery embolization: an underused method of controlling pelvic hemorrhage. Am J Obstet Gynecol 1997;176:938–48.
4. Ravina JH, Herbretreau D, Ciraru-Vigneron N, Bouret JM, Houdart E, Aymard A, et al. Arterial embolisation to treat uterine myomata. Lancet 1995;346:671–2.
5. Goodwin SC, McLucas B, Lee M, Chen G, Perrella R, Vedantham S, et al. Uterine artery embolization for the treatment of uterine leiomyomata: midterm results. J Vasc Interv Radiol 1999;10:1159–65. Semin Intervent Radiol. 2006 Jun; 23(2): 143–149.
6. Journal List Can Fam Physician. 53(2); 2007 Feb.
7. Uterine Artery Embolization in the Treatment of Postpartum Uterine Hemorrhage. Suvranu Ganguli, MD,



- Michael S. Stecker, MD, DeverajPyne, MD, Richard A. Baum, MD, and Chieh-Min Fan, MDJ VascIntervRadiol 2011; 22:169 –176 DOI: 10.1016/j.jvir.2010.09.031; J Reprod Med. 2005 Nov;50(11):844-50.
8. Semin Intervent Radiol. 2006 Jun; 23(2): 143–149; doi: 10.1055/s-2006-941444ss PMID: PMC3036365
  9. Complications in Interventional Radiology, Guest Editor Jonathan Lorenz M.D.; Complications of Uterine Fibroid Embolization, Brian E. Schirf, M.D.,<sup>1</sup> Robert L. Vogelzang, M.D.,<sup>1</sup> and Howard B. Chrisman, M.D., M.B.A.<sup>1</sup>
  10. Conservative management of cervical ectopic pregnancy, Usha Verma, M.D., Nima Goharkhay, M.D., DOI: <http://dx.doi.org/10.1016/j.fertnstert.2007.12.054>.
  11. Fertility and Sterility; Volume 91, Issue 3, March 2009, Pages 671–674, onservative management of cervical ectopic pregnancy, Usha Verma, M.D.<sup>a</sup>, Nima Goharkhay, M.D.
  12. Uterine artery embolization in the management of vaginal bleeding from cervical pregnancy: a case series. Trambert JJ1, Einstein MH, Banks E, Frost A, Goldberg GLAJR Am J Roentgenol. 2009 Jun;192(6):1601-7. doi: 10.2214/AJR.08.1921.
  13. Uterine artery embolization along with the administration of methotrexate for cervical ectopic pregnancy: technical and clinical outcomes. Hirakawa M1, Tajima T, Yoshimitsu K, Irie H, Ishigami K, Yahata H, Wake N, Honda H12; Mitra AG1, Harris-Owens M. Ultrasound Obstet Gynecol. 2005 Mar;25(3):282-8. Non-surgical management of live ectopic pregnancy with ultrasound-guided local injection: a case series.
  14. Monteagudo A1, Minior VK, Stephenson C, Monda S, Timor-Tritsch IE. ObstetGynecolSurv. 2000 Jun; 55(6): 385-9.
  15. Conservative medical management of advanced cervical ectopic pregnancies. . Bryman I, Norstrom A, Lindblom B. Influence of neurohypophyseal hormones on human cervical smooth muscle contractility in vitro. ObstetGynecol 1990;75:240 – 243.
  16. Ginsburg ES, Frates M, Rein MS, Fox JH, Hornstein MD, Friedman AJ. Early diagnosis and treatment of cervical pregnancy in an vitro fertilization program. FertilSteril 1994; 61: 5: 966-69.
  17. Timmerman D, Bosch TVd, Peeraer K. Vascular Malformations in the Uterus: Ultrasonographic Diagnosis and Conservative Management. *Euro J Obstet Gynaecol Reprod Biol.* 2000;92:171–178.[PubMed].