

Imperforate Hymen Presenting with Regular Menses... A diagnostic dilemma

Geetha V^{1,*}, Rohini G²

¹Assistant Professor, ²Professor & HOD,
Vinayaka Mission's Kirupananda Variyar Medical College & Hospitals, Salem, Tamilnadu, India.

***Corresponding author:**

E-mail: geetha_smc@yahoo.com

Abstract

Mullerian anomalies are rare and one among them is uterus didelphys with unilateral imperforate hymen associated with unilateral renal agenesis. A 15year old girl presented to our emergency department with urinary retention. On evaluation, she was diagnosed to have uterus didelphys with imperforate hymen on the right side leading to hematocolpos and hematometra on the right side causing urinary retention and also associated with unilateral renal agenesis. Patient was catheterised and urine from bladder drained. Excision of vaginal septum was performed and hematometra drained.

Key words: Uterus didelphys, Hematocolpos, Hematometra, Imperforate hymen, Renal agenesis.

Access this article online	
Quick Response Code:	Website: www.innovativepublication.com
	DOI: 10.5958/2394-2754.2016.00018.7

Obstructive anomalies result in retrograde menstruation due to collection of blood in the uterus and the vagina⁹. Early diagnosis and management of these rare conditions reduce long-term morbidity.^{10,11}

Case Report

A 15year old girl presented to our hospital with complaints of abdominal pain and inability to pass urine. Her menarche was 2 years ago with regular menstrual cycles. Her physical and general examination was normal. Abdominal examination revealed a suprapubic mass due to urinary retention. Bladder was catheterised and urine drained. Pelvic examination revealed imperforate hymen (Figure 1). Per rectal examination revealed a tense cystic swelling anteriorly and its upper margin was not made out. Abdominopelvic ultrasound examination suggested right renal agenesis with uterus didelphys. Vagina was seen with cystic mass of 4x9cm extending above to the right side of uterus.

Introduction

Mullerian anomaly varies between 0.1% to 3.8%¹. Incidence of uterus didelphys is estimated to be 5%² and imperforate hymen is 0.1%³. An imperforate hymen is a congenital resorptive defect which does not apparently derive from the Mullerian ducts⁴. Uterus didelphys with renal agenesis occurs from embryologic arrest at 8 weeks of gestation that simultaneously affects the adjacent Mullerian and metanephric ducts⁵. Complete obstructing hemivagina with longitudinal vaginal septum may be associated with uterine malformation and ipsilateral renal agenesis⁶⁻⁸.

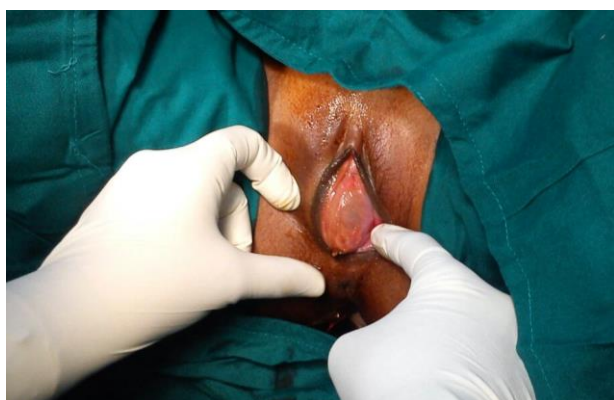


Figure 1: Imperforate hymen

Diagnosis of hematocolpos and hematometra was made, as she gave history of regular menses with imperforate hymen, uterus didelphys with obstructing hemivagina was highly suspected. Her laboratory results were within normal limits. Surgical intervention was decided to release the obstruction. Informed written consent was obtained from patient and parents. Preoperative antibiotic prophylaxis was given. Examination under anesthesia revealed longitudinal septate vagina with obstructed right hemivagina (Figure 2,3). Excision of vaginal septum was done using monopolar diathermy and collected blood was drained. Postoperative recovery was uneventful. Follow up ultrasound after one week showed uterus didelphys with complete clearance of hematocolpos and hematometra.

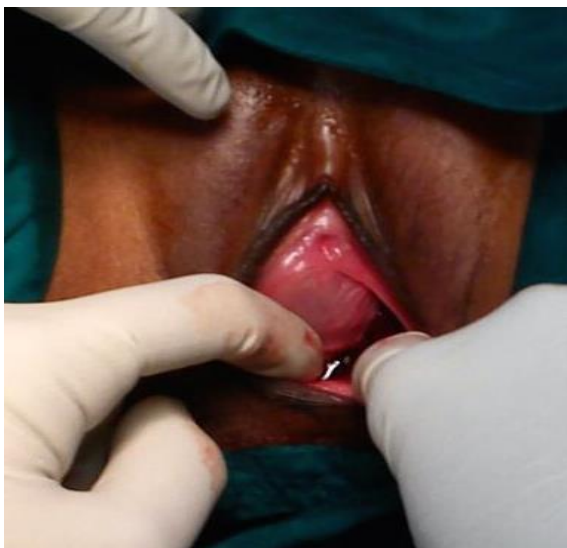


Figure 2: Obstructed right hemivagina

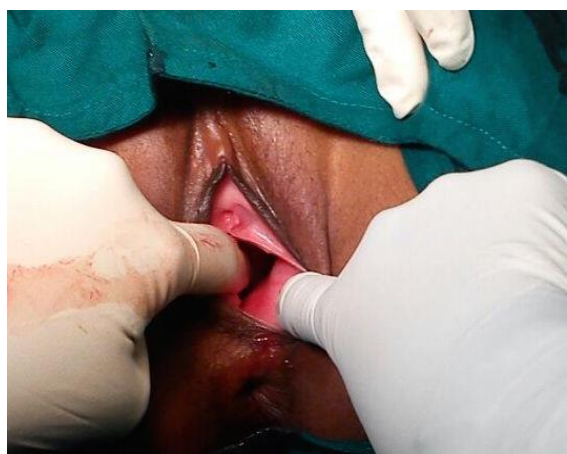


Fig. 3: Left hemivagina seen under anesthesia

Discussion

Uterus didelphys was first termed in 1925 by Wilson in a case with hematocolpos.¹² At 6 weeks of embryonic life müllerian duct fusion occurs in midline resulting in formation of uterus, cervix and upper 2/3 of vagina. If midline fusion fails, two separate uterine cavities and cervix formation occurs.¹ Metanephrogenic mesoderm and metanephric tubercle fail to develop if wolffian duct on one side is absent as they help müllerian duct to fuse. So development of kidney and collecting duct on the same side not occurs.^{13,14}

Müllerian duct anomalies present after puberty¹. Uterus didelphys with obstructed hemivagina should always be a differential diagnosis in a case with imperforate hymen and regular menstrual cycles. Early diagnosis and management to relieve obstruction prevent future morbidity.^{15,16} Imaging techniques like ultrasonography, hysterosalpingography and magnetic resonance imaging helps in diagnosis of uterus didelphys. Pelvic ultrasound is always preferred as the

initial diagnostic method¹. Resection of vaginal septum and draining of collected blood is the preferred management.¹⁷ Septum resection can be done with preservation of the hymen⁵. Fertility sparing surgery should always be preferred in management of müllerian anomalies¹.

Conclusion

Uterus didelphys with obstructed hemivagina should always be suspected in case of imperforate hymen presenting with regular menstrual cycles. These cases may be associated with unilateral renal agenesis. Early diagnosis and management is essential to preserve future fertility. Surgical management is the preferred first line therapy.

Conflict of Interest: None

Source of Support: Nil

References

1. Nesrin Atci, Kenan Serdar, Ayse Guler et al. A case of imperforated hymen in a regularly menstruating girl. *Journal of Cases in Obstetrics & Gynecology* 2015;2(3):56-58.
2. Fatum M, Rojansky N, Shushan A. Septate uterus with cervical duplication: rethinking the development of müllerian anomalies. *Gynecol Obstet Invest* 2003;55:186-88.
3. Attaran M, Falcone T, Gidwani G. Obstructive Müllerian anomalies. *Congenital Malformations of the Female Genital Tract. Diagnosis and management. Philadelphia: Lippincott Williams & Wilkins* 1999: 145-68.
4. Luigi Fedele, Giada Frontino, Francesca Motta, Elisa Restelli. A uterovaginal septum and imperforate hymen with a double pyocolpos. *Human Reproduction* 2012; Vol.27,(6): 1637-1639.
5. Kamal M. Zahran, Diaa Eldeen, Abd El Aal et al. Uterus didelphys with imperforate hemivagina and ipsilateral renal agenesis complicated by hematocolpos, hematometra and hematosalpinx. *The challenge of intact hymen. Middle East Fertility Society Journal* 2011; 16, 291-294.
6. Altintas A. Uterus didelphys with unilateral imperforate hemivagina and ipsilateral renal agenesis. *J Pediatr Adolesc Gynecol* 1998 Feb; 11: 25-7.
7. Kim TE, Lee GH, Choi YM, Jee BC, Ku SY, Suh CS et al. Hysteroscopic resection of the vaginal septum in uterus didelphys with obstructed hemivagina: a case report. *J Korean Med Sci* 2007; 22: 766-9.
8. Rock JA, Jones Jr. HW. The double uterus associated with an obstructed hemivagina and ipsilateral renal agenesis. *Am J Obstet Gynecol* 1980; 138: 339-42.
9. V DaCosta; L Christie; S Wynter; J Harriott; J Frederick. *Uterus bicornis bicollis*, imperforate hemivagina and ipsilateral renal agenesis case report and literature review. *West Indian med. j.* 2009; vol.58 (4),1-7.
10. Rock JA, Zacur HA, Dlugi AM, Jones HW Jr, TeLinde RW. Pregnancy success following surgical correction of imperforate hymen and complete transverse vaginal septum. *Obstet Gynecol* 1982; 59: 448-51.
11. Stassart JP, Nagel TC, Prem KA, Phipps WR. Uterus didelphys, obstructed hemivagina, and ipsilateral renal agenesis: the University of Minnesota experience. *Fertil*

- Steril 1992; 57: 756-61 .
12. Wilson JS: A case of double uterus and vagina with unilateral hematocolpos and hematometra. *J Obstet Gynecol Br Emp* 1925;32:127-128.
 13. Zurawin RK, Dietrich JE, Heard MJ, Edwards CL. Didelphic uterus and obstructed hemivagina with renalagenesis: case report and review of the literature. *Pediatr Adolesc Gynecol* 2004;17:137-41.
 14. Gyimadu A, Sayal B, Guven S, Gunalp GS. Hematocolpos causing severe urinary retention in an adolescent girl with imperforate hymen: an uncommon presentation. *Arch Gynecol Obstet* 2009;280:461-3.
 15. Raga F, Bauset C, Remohi J, Bonilla-Musoles F, Simon C, Pellicer A. Reproductive impact of congenital Mullerian anomalies. *Hum Reprod* 1997;12: 2277-81.
 16. Marcus S, al-Shawaf T, Brinsden P. The obstetric outcome of in vitro fertilization and embryo transfer in women with congenital uterine malformation. *Am J Obstet Gynecol* 1996;175:85-9.
 17. Altıntaş A. Uterus didelphys with unilateral imperforate hemivagina and ipsilateral renal agenesis. *J Pediatr Adolesc Gynecol* 1998;11:25-7.