

Content available at: <https://www.ipinnovative.com/open-access-journals>

Indian Journal of Obstetrics and Gynecology Research

Journal homepage: [www.ijogr.org](http://www.ijogr.org)

## Case Report

# Successful outcome of pregnancy with aplastic anaemia: A case report

Geetha<sup>1</sup>, K M Kundavi Shankar<sup>1</sup>, K Sofia Mercy<sup>1,\*</sup><sup>1</sup>Dept. of Reproductive Medicine, Institute of Reproductive Medicine, MMM, Chennai, Tamil Nadu, India

## ARTICLE INFO

### Article history:

Received 17-11-2021

Accepted 11-12-2021

Available online 14-02-2022

### Keywords:

Aplastic anaemia

Immunosuppressive therapy

Bone marrow depression in pregnancy

## ABSTRACT

Pregnancy in aplastic anaemia is rare and it may exacerbate bone marrow depression and cause deterioration, which can be life threatening for both mother and child. It poses a great challenge to the haematologist as well as obstetrician as the management of such cases challenges their skills in deciding the best treatment option for the patient. The first report of Aplastic anemia in Pregnancy was published by Ehrlich in 1888. Haemorrhage and sepsis due to pancytopenia are the main factors responsible for mortality in pregnant women with aplastic anemia. Treatment options are erythrocytes and platelet transfusions and immuno suppressive therapy. Immunosuppressive agents or hemopoietic stem cell transplantation are contraindicated during pregnancy. There is no universal agreement about the optimal treatment regime for this disorder in pregnancy, and supportive therapy remains the mainstay of therapy. The present case report describes our experience with a patient with aplastic anaemia, who was managed with intensive haematological support leading to delivery of a healthy baby.

This is an Open Access (OA) journal, and articles are distributed under the terms of the [Creative Commons Attribution-NonCommercial-ShareAlike 4.0 License](https://creativecommons.org/licenses/by-nc-sa/4.0/), which allows others to remix, tweak, and build upon the work non-commercially, as long as appropriate credit is given and the new creations are licensed under the identical terms.

For reprints contact: [reprint@ipinnovative.com](mailto:reprint@ipinnovative.com)

## 1. Introduction

Aplastic anaemia is a rare disease caused by destruction of pluripotent stem cells in bone marrow with an annual incidence of 2 to 6/10,00,000.<sup>1</sup> In contrast to the term 'aplastic anemia', suggesting suppression of erythropoietic cell lines, all cell lines may be affected.<sup>2</sup> Depending on affected cell lines, aplastic anaemia is associated with fatigue, bleeding due to thrombocytopenia and recurrent infections due to neutropenia.<sup>3</sup> The diagnosis 'aplastic anaemia' is confirmed by hypocellularity of the bone marrow. The remaining cells are morphologically unaffected without malignant infiltration. The first report of Aplastic anaemia in Pregnancy was published by Ehrlich in 1888. This patient was pregnant and died 1 month after delivery, due to postpartum hemorrhage.<sup>4</sup> Pregnancy associated aplastic anemia is rare but a life threatening

disorder. Haemorrhage and sepsis due to pancytopenia are the major reasons for death in pregnant women with aplastic anaemia. Immunosuppressive agents or hemopoietic stem cell transplantation are contraindicated during pregnancy. Supportive care remains the first line treatment for pregnant women. Since only a handful of cases been reported so far, there is no clear guidelines established for the management of aplastic anaemia during pregnancy. Mortality in aplastic anaemia associated with pregnancy is 20-60%. The outcome in pregnancy is generally good owing to the recent advances in the supportive therapy, and up to 39% will have successful pregnancies.<sup>5</sup>

### 1.1. Pathophysiology in Pregnancy

Pathophysiological mechanisms underlying the association between Aplastic Anaemia and pregnancy have not been clearly elucidated. It is known that estrogens increase plasma volume in pregnancy more than red-blood-cell

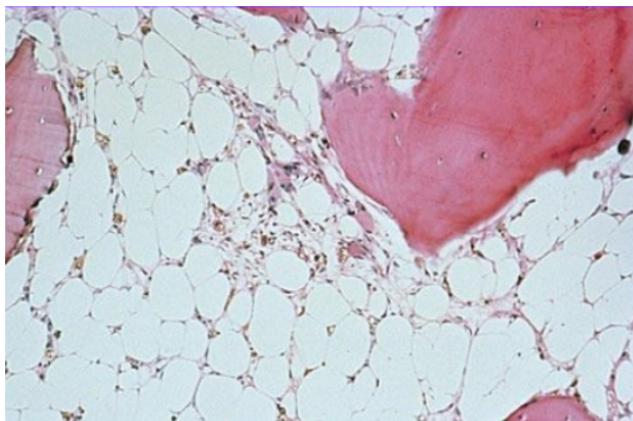
\* Corresponding author.

E-mail address: [drksfiamercy@gmail.com](mailto:drksfiamercy@gmail.com) (K. S. Mercy).

production, resulting in anemia of pregnancy. It has been postulated that hormonal influences may contribute to worsening of blood counts in pregnant patients with Aplastic anemia, but the exact mechanism and causes are still unclear.<sup>6,7</sup> Animal models have provided some insight into mechanisms for altered maturation and proliferation of blood cells in pregnancy.

## 2. Case Presentation

23 years old primi presented to our centre at 7 weeks and 4 days period of gestation, with history of recently diagnosed aplastic anemia. After around 3 months of marriage, the patient had developed severe urinary tract infection, associated with chills and rigor for which she was evaluated. Her routine laboratory tests showed pancytopenia wherein the Haemoglobin was 7 gm/dl, WBCs 3600 cells/dl, Platelets 37,000. Three units of Packed Red blood cells were transfused and hematologist opinion was obtained. Iron, Ferritin & TIBC were found to be normal. Bone marrow biopsy showed hypocellular bone marrow, Dyserythropoiesis & absent iron storage. A bone marrow biopsy confirmed the diagnosis of aplastic anemia. Patient had regular antenatal checkups, NT scan, First trimester screening, Anomaly Scan and serial growth scans were all found to be normal throughout. Her pregnancy was managed with a multidisciplinary approach. Myelodysplastic syndrome panel by FISH was Normal. Chromosomal analysis showed Normal female karyotype 46XX. Hematologist advised blood count every 2 weeks, 2 units of packed red blood cells transfusion if Haemoglobin < 8 gm/dl, 4 units of platelets when Platelet count < 20,000. According to the Hematologist's advice, patient was managed accordingly.



**Fig. 1:** BM Biopsy –Hypocellular, increased fat spaces

According to hematologist advise patient was transfused with PRBC and platelets to maintain Haemoglobin > 8 gm/dl, platelet > 20,000 to prevent the serious consequences of thrombocytopenia and anaemia in the mother and fetus.

Decision for elective delivery by caesarean was planned at 35 weeks + 3 days of gestation. Antenatal steroids were given for fetal lung maturity. Patient was transfused with 4 units of random donor platelets & 1 unit of PRBC prior to delivery. Platelet refractoriness was checked. Platelets after one hour -80,000. Patient did not have platelet refractoriness. Post transfusion Haemoglobin was 9.9 gm/dl and platelet - 70,000. Elective lower segment caesarean section was done at 35 weeks and 5 days with 4 units of platelets on flow under antibiotic coverage. An alive male baby weighing 2.470 kgs was born with good APGAR SCORE. There as no PPH. Histopathology of placenta showed Umbilical cord with Three blood vessel and placenta had congestion. Intraoperative and post operative period were uneventful.

Patient was discharged on 4<sup>th</sup> Post operative day with Haemoglobin of 9 gm /dl and platelets – 100,000 in stable condition.

## 3. Discussion

Little research has been published about therapy for aplastic anemia during pregnancy. In fact, only case reports and series with small sample sizes are available. The annual incidence of aplastic anemia is 2 to 6 per million population per year. In some parts of Asia, the incidence is higher. It is believed that the increased incidence of aplastic anemia in Asia is due to exposure to toxic substances rather than genetic disorder. Although rarely encountered during pregnancy, it may exacerbate bone marrow depression and cause deterioration. Hence aplastic anemia is a grave complication. The relation between the pregnancy and aplastic anemia is still unclear. Causes include drugs and other chemicals, infections, irradiation, leukaemia, immunological disorders, and inherited conditions such as Fanconi anaemia and Diamond-Blackfan syndrome.<sup>8,9</sup> Bone marrow transplantation (BMT) has been reported to be the most effective treatment, with a 5-year survival of 56-89%.<sup>1</sup> However, BMT is contraindicated during pregnancy because it requires high-doses of immunosuppressive agents or radiation therapy, which would be toxic to the fetus.<sup>10</sup> But there are several case reports of successful pregnancies in women who had undergone bone marrow transplantation.<sup>11</sup> There is no universal agreement over the optimal management of aplastic anaemia in pregnancy.

The maternal complications of aplastic anaemia in pregnancy are haemorrhage and infection and foetal complications are growth restriction and even intrauterine death. Other antenatal complications that occur due to placental vascular etiologies are abortion, preeclampsia, still birth and preterm birth.<sup>12</sup> Fortunately our patient didn't develop any of these complications we did not encounter haemorrhage either during caesarean or in the postpartum period. Earlier case reports in 1989 by Aitchison et al proposed termination of pregnancy in the

**Table 1:** Haematological profile

Date	GA	Hb	Platelet	WBC	Blood transfusion
3/12/2019	7+4 weeks	12.7	37000		
20/12/2019	10weeks	10.6	45000	3840	
02/01/2020	12wks	9.1	58000	2670	
14/01/2020	13+3wks	7.1	60000	4000	2 PRBC
05/02/2020	16+4wks	7.7	50000	3900	2 PRBC
19/02/2020	18+4wks	8.3	50000	3800	
28/02/2020	19+6wks	6.8	50000	4000	2 PRBC
29/03/2020	23wks	6.7	38000	4500	2 PRBC
08/04/2020	25+4wks	7.5	26000	4200	1 PRBC
15/04/2020	26+4wks	7.2			1 PRBC
27/04/2020	28+2wks	6.5	30000	3900	2 PRBc
28/5/2020	32+3wks	9	40000		

**Table 2:** Post operative period profile

POD	Hb	Platelet	TC
POD - 0	9.9	1,00,000	7100
POD - 1	9.0	1,00,000	5700
POD - 2	8.9	1,00,000	6200
POD- 3	9.2	1,00,000	5500

first trimester for patients with aplastic anemia.<sup>10</sup> But now, supportive measures are improving with the availability of better transfusion services and hence pregnancies should be maintained as long as the health of the mother is not seriously affected. Good supportive care and blood transfusion resulted in Successful outcome of our patient and literature supports this. The benefit of transfusions to prevent bleeding should be weighed against the likelihood of developing HLA antibodies and hemochromatosis in the mother.<sup>13</sup> Perhaps the mainstay of the management of aplastic anaemia in pregnancy is supportive therapy with blood and blood products.<sup>14</sup> If the patient does not respond sufficiently then antithymocyte immunoglobulin, cyclosporine and steroids should be started.<sup>15,16</sup>

Maintaining adequate hemoglobin level of more than 8 g/dl and platelet count more than 20,000/cmm is necessary. Prophylactic measures like Prophylactic platelet transfusion analgesics and antibiotic coverage should be ensure during delivery. Assisted second stage of labour in cases of vaginal delivery and avoiding perineal infection in post partum period will result in good prognosis. At present, It is possible to have a successful outcome in moderately severe aplastic anaemia and severe thrombocytopenia through pregnancy with recent advances in supportive care and blood transfusion.

#### 4. Conclusion

Aplastic anaemia is a serious condition which may manifest during pregnancy. The seriousness depends on the degree of bone marrow suppression. Most pregnant patients will have full-term pregnancies with a healthy child with supportive care. Fortunately, aplastic anaemia

has a low mortality due to treatment. We cannot draw any conclusions regarding the optimal therapies other than supportive therapy for patients with aplastic anaemia in pregnancy depending on few case reports. A multidisciplinary - team approach to the management of aplastic anemia in pregnancy involving the obstetrician, the hematologist, Anaesthetist and neonatologist is necessary to Coordinate antenatal care, Optimize maternofetal outcomes & Plan peripartum interventions. This case report shows that with good supportive care and blood transfusion we can achieve successful outcome in our pregnant women with aplastic anemia.

#### 5. Source of Funding

None.

#### 6. Conflict of Interest

The authors declare no conflict of interest.

#### References

1. Young NS. Acquired aplastic anemia. *Ann Intern Med.* 2002;136:534–46.
2. Tichelli A, Socie G, Marsh J, Barge R, Frickhofen N, McCann S, et al. Outcome of pregnancy and disease course among women with aplastic anemia treated with immunosuppression. *Ann Intern Med.* 2002;137(3):164–72.
3. Snyder TE, Lee LP, Lynch S. Pregnancy-associated hypoplastic anemia: a review. *Obstet Gynecol Surv.* 1991;46(5):264–9.
4. Ehrlich P. Über einen Fall von Anämie mit Bemerkungen über regenerative Veränderungen des Knochenmarks. *Charite Ann.* 1888;13:300–5.
5. Kuispel JW, Lynch VA, Vicle ED. Aplastic anemia in pregnancy a case report, review of literature and a re-evaluation of management. *Obstet*

- Gynecol Surv.* 1976;31(7):523–8.
6. Brewer CA, Adelson MD, Elder RC. Erythrocytosis associated with a placental-site trophoblastic tumor. *Obstet Gynecol.* 1992;79(5):846–9.
  7. Jepsen JH, Lowenstein L. Role of erythropoietin and placental lactogen in the control of erythropoiesis during pregnancy. *Can J Physiol Pharmacol.* 1968;46(4):573–6.
  8. Green AM, Kupfer GM. Fanconi anemia. *Hematol Oncol Clin North Am.* 2009;23(2):193.
  9. Lipton JM, Ellis SR. Diamond-Blackfan anemia: Diagnosis, treatment, and molecular pathogenesis. *Hematol Oncol Clin North Am.* 2009;23(2):261.
  10. Aitchison RG, Marsh JC, Hows JM, Russell NH, Gordon-Smith EC. Pregnancy associated aplastic anaemia: a report of five cases and review of current management. *Br J Haematol.* 1989;73(4):541–5.
  11. Moise KJ. Umbilical cord stem cells. *Obstet Gynecol.* 2005;106:1393.
  12. Faivre L, Meerpohl J, Costa D, L. High-risk pregnancies in Diamond-Blackfan anemia: A survey of 64 pregnancies from the French and German registries. *Haematologica.* 2006;91.
  13. Ascarelli MH, Emerson ES, Bigelow CL, Martin JN. Aplastic anemia and immune-mediated thrombocytopenia: concurrent complications encountered in the third trimester of pregnancy. *Obstet Gynecol.* 1998;91(5 Pt 2):803–6.
  14. Kwon JY, Lee Y, Shin JC, Lee JW, Rha JG, Kim SP, et al. Supportive management of pregnancy-associated aplastic anemia. *Int J Gynaecol Obstet.* 2006;95(2):115–20.
  15. Stibbe KJM, Wildschut HJJ, Lugtenburg P. Management of Aplastic anemia in a woman during pregnancy: a case report. *J Med Case Rep.* 2011;5:66. doi:10.1186/1752-1947-5-66.
  16. Yilmaz E. Aplastic Anemia and Pregnancy: Case Report. *Perinatal Journal.* 2007;15(1).

### Author biography

**Geetha**, Consultant

**K M Kundavi Shankar**, HOD

**K Sofia Mercy**, Fellow

**Cite this article:** Geetha, Shankar KMK, Mercy KS. Successful outcome of pregnancy with aplastic anaemia: A case report. *Indian J Obstet Gynecol Res* 2022;9(1):114-117.