

Content available at: <https://www.ipinnovative.com/open-access-journals>

Indian Journal of Obstetrics and Gynecology Research

Journal homepage: www.ijogr.org

Case Report

Spontaneous unscarred uterine rupture at 34⁺⁶ weeks of gestation in a primigravid women: A case report

Nhat Quang Ho^{1,*}, Anh Dinh Bao Vuong¹, Thanh Quang Le¹

¹Dept. of Obstetrics, Tu Du Hospital, Ho Chi Minh, Vietnam



ARTICLE INFO

Article history:

Received 09-09-2021

Accepted 16-10-2021

Available online 14-02-2022

Keywords:

Uterine rupture

Primigravid

Unscarred uterus

ABSTRACT

Objective: Spontaneous unscarred uterine rupture (SUUR) is a catastrophic obstetric complication. We presented a case of the woman at 34⁺⁶ weeks of gestation without apparent causes of SUUR.

Case Presentation: A 28-year-old primigravid woman in her third trimester came to the hospital because of abdominal pain. She had a history of endoscopic surgery for adhesiolysis of bilateral fallopian tubes and untreated thyroid disease. Out of the typical vital signs, preeclampsia was diagnosed. After considering the results of ultrasound images with massive free fluid in the abdomen, the emergency exploratory laparotomy was conducted. We delivered an alive baby and repaired the uterine rupture site. The patient was discharged on the 5th postoperative day in a stable condition.

Conclusion: The endoscopic surgery for adhesion separation of the fallopian tube could be a risk factor for SUUR. Timely diagnosis and management plays a crucial role in the prognosis of women suspected of SUUR.

This is an Open Access (OA) journal, and articles are distributed under the terms of the [Creative Commons Attribution-NonCommercial-ShareAlike 4.0 License](https://creativecommons.org/licenses/by-nc-sa/4.0/), which allows others to remix, tweak, and build upon the work non-commercially, as long as appropriate credit is given and the new creations are licensed under the identical terms.

For reprints contact: reprint@ipinnovative.com

1. Introduction

Uterine rupture is a rare but catastrophic complication for both maternal and fetal morbidity and mortality.¹ Population-based study reported that the trend of uterine rupture has increased sharply over the past decades, especially in developing countries pertaining to obstetric interventions, however, these cannot explain it entirely.^{1,2} Despite the fact that much more evidence has been reported to prompt the early detection and diagnosis in reducing morbidity and mortality, uterine rupture is still life-threatening to the mother and the fetus.³

Several risk factors of uterine rupture have been noticed. The high maternal age, increased usage of drugs for augmentation of labour, or uterine contraction increase through external pressure such as “fundal pressure” was associated with uterine rupture.⁴ More importantly, the

previous cesarean section or the scarred uterus condition is usually the cause of most uterine rupture cases.² By contrast, spontaneous unscarred uterine rupture (SUUR) was extremely rare and showed a higher composite of maternal and fetal morbidity compared to consequences of scarred uterine rupture.⁵ In terms of SUUR, several risk factors have been revealed, such as fundal pressure assistance,⁴ prior instrumental abortion,⁶ and unsuccessful induction. With regard to pharmacological induction consisting of prostaglandin E1, E2, F2 analogues and oxytocin drips, the uterine rupture following induction with misoprostol, which is a prostaglandin E1 is a rare side effect and not in dose-dependent relationship with misoprostol administration on an unscarred uterus.⁷ Intriguingly, the incidence of SURR in primigravid woman is usually unexpected and extremely rare.³ Herein, we first reported a SUUR case, which is worthy of discussion, of a primigravid woman who has a history of endoscopic surgery for

* Corresponding author.

E-mail address: drnhattudu@gmail.com (N. Q. Ho).

adhesiolysis separation of bilateral fallopian tubes and thyroid disease without treatment.

2. Case Presentation

A 28-year-old primigravid woman at 34⁺⁶ weeks of gestation was sent to our hospital because of her acute abdominal pain, which had begun the previous day and became severe before admission. According to the medical record, she was an infertility patient and came to hospital for periodic examination and was found to have bilateral proximal fallopian tubal occlusion underlying hysterosalpingogram (HSG) examination. After a consulting, she underwent bilateral laparoscopic for adhesiolysis separation of fallopian tubes one year ago. And, she also suffered from thyroid disease without any treatment during pregnancy. She had no history of hypertension and abdominal trauma. Her routine pregnancy check had been performed at local health centre, not at our hospital.

On admission to the hospital, patient was suspected to have preeclampsia with blood pressure of 140/80 mmHg. Other vital signs were: pulse rate of 100 beats per minute, and a respiratory rate of 19 breaths per minute. Physical examination showed a tense abdomen but no rebound tenderness. On vaginal examination, the patient's cervix was closed, the vaginal discharge was observed with no evidence of bleeding.

Emergent ultrasonography showed one live fetus in a cephalic presentation. A Doppler fetal monitor was used to detect the fetal heartbeat that was at proximately 5 cm under umbilicus and deviation of umbilicus to the left. The fetal heart rate was 156 beats per minute. The infant at 34⁺⁶ weeks of gestation corresponded with all the recorded fetal growth parameters. However, a massive amount of abdominal effusion was revealed in abdominal ultrasonography. After that, a diagnostic abdominal puncture revealed the blood of dark color with no coagulation.

Laboratory blood tests showed the following: white blood cells, $19.61 \times 10^3/\mu\text{L}$; neutrophils, 85.8%; red blood cells, $4.6 \times 10^6/\mu\text{L}$; hemoglobin, 14.1g/dL; platelets, $180.0 \times 10^9/\text{L}$; and creatinine, 51 $\mu\text{mol/L}$; procalcitonin, 0.246 ng/mL A high level of uric acid was detected at 395 $\mu\text{mol/L}$. Normal results were observed in urine and liver function tests. Coagulopathy gained no positive finding.

After consultation, the patient was diagnosed to have internal bleeding, suspected preeclampsia at 34⁺⁶ weeks of gestation, and untreated thyroid disease. With pre op preparation, on emergency basis, we performed an exploratory laparotomy.

On opening the abdomen, the hemoperitoneum of dark color blood and blood clots (of approximately 1000mL) were found in the abdominal cavity (Figure 1). We performed a lower segment cesarean section to deliver a

live infant. The female infant's weight was 3000 grams, and the infant's Apgar scores were 6 at 1 min and 7 at 5 min. On uterine examination, a rupture was found at the angle of right uterine horns with a diameter of 10*5*6 cm, placental tissue protruding from the bleeding rupture (Figure 2). Owing to the small size of the rupture, which is only about 1/10 that of the attached area of uterine placenta, the placenta was not totally detached from the uterine. In this case, the placenta dissection was throughly operate without any sign of placenta percreta. We repaired the rupture site with 1.0 monocryl sutures for ligating the bilateral uterine arteries. We applied the CHO suture (multiple square sutures) at the right cornus of the fundus and a vertical B-Lynch sutures. After suturing, no bleeding was observed. We closed the defect by locking sutures of the myometrium. The uterine incision was sutured and covered with the peritoneum; both ovaries were intact. The liver appeared normal. Blood clots were observed at left and right sub-hepatic spaces; they were suctioned out and cleaned off. Two abdominal drainage tubes were used. One tube had been placed in the pouch of Douglas and drained to the left lower quadrant of the abdomen; the other tube was inserted at Morison's pouch and diverted to the right upper quadrant of the abdomen. Total pre-and intraoperative blood loss was about 1200-1400 ml. Therefore, every two bags of 350 ml of red blood cells (RBC) were infused to patient during operation and post-operation (up to 1400 ml of RBC used).

The mother had an uneventful postoperative course, and she was discharged five days after the operation in a stable condition. She was consulted for using contraceptive therapy within at least two years after the operation and should be well-checked for future pregnancy.

3. Discussions

SUUR is uncommon but life threatening to mother and fetus. Hence, the acknowledgement of its etiology and pathogenesis is necessary. The incidence of SUUR was extremely low in the developed countries;¹ however, it remained high in developing countries.⁸ We presented a SUUR case without apparent reason in a 28-year-old primigravid woman at 34+6 weeks of gestation who was admitted to the hospital with abdominal pain and a history of surgery for infertility.

In patients with unscarred uterus, the diagnosis is usually delayed as there is false sense of security when they have complained of pain in abdomen. Some common risk factors have been identified in unscarred uterine rupture, including delivery with fundal pressure assistance,⁴ stimulation of oxytocin,⁵ prior instrumental abortion.⁶ Besides, curettage, myomectomy, and hysteroscopy have been identified as risk factors for unscarred uterus rupture.⁹ Labor dystocia is also a risk factor for this scenario.¹⁰ Other predisposing factors are multiparty, multiple pregnancies, big babies,¹¹ chronic use of corticosteroids,¹² placenta percreta,¹³

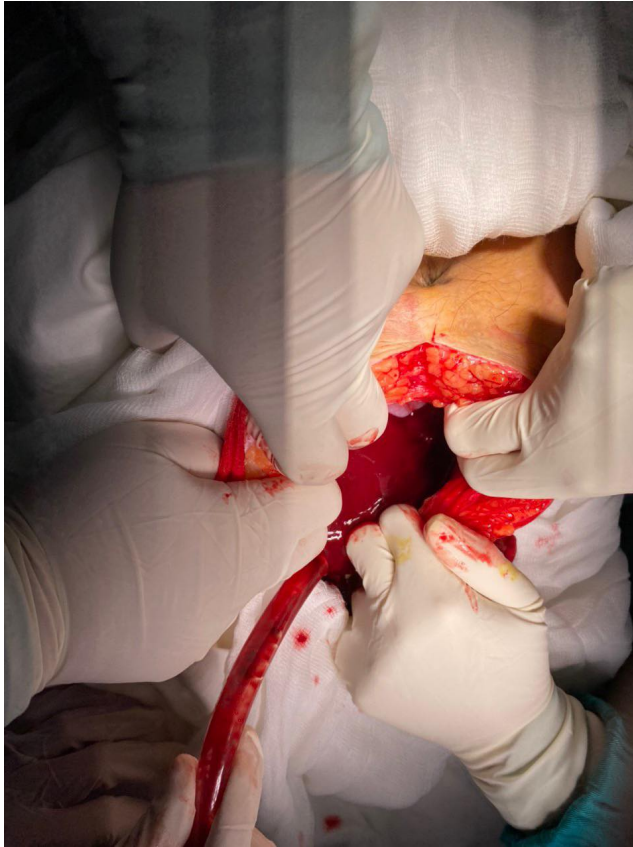

Fig. 1: Hemoperitoneum of dark color blood and blood clots were found in the abdominal cavity

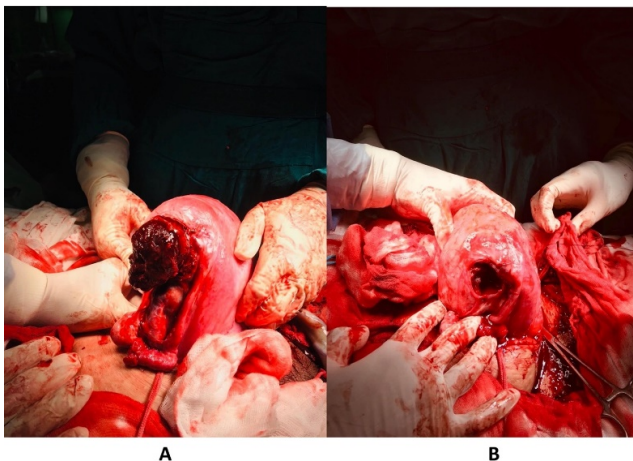


Fig. 2: Uterine rupture identified during cesarean section. A rupture was found on the right side of the uterus with a diameter of 10*5*6 cm. lacental tissue protruding from the bleeding rupture (A). The massive hole remained after removing placental tissue (B)

uterine anomaly.¹⁴ Additionally, the risk of uterus rupture increased linearly with maternal age¹⁵ or passive cocaine abuse¹²—however, none of above mentioned risk factors were present in our patient.

Among primigravida women who acquired SUUR without identified risk factors, only 25% (1/8 cases) was an incomplete rupture, according to the systematic review of Zhao and colleagues.³ The present case was an infrequent event because we observed an incomplete rupture at the right side of the uterine. The presented woman underwent laparoscopic surgery for infertility and her bilateral fallopian tubes adhesiolysis was done one year before her pregnancy. This time, the rupture site was far away from her previous surgery of the fallopian tubes. Therefore, we speculated that her previous surgery might not directly cause the spontaneous rupture of the uterus. However, we could not exclude the possibility that the previous surgery might contribute to the current uterine rupture. In addition, the uterine rupture was at the site of the uterine-attached placenta that may be considered as a weak part of uterus that is worthy of discussion in some further cases. Here, the uterine rupture can be foreseen in this case. We tried to find some literature to explain why this event happened in our patient when she has a no-damaged uterus. Sun et al.¹⁶ reported that a SUUR case was possibly caused by the use of an electric cauterly during the previous laparoscopic salpingectomy. In line with this, we cannot exclude the possibility of the laparoscopic electric cauterly during previous surgery and damage to uterine wall as a risk factor of uterus rupture. Furthermore, our patient also had untreated thyroid disease. Evidence has shown the link of thyroid diseases and adverse pregnancy outcomes, such as preterm birth, cesarean section, premature rupture of membranes (PROM), and placental abruption.¹⁷ In vivo studies, the important relationship between thyroid hormones and uterine development by altering the reproductive hormone levels have been elucidated.¹⁸ Therefore, we suspect that the untreated thyroid disease might be a potential association to the uterus rupture in our patient that merits further mechanistically investigation.

4. Conclusion

SUUR is a severely catastrophic health outcome for the mother and fetus. The present case study may serve as a reference to raise the suspicion of a SUUR in a patient with previous laparoscopic surgery that required a timely exploratory laparotomy. Further study requires investigating whether the presence of untreated thyroid disease could be linked to the SUUR incidence.

5. Source of Funding

None.

6. Conflict of Interest

The authors declare no conflict of interest.

References

- Hofmeyr GJ, Say L, Gülmezoglu AM. Systematic review: WHO systematic review of maternal mortality and morbidity: the prevalence of uterine rupture. *BJOG*. 2005;112:1221–8.
- Al-Zirqi I, Stray-Pedersen B, Forsén L, Daltveit AK, Vangen S. Uterine rupture: trends over 40 years. *BJOG*. 2016;123(5):780–7.
- Zhao Y, Tian B, Xu Y, Dai H. Spontaneous prelabor unscarred uterine rupture in primigravida: a case report and review of literature. *Int J Clin Exp Med*. 2017;10:7296–7303.
- Wei SC, Chen CP. Uterine rupture due to traumatic assisted fundal pressure. *Taiwan J Obstet Gynecol*. 2006;45:170–2.
- Gibbins KJ, Weber T, Holmgren CM, Porter TF, Varner MW, Manuck TA. Maternal and fetal morbidity associated with uterine rupture of the unscarred uterus. *Am J Obstet Gynecol*. 2015;213(3):382.
- Wang YL, Su TH. Obstetric uterine rupture of the unscarred uterus: a twenty-year clinical analysis. *Gynecol Obstet Invest*. 2006;62(3):131–5.
- Ansong G, Sebuabe SA, Afrani AK. Uterine Rupture Following Misoprostol Induction of Labour at 36 Weeks Gestation in an Unscarred Uterus. *Obstet Gynecol Cases Rev*. 2020;7:158. doi:10.23937/2377-9004/1410158.
- Nahum G, Pham K. Uterine rupture in pregnancy. Medscape Reference; 2010. Available from: <https://reference.medscape.com/article/275854-overview#:~:text=Uterine%20rupture%20occurs%20when%20a,Fetal%20distress>.
- Andonovová V, Hruban L, Gerychová R, Janků P, Ventruba P. Uterine rupture during pregnancy and delivery: risk factors, symptoms and maternal and neonatal outcomes-retrospective cohort. *Ceska Gynecol*. 2019;84(2):121–8.
- Vachon-Marceau C, Demers S, Goyet M, Gauthier R, Roberge S, Chaillet N, et al. Labor dystocia and the risk of uterine rupture in women with prior cesarean. *Am J Perinatol*. 2016;33(6):577–83.
- Misra M, Roychowdhury R, Sarkar NC, Koley MM. The spontaneous prelabour rupture of unscarred uterus at 34 weeks of pregnancy. *J Clin Diagn Res*. 2013;7(3):548–9.
- Cai E, Shao YH, Mansour FW, Brown R. Spontaneous Uterine Rupture in a Multigravid Pregnant Woman with Unscarred Uterus on Chronic Steroid Use: A Case Report. *J Obstet Gynaecol Can*. 2021;43(1):82–4.
- Enebe J, Ofor I, Okafor I. Placenta percreta causing spontaneous uterine rupture and intrauterine fetal death in an unscarred uterus: A case report. *Int J Surg Case Rep*. 2019;65:65–8.
- Tola EN. First trimester spontaneous uterine rupture in a young woman with uterine anomaly. *Case Rep Obstet Gynecol*. 2014;2014:967386. doi:10.1155/2014/967386.
- Hochler H, Wainstock T, Lipschuetz M, Sheiner E, Ezra Y, Yagel S, et al. Grandmultiparity, maternal age, and the risk for uterine rupture—A multicenter cohort study. *Acta Obstet Gynecol Scand*. 2020;99:267–73.
- Sun Y, Huang J, Kong HF. Spontaneous rupture of unscarred uterus in the third trimester after in vitro fertilization-embryo transfer because of bilateral salpingectomy: A case report. *Medicine (Baltimore)*. 2019;98(48):e18182.
- Männistö T, Mendola P, Grewal J, Xie Y, Chen Z, Laughon SK. Thyroid diseases and adverse pregnancy outcomes in a contemporary US cohort. *J Clin Endocrinol Metab*. 2013;98(7):2725–33.
- Kong L, Wei Q, Fedail JS, Shi F, Nagaoka K, Watanabe G. Effects of thyroid hormones on the antioxidative status in the uterus of young adult rats. *J Reprod Dev*. 2015;61(3):219–27.

Author biography

Nhat Quang Ho, Attending Physician

Anh Dinh Bao Vuong, Attending Physician

Thanh Quang Le, Attending Physician

Cite this article: Ho NQ, Vuong ADB, Quang Le T. Spontaneous unscarred uterine rupture at 34⁺⁶ weeks of gestation in a primigravid women: A case report. *Indian J Obstet Gynecol Res* 2022;9(1):131-134.