

Content available at: <https://www.ipinnovative.com/open-access-journals>

Indian Journal of Obstetrics and Gynecology Research

Journal homepage: www.ijogr.org

Case Report

A rare case of giant broad ligament leiomyoma mimicking ovarian malignancy

Bhopesh Kadian^{1,*}, Sanjeev Singla¹, Rohit Virmani¹, Garima Dwivedi¹

¹Dept. of General Surgery, BPS Government Medical College, Haryana, India



ARTICLE INFO

Article history:

Received 12-03-2022

Accepted 21-04-2022

Available online 08-08-2022

Keywords:

Broad ligament leiomyoma

Ovarian malignancy

Myxoid leiomyoma

ABSTRACT

Introduction: Broad ligament leiomyomas are uncommon but when they occur they can present in varying degrees of bladder and bowel obstruction. A definite diagnosis of the broad ligament leiomyoma was made after histopathological report of the specimen obtained after operating the patient.

Case Presentation: A 45 years old female had a history of pain in abdomen and increase abdominal girth for 6 months. On the basis of CT scan a diagnosis of left adnexal mass was made. She was advised surgery and subsequently a mass of 30 cm x 21 cm x 22 cm was resected which weighed 11.05 kgs.

Clinical Discussion: Hyaline degeneration is most common among all of the secondary changes in leiomyomas. However, a dilemma in diagnosis caused by myxoid degeneration. In present case there is presence of both hyaline and myxoid degeneration.

Conclusion: This is a unique presentation of a broad ligament leiomyoma which mimicked ovarian malignancy for which staging laparotomy was done.

This is an Open Access (OA) journal, and articles are distributed under the terms of the [Creative Commons Attribution-NonCommercial-ShareAlike 4.0 License](https://creativecommons.org/licenses/by-nc-sa/4.0/), which allows others to remix, tweak, and build upon the work non-commercially, as long as appropriate credit is given and the new creations are licensed under the identical terms.

For reprints contact: reprint@ipinnovative.com

1. Introduction

Leiomyoma, which is the commonest female genital neoplasm affecting 30% of all women of reproductive age but the incidence of broad-ligament leiomyoma is <1%.¹ Even when benign leiomyoma with degenerative changes can mimic malignancy of adnexal organs and raise a diagnostic dilemma. Tumors of broad ligament are uncommon. Leiomyomas of broad ligament are usually asymptomatic but can present with bladder and bowel dysfunction as pressure symptoms. A case is being presented of a 43year old female that presented with gradual abdominal swelling which was radiologically diagnosed as left adnexal mass.

2. Case Report

A 45year old female presented to our department with complains of pain in abdomen for 6 months and increase in abdominal girth for 6 months. Abdominal examination revealed a mass extending from pelvis to epigastric region. Upper border was felt midway between umbilicus and xiphisternum. General examination showed mild pallor. There was no pleural effusion, free fluid in the peritoneum, or retroperitoneal mass. Hemoglobin was 9.8 gm% and other hematological parameters were within normal range. CT pelvis suggested a left adnexal mass of size 30 cm X 21 cm X 22 cm which was highly vascular and had multiple necrotic changes (Figure 1).

To evaluate the possibility of an ovarian malignancy, serum CA 125, CEA, CA 19.9 levels were estimated, and all were within normal limits. Staging laparotomy with total abdominal hysterectomy and bilateral salpingo-oophorectomy and omentectomy was done which revealed a huge hemorrhagic tumor in left broad ligament. Grossly

* Corresponding author.

E-mail address: bhopeshkadian@gmail.com (B. Kadian).

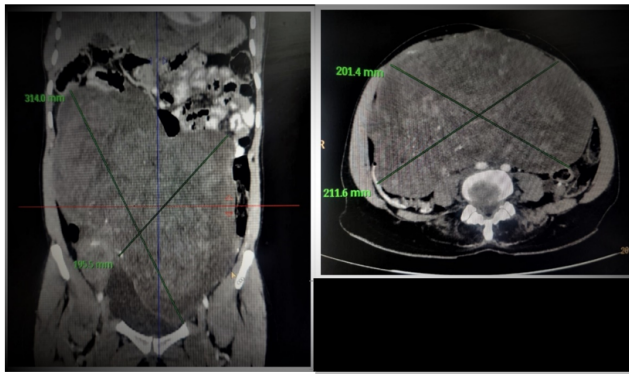


Fig. 1: CECT abdomen showing a large heterogenous mass lesion arising from pelvis in coronal (right) and axial (left) view

uterus and bilateral ovaries were normal. An ovoid mass arising from left broad ligament with hemorrhagic, variegated and bosselated appearance measuring 30 cm x 21 cm x 22 cm was noted (Figure 2).

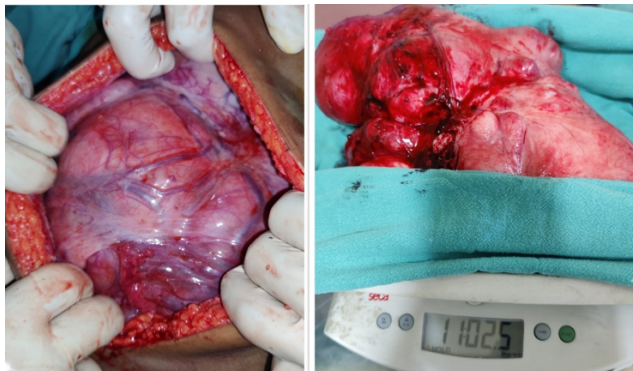


Fig. 2: (Right) Intraoperative photograph showing large hard lobulated mass with high surgical vascularization (Left) resected specimen showing weight of around 11 kg

Weight of the tumor was 11.05 kg.

On histopathological examination, cut section of the mass showed features of leiomyoma with myxoid and hyaline degenerative changes. No malignant changes were noted (Figure 3).

Therefore, final diagnosis of leiomyoma of the broad ligament was made. Postoperative period was uneventful.

3. Discussion

Fibroids are smooth muscle benign tumours; most commonly arise from uterus but may also rise from extra uterine sites like broad ligament. This case report of broad ligament myoma with extensive cystic degeneration is presented for its rarity and diagnostic challenges as they mimic pelvic adnexal tumours. Sometimes leiomyomas originating from uterus becomes adherent to surrounding structures such as broad ligament, omentum

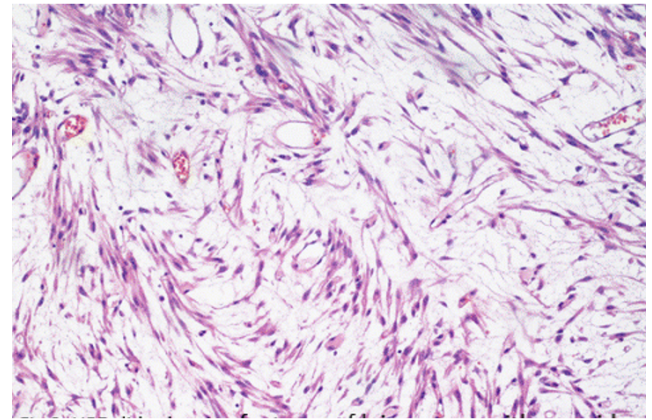


Fig. 3: HPE slide showing features of leiomyoma with myxoid and hyaline degenerative changes

or retroperitoneal connective tissue. These leiomyomas lose their original attachment after developing new blood supply and thus becoming parasitic. Another theory of broad ligament leiomyomas origin is that they may arise from hormonally sensitive smooth muscle element of that ligament.²

Clinically, these lesions may manifest as extrauterine pelvic masses that compress the urethra, bladder neck, or ureter, producing symptoms of varying degrees of urinary outflow obstruction or secondary hydronephrosis.³ A typical leiomyoma usually has a whorled appearance, with variable echogenicity depending on the extent of degeneration, fibrosis, and calcification. The differential diagnosis for parasitic leiomyomas includes masses of ovarian origin (both primary neoplasms and metastases), broad ligament cysts, and lymphadenopathy.

Transvaginal ultrasonography may be of great help in diagnosing broad ligament leiomyomas because it allows clear visual separation of the uterus and ovaries from the mass. MR imaging, with its multiplanar imaging capabilities, also may be extremely useful for differentiating broad ligament leiomyomas from masses of ovarian or tubal origin and from broad ligament cysts. The distinctive MR imaging appearances of typical leiomyomas also are useful in differentiating them from solid malignant pelvic tumors. This observation is important because broad ligament leiomyomas are associated with pseudo-Meigs syndrome and produce an elevated CA-125 level that may clinically mimic that in metastatic ovarian carcinoma, thereby causing diagnostic confusion.^{4,5}

Leiomyomas develop in woman with increasing age and have prevalence varying from 4 percent in age group of 20 -30 year to 33 percent in age group of 40-60 year. These leiomyomas arise most commonly from uterus but sometimes they develop in unusual location that make their diagnosis more difficult. Example of leiomyomas in unusual location are diffuse peritoneal leiomyomatosis, intravenous

leiomyomatosis, retroperitoneal leiomyomas and parasitic leiomyomas (broad ligament).

4. Conclusion

In this case report we highlight the rarity of broad ligament leiomyoma. The diagnostic imaging can produce challenges as faced by us in the following case. The mixed solid and cystic appearances of the broad ligament produce challenges that can only be removed after surgery. The presentation of leiomyoma can vary from being asymptomatic to obstruction of bladder and bowel. Thus, Identifying and removal of the leiomyomas is necessary to avoid the above-mentioned complications.

5. Source of Funding

None.

6. Conflict of Interest

The authors declare no conflict of interest.

References

1. Mallick D, Saha M, Chakrabarti S, Chakraborty J. Leiomyoma of Broad Ligament Mimicking Ovarian Malignancy- Report of a Unique Case. *Kathmandu Univ Med J (KUMJ)*. 2014;47(3):219–21.
2. Rader JS, Binette SP, Brandt TD, Sreekanth S, Chhablani A. Ileal hemorrhage caused by a parasitic uterine leiomyoma. *Obstet Gynecol*. 1990;76(3 Pt 2):531–4.
3. Yıldız P, Cengiz H, Yıldız G, Sam AD, Yavuzcan A, Çelikbaş B, et al. Two unusual clinical presentations of broad-ligament leiomyomas: a report of two cases. *Medicina (Kaunas)*. 2012;48(3):163–5.
4. Paramasivam S, Tripcony L, Crandon A, Quinn M, Hammond I, Marsden D, et al. Prognostic importance of preoperative CA 125 in International Federation of Gynecology and Obstetrics stage I epithelial ovarian cancer: an Australian multicenter study. *J Clin Oncol*. 2005;23(25):5938–42.
5. Tsao KC, Hong JH, Wu TL, Chang PY, Sun CF, Wu JT. Elevation of CA 19-9 and chromogranin A, in addition to CA 125, are detectable in benign tumors in leiomyomas and endometriosis. *J Clin Lab Anal*. 2007;21(3):193–6.

Author biography

Bhopes Kadian, Senior Resident  <https://orcid.org/0000-0001-8007-1236>

Sanjeev Singla, Senior Professor

Rohit Virmani, Assistant Professor

Garima Dwivedi, Junior Resident

Cite this article: Kadian B, Singla S, Virmani R, Dwivedi G. A rare case of giant broad ligament leiomyoma mimicking ovarian malignancy. *Indian J Obstet Gynecol Res* 2022;9(3):418-420.