

Content available at: <https://www.ipinnovative.com/open-access-journals>

Indian Journal of Obstetrics and Gynecology Research

Journal homepage: www.ijogr.org

Case Report

A case of ovarian torsion in early pregnancy after ovulation induction-diagnostic dilemma and management

Aparna Krishnamurthy^{1,*}, Shyamal Maiti², GD Maiti¹

¹Dept. of Obstetrics & Gynecology, INHS Asvini, Mumbai, Maharashtra, India

²Dept. of Anasthesia, Manipal Tata Medical College, Jamshedpur, Jharkhand, India



ARTICLE INFO

Article history:

Received 25-02-2022

Accepted 21-04-2022

Available online 08-08-2022

Keywords:

Ovarian torsion

Pregnancy

Laparoscopy

Untwisted

ABSTRACT

Ovarian torsion is one of the common gynaecologic surgical emergencies. Ovarian stimulation in infertility treatment has become a major risk factor for ovarian torsion. The diagnosis of the condition is challenging in early pregnancy and timely diagnosis can prevent morbidity of both mother and foetus. We present a case of 28 years old primi gravida known case of polycystic ovarian syndrome (PCOS) conceived after ovulation induction, at 7 weeks period of gestation with right ovarian torsion. Laparoscopic untwisting of the ovarian pedicle and debulking of multiple follicular ovarian cysts bilaterally was done. Patient withstood the surgery well and the pregnancy continued uneventfully. The patient progressed to deliver a healthy male baby at 40 completed weeks of gestation.

This is an Open Access (OA) journal, and articles are distributed under the terms of the [Creative Commons Attribution-NonCommercial-ShareAlike 4.0 License](https://creativecommons.org/licenses/by-nc-sa/4.0/), which allows others to remix, tweak, and build upon the work non-commercially, as long as appropriate credit is given and the new creations are licensed under the identical terms.

For reprints contact: reprint@ipinnovative.com

1. Introduction

Ovarian torsion is a gynaecological emergency in any patient more so in early pregnancy which can jeopardize the maternal and foetal outcome. Timely diagnosis and intervention can make the difference between ovarian loss and salvage – a significant outcome in women of reproductive age. It's a race against time for both the gynaecologist and the patient.

2. Case Report

28 years old Primi gravida, a nurse by profession presented to the emergency department with complaints of pain lower abdomen since two hours. She was referred from another hospital after an antenatal ultrasound which revealed an early intra uterine pregnancy of 7 weeks gestational age with good cardiac activity, with bilateral large multiple clear ovarian cysts and diagnosed as ovarian

hyperstimulation syndrome (OHSS). She gave the history of been under treatment elsewhere for polycystic ovarian syndrome (PCOS). She was given ovulation induction with injection human menopausal gonadotropin (hMG) three doses and was advised timed intercourse, she failed to continue her follow up as she proceeded on leave. She confirmed her pregnancy by home pregnancy urine test on missing her menses. She had no history of dysuria, fever or bleeding per vagina, had occasional nausea and vomiting. On general examination she was anxious, but comfortable, not pale, afebrile, hydration fair, systemic exam NAD, per abdomen soft, minimal tenderness in the right iliac fossa and supra pubic region, no guarding or rigidity, no mass palpable, bimanual pelvic examination uterus anteverted, 6-8 weeks enlarged, non-tender, forniceal fullness felt, non-tender, rocking sign negative, no discharge or bleeding per vagina. Differential diagnosis of secondary OHSS, acute appendicitis, torsion ovary in early intra uterine pregnancy were made. Patient was admitted in ICU, was kept nil by mouth and treated symptomatically with

* Corresponding author.

E-mail address: apargan@hotmail.com (A. Krishnamurthy).

inj acetamenophen. All her biochemical parameters were WNL, electrolytes WNL, she was hemodynamically stable. Bedside ultrasound revealed an early intrauterine pregnancy and bilateral large multiple cysts in both ovaries, little free fluid in the peritoneal cavity. She responded well to the initial treatment she was relieved of her symptoms after analgesia. She was shifted to step down care started on oral fluids, she remained haemodynamically stable, she was still thought of as secondary OHSS. 24 hours later her pain re-appeared, localised in the right iliac fossa, clinically abdomen was soft and bedside repeat ultrasound revealed the same bilateral multiple large ovarian cysts, doppler was inconclusive, minimal free fluid in peritoneal cavity and an alive intra uterine gestation, no signs suggestive of appendicitis, though surgical specialist opinion was also sought. She responded to analgesics but briefly the pain episodes became more frequent with intermittent pain free periods. The patient was clinically diagnosed as torsion ovarian cyst in view of enlarged ovary due to multiple follicles, right sided localised pain not responding to analgesics anymore. After informed consent patient was taken up for diagnostic laparoscopy under general anaesthesia in the presence of surgeon (in view of suspicion of appendicitis). Laparoscopy findings: bilateral multiple enlarged follicles compounding with ovarian hyper stimulation, minimal clear fluid in the peritoneal cavity, both ovaries were looking healthy and bulky, right ovarian pedicle was twisted two and half turns, but ovarian colour was maintained with no signs of ischemic changes. Follicular cysts were aspirated and the ovary was untwisted after debulking, left ovarian cysts were aspirated and debulked too. Healthy looking appendix was visualised. Patient withstood the procedure well, post-operative ultrasound confirmed the cardiac activity of the in-utero pregnancy, patient was given progesterone supplements for 4 weeks. Her post-operative period was uneventful. She was discharged after one week with a repeat ultrasound confirming the viability of the pregnancy, her rest of the pregnancy continued uneventfully. She progressed to 40 weeks of pregnancy and delivered an alive male baby weighing 3.75 kg by emergency caesarean section for non-progress of labour and during the surgery her ovaries were examined grossly and found to be healthy.

3. Discussion

Adnexal torsion is when the ovary, with or without the fallopian tube rotates along its vascular pedicle, leading to partial or complete occlusion of the blood supply and if left untreated resulting in necrosis. It has a propensity to involve the right adnexa. The left adnexa is probably spared due to the presence of the sigmoid colon which restricts its mobility, however bilateral torsions are also reported.^{1,2} Ovarian torsion is a one of the gynaecological emergency requiring immediate intervention. The incidence

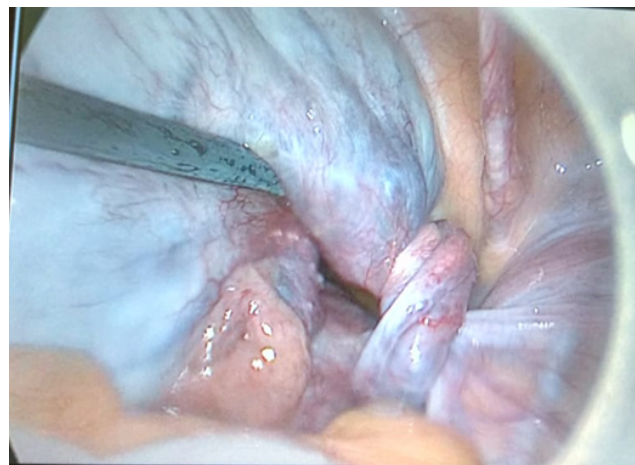

Fig. 1: Per-operative finding twisted right ovarian pedicle, preserved ovarian colour

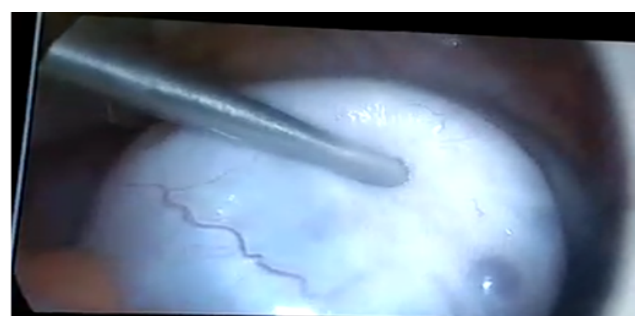

Fig. 2: Aspiration from the cyst to debulk the ovary

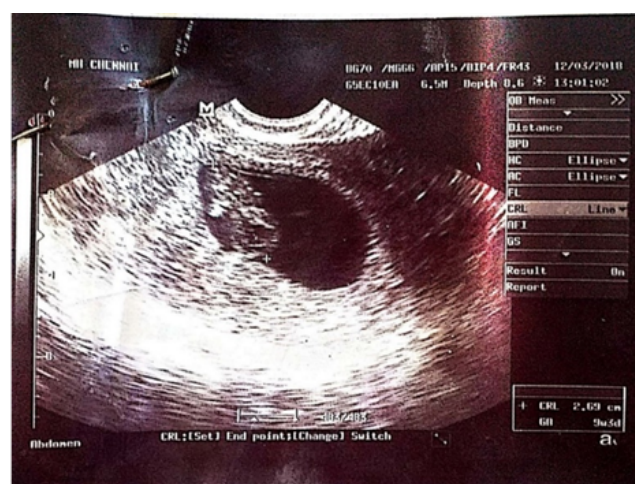

Fig. 3: Post op image of the live intra uterine pregnancy

of ovarian torsion ranges between 5-9 per 100,000 women. The occurrence is more in reproductive age group and maximum between 25-30 years of age. Ovarian stimulation in infertility patients is a major risk factor to adnexal torsion, with increased prevalence of the ovulation induction, this complication has to be kept in mind in pregnancy, other risk factors been ovarian cysts of moderate size around 5 cm, tubal surgeries, polycystic ovarian syndrome and previous torsion.¹ Diagnosis is basically clinical, however, pelvic ultrasonography, transvaginal ultrasound (TVUS) along with doppler evaluation of ovarian blood flow, aids in the diagnosis and excludes simulating conditions.³ However the presence of blood flow in doppler doesn't really rule out ovarian torsion.² Arriving at an accurate diagnosis of adnexal torsion is challenging due to the similarity of the presentation to non-gynaecological conditions, patients are taken up for surgery with high index of clinical suspicion. Laparoscopic approach is preferred to confirm ovarian torsion. On laparoscopy the assessment of the side involved, the condition of ovary affected in terms of ischemia should be assessed.⁴ Laparoscopic untwisting should be tried keeping in mind the right direction to be adopted, the pedicle on the right side rotates anticlockwise and vice versa (Kustner's law).^{3,5} If there's colour change of the ovary initially, after detorsion the colour and the vitality are restored remarkably.^{2,5} Ovariectomy or adnexectomy, is the last resort only if the ovary in question is gangrenous.⁶ The concept of release of toxins/emboli in the main stream on detorting the pedicle is not substantiated by evidence.⁴ A high index of suspicion to diagnose ovarian torsion and an early laparoscopy can prevent both the maternal and the foetal complications.⁵ In this case diagnostic dilemma was experienced. Patient was in early pregnancy, conceived after ovulation induction, presented with right iliac fossa pain, in the setting of Secondary OHSS and doppler been inconclusive, the diagnosis was elusive due to similarity to non-gynaecological condition.

However, a clinical judgement of diagnostic laparoscopy and laparoscopic untwisting of the ovarian pedicle saved the patient from ovarian damage and foetal complications.

4. Source of Funding

None.


5. Conflict of Interest

The authors declare no conflict of interest.

References

1. Mancuso A, Broccio G, Angio LG, Pirri V. Adnexal torsion in pregnancy. *Acta Obstet Gynecol Scand.* 1997;76(1):83–4.
2. Tandulwadkar S, Shah A. Bhavana Agarwal Detorsion and Conservative Therapy for Twisted Adnexa: Our Experience. *J Gynecol Endosc Surg.* 2009;1(1):21–6.
3. Morton MJ, Masterson M, Hoffmann B. Case report: ovarian torsion in pregnancy - diagnosis and management. *J Emerg Med.* 2013;45(3):348–51.
4. Oelsner G, Cohen SB, Soriano D, Admon D, Mashiach S, Carp H, et al. Minimal surgery for the twisted ischaemic adnexa can preserve ovarian function. *Hum Reprod.* 2003;18(12):2599–602.
5. Piper HG, Oltmann SC, Xu L, Adusumilli S, Fischer AC. Ovarian torsion: diagnosis of inclusion mandates earlier intervention. *J Pediatr Surg.* 2012;47(11):2071–6.
6. Moiety FMS. Adnexal torsion: Management controversy: A case series. *Middle East Fertility Soc J.* 2017;22(2):156–9.

Author biography

Aparna Krishnamurthy, Associate Professor  <https://orcid.org/0000-0003-4596-7074>

GD Maiti, Professor and HOD

Cite this article: Krishnamurthy A, Maiti S, Maiti GD. A case of ovarian torsion in early pregnancy after ovulation induction-diagnostic dilemma and management. *Indian J Obstet Gynecol Res* 2022;9(3):425-427.