

Content available at: <https://www.ipinnovative.com/open-access-journals>

Indian Journal of Obstetrics and Gynecology Research

Journal homepage: [www.ijogr.org](http://www.ijogr.org)

## Case Report

# Adenomyosis in a postmenopausal woman: A rare entity

Purnima Upreti<sup>1</sup>, Punam Godara<sup>1,\*</sup>

<sup>1</sup>Himalayan Institute of Medical Science, SHRU, Jollygrant, Dehradun, India



### ARTICLE INFO

#### Article history:

Received 05-01-2022

Accepted 10-03-2022

Available online 08-08-2022

#### Keywords:

Adenomyosis

Postmenopausal

### ABSTRACT

Adenomyosis is an important clinical challenge in gynecology. It is known as the benign invasion of endometrium into the myometrium. It is usually seen in women of reproductive age group where estrogen plays an important role, rare in postmenopausal women. Here we present a case of a 68-year-old lady who presented to us with postmenopausal bleeding and was found to have adenomyosis.

This is an Open Access (OA) journal, and articles are distributed under the terms of the [Creative Commons Attribution-NonCommercial-ShareAlike 4.0 License](https://creativecommons.org/licenses/by-nc-sa/4.0/), which allows others to remix, tweak, and build upon the work non-commercially, as long as appropriate credit is given and the new creations are licensed under the identical terms.

For reprints contact: [reprint@ipinnovative.com](mailto:reprint@ipinnovative.com)

## 1. Case Report

A 68-year-old female presented with recurrent episodes of postmenopausal bleeding over a period of two months. She had attained menopause at the age of 52 years. She was para 4 live 3 with all full term vaginal deliveries at home. She got her bilateral tubal ligation done about 25 years back. There was no significant past history. She had no history of any hormonal treatment in the past. She had normal regular cycles of 4-5 days before menopause. On examination, her vitals were stable. B/L breast soft. Per abdomen-soft, non tender. Per speculum examination revealed hypertrophied cervix. Slight bleeding through os was present. On bimanual examination, uterus was 12-14 weeks size with irregular surface, firm, mobile and tender. There was no adnexal mass.

Her laboratory investigations were unremarkable. Pap smear was Negative for Intraepithelial Lesion / Malignancy. Trans Vaginal Sonography showed enlarged uterus with Endometrial Thickness 5.4mm and diffuse heterogenous echotexture of myometrium along with few small anechoic areas within it suggestive of diffuse adenomyosis. Endometrial biopsy was suggestive of

endometrial hyperplasia without atypia.

Since her bleeding continued, she was taken up for definitive surgery. Total abdominal hysterectomy with bilateral salpingoophrectomy was done. Per operative finding: Uterus was 14 weeks size, firm with irregular surface having two small (2\*2 cm) subserosal fibroids one at fundus and other on anterior wall. Cervix was elongated and hypertrophied. Both ovaries were looking normal. Both fallopian tubes showed fallope rings.

Cut section of uterine specimen showed thickened myometrium. Histopathological examination of uterus showed non secretory endometrium, multiple foci of endometrial glands and stroma deep in myometrium suggestive of diffuse adenomyosis and two subserosal fibroids and that of cervix showed Chronic cervicitis.

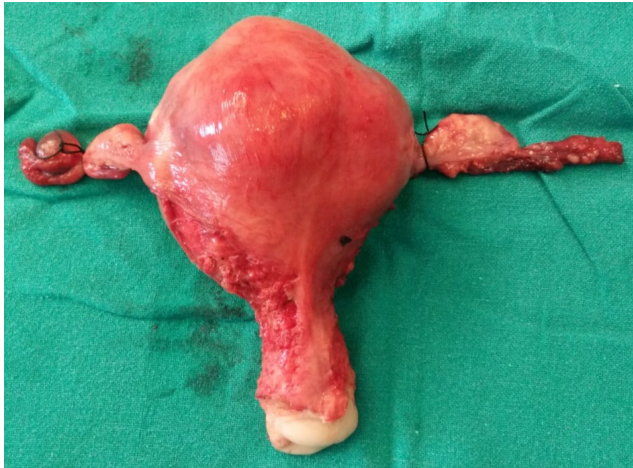A pathological diagnosis of adenomyosis with coexisting fibroid was made. The patient is under follow up.

## 2. Discussion

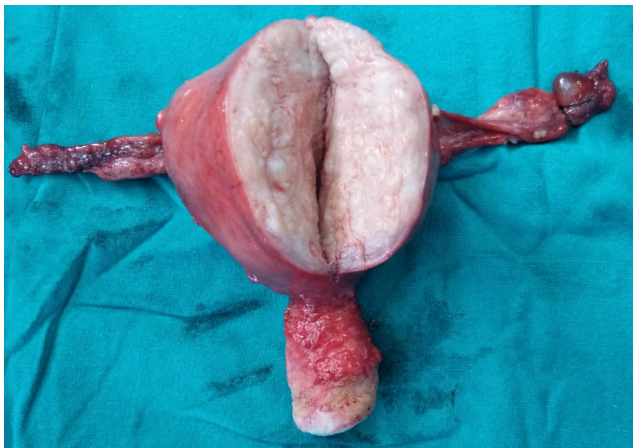Adenomyosis was first described in 1860 by Von Rokitsansky who found a heterotropic occurrence of islands of endometrium scattered throughout myometrium.<sup>1</sup> The current definition of adenomyosis was finally provided in 1972 by Bird who stated 'Adenomyosis

\* Corresponding author.

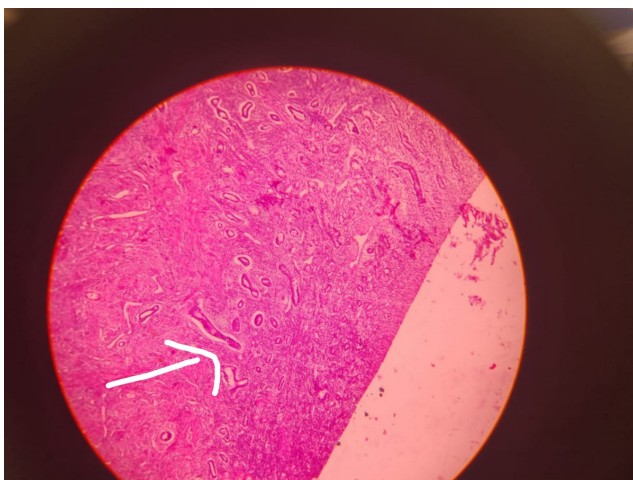
E-mail address: [punamgodara@gmail.com](mailto:punamgodara@gmail.com) (P. Godara).



**Fig. 1:** Post operative specimen



**Fig. 2:** Cut section of postoperative specimen



**Fig. 3:** Histopathology of postoperative specimen (adenomyosis)

may be defined as the benign invasion of endometrium into the myometrium, producing a diffusely enlarged uterus which microscopically exhibits ectopic non neoplastic endometrial glands and stroma surrounded by the hypertrophic and hyperplastic myometrium.<sup>2</sup> Adenomyosis may be diffuse or cystic, diffuse being more common. Adenomyosis considered a specific entity in the PALM-COEIN classification of causes of abnormal uterine bleeding.

The reported incidence of adenomyosis varies widely from 5 to 70% depending on the method used for diagnosis with a median incidence of 20 to 30%.<sup>3</sup>

The exact pathogenesis of adenomyosis is not known. Adenomyosis may occur by invagination of basal endometrium into myometrium and metaplasia of Mullerian rests in the myometrium.

The common risk factors for adenomyosis include age more than 40 years, multiparity, previous caesarean section or uterine surgery.<sup>3</sup> But the epidemiological scenario has changed. The disease is increasingly being diagnosed in young women, in women with infertility<sup>4</sup> or in those with pain or abnormal uterine bleeding or both.<sup>5</sup>

Adenomyosis regresses after menopause. So its presence in postmenopausal women is rare. The reported incidence of adenomyosis among postmenopausal women was 0.49% by Dr Akhtar Un Nisha Salaria et al,<sup>6</sup> 0.8% by Arunachalam B et al,<sup>7</sup> and 9% by Shaikh H et al.<sup>8</sup>

Upto 30% of patients with adenomyosis remain asymptomatic. Symptomatic women present with heavy menstrual bleeding, congestive dysmenorrhea, chronic pelvic pain, dyspareunia and infertility.

Bimanual examination reveals uniformly enlarged (Not more than 12 weeks size) tender uterus. However, the findings may be altered due to coexisting fibroid or pelvic endometriosis. In our case, uterus was 14 weeks size with irregular surface due to coexisting subserous fibroids.

The introduction of imaging techniques such as Trans vaginal sonography and Magnetic Resonance Imaging has allowed to establish pre operative diagnosis of adenomyosis.

The features indicative of adenomyosis on pelvic ultrasound include enlarged globular uterus, asymmetrical thickening of myometrium, myometrial cysts, echogenic subendometrial linings and buds, hyperechoic islands, fan shaped shadowing, an irregular or interrupted junctional zone and translesional vascularity on colour Doppler (MUSA criteria).<sup>9</sup>

The junctional zone at the endometrial-myometrial interface may be assessed by three dimensional TVS and MRI.

Definitive diagnosis of adenomyosis can be made histologically only when endometrial stroma and glandular tissue is found within the myometrium. Different criteria for required depth of invasion exist, some using an absolute measurement between 2.5 to 8mm while others

use a percentage of myometrial involvement Traditionally diagnosis is made when endometrial tissue has invaded more than 2% of myometrium or a minimum depth of invasion is equal to or more than 4 mm beneath the endomyometrial junction.<sup>10</sup>

While planning treatment for adenomyosis, two factors are important, age of patient and her desire for future fertility. The definitive treatment of symptomatic adenomyosis is hysterectomy, but it may not be an option in patients who are young, who desire future fertility or who are poor surgical candidates.

For these patients, treatment options include medical treatment such as Non Steroidal Anti Inflammatory drugs used to control pain and bleeding, Combined Oral Contraceptive pills (though not found very useful). LNG intrauterine system, GnRH analogues and Danazol, Conservative surgery such as resection of adenomyoma, myometrial reduction or newer interventional techniques such as uterine artery embolization.

Our case was postmenopausal, so total hysterectomy with bilateral salpingoophorectomy was the definitive treatment for her.

### 3. Conclusion

In conclusion, adenomyosis is a benign but often progressive condition. It is very rare in postmenopausal women. As the condition is estrogen dependent, menopause presents a natural cure. Still, very rarely as seen here, adenomyosis can present in the seventies or beyond.

### 4. Source of Funding

None.


### 5. Conflict of Interest


None.

## References

1. Cucinella G, Billone V, Pitruzzella I. Adenomyotic cyst in a 25-year-old woman: case report. *J Minim Invasive Gynecol.* 2013;20(6):894–8.
2. Benagiana G, Brosens I, Brosens I History of adenomyosis. *Best Pract Res Clin Obstet Gynaecol.* 2006;20(4):449–63.
3. Vercellini P, Viganò P, Somigliana E, Daguati R, Abbiati A, Fedele L. Adenomyosis: epidemiological factors. *Best Pract Res Clin Obstet Gynaecol.* 2006;20(4):465–77.
4. Puente JM, Fabris A, Patel J, Patel A, Cerrillo M, Requena A, et al. Adenomyosis in infertile women: prevalence and the role of 3D ultrasound as a marker of severity of the disease. *Reprod Biol Endocrinol.* 2016;14(1):60.
5. Naftalin J, Hoo W, Pateman K, Mavrelou D, Foo X, Jurkovic D. Is adenomyosis associated with menorrhagia? *Hum Reprod.* 2014;29(3):473–9.
6. Salaria AUN, Singh J. Prevalence of Adenomyosis in Hysterectomy Specimen in Jammu Region and its Clinical Correlations in a Tertiary Care Hospital. *J Med Sci Clin Res.* 2019;7(7):738–42.
7. Arunachalam B, Manivasakan J. A clinico - Pathological study of adenomyosis. *J Clin Diagn Res.* 2012;6:428–30.
8. Shaikh H, Khan KS. Adenomyosis in Pakistani women: four year experience at the Aga Khan University Medical Centre, Karachi. *J Clin Pathol.* 1990;43(10):817–9.
9. Champaneria R, Abedin P, Daniels J. Ultrasound scan and magnetic resonance imaging for the diagnosis of adenomyosis: systematic review comparing test accuracy. *Acta Obstet Gynecol Scand.* 2010;89(11):1374–84.
10. Sagar N, Tomar R, Balhara K, Mallya V, Mandal S, Khurana N. Histopathological Association of Adenomyosis with Various Gynaecological Pathologies. *Ann Pathol Lab Med.* 2020;7(2):221–3.

## Author biography

**Purnima Upreti**, Associate Professor  <https://orcid.org/0000-0001-7004-8112>

**Punam Godara**, Junior Resident  <https://orcid.org/0000-0001-7645-068X>

**Cite this article:** Upreti P, Godara P. Adenomyosis in a postmenopausal woman: A rare entity. *Indian J Obstet Gynecol Res* 2022;9(3):432-434.