

Content available at: <https://www.ipinnovative.com/open-access-journals>

Indian Journal of Obstetrics and Gynecology Research

Journal homepage: www.ijogr.org

Case Report

Metastatic leiomyosarcoma of vault post – hysterectomy

S A Deshpande¹, Alamelu Varsha Muthuraman^{1,*}

¹Dept. of Obstetrics and Gynaecology, Bharati Vidyapeeth deemed to be University Medical College and Hospital, Sangli, Maharashtra, India



ARTICLE INFO

Article history:

Received 05-05-2022

Accepted 23-05-2022

Available online 08-08-2022

Keywords:

Mitotically active leiomyoma

Leiomyosarcoma

ABSTRACT

Fibroids/Leiomyomas are the most common benign mesenchymal neoplasms and consist of smooth muscle cells with variable amounts of fibrous stroma. Atypical leiomyomas are rare forms of myoma (fibroid uterus), of which recurrent atypical leiomyoma post hysterectomy is rarer and its converting into leiomyosarcoma rising from the vault is rarest. The tumor occurs most frequently in uterus, affecting 20-30% of women of reproductive age. We report a case of 51 years old P4L4A2 patient presented with complaints of PV bleeding for 4 days, hysterectomy was done 1 year back for chronic nonspecific cervicitis and cervical leiomyomatous polyp. In January 2022, polypoidal growth from vault for which Laparoscopic excision of the mass was performed, Sample has been sent for histopathology and suggestive of mitotically active leiomyoma. Radical vaginectomy and reconstruction was done, small bowel deposits was found and diagnosed as Metastatic Leiomyosarcoma. Hence, diagnosis of leiomyosarcoma should always kept in mind though the patient is hysterectomized.

This is an Open Access (OA) journal, and articles are distributed under the terms of the [Creative Commons Attribution-NonCommercial-ShareAlike 4.0 License](https://creativecommons.org/licenses/by-nc-sa/4.0/), which allows others to remix, tweak, and build upon the work non-commercially, as long as appropriate credit is given and the new creations are licensed under the identical terms.

For reprints contact: reprint@ipinnovative.com

1. Introduction

Smooth muscles of the uterus encompass a variety of neoplasms, either benign or malignant. These includes leiomyomas, leiomyosarcomas and smooth muscle tumor of uncertain malignant potential (STUMP). Mitotically active leiomyoma a rare histologic entity of smooth muscle tumors of the uterus, they have the same clinical behavior as an ordinary leiomyomas, histologically characterized by a mitotic activity higher than 5 mitoses / high power field, without necrosis or cellular atypia. Leiomyosarcoma is a malignant smooth muscle cell tumor of unknown origin. It is a smooth muscle cell tumor and is malignant. Leiomyosarcoma, constitutes approximately 1% of all uterine malignancies; however it has a poor prognosis. The median age of women with leiomyosarcomas (50-55 years) arise in postmenopausal women, several cases have

been reported in women of reproductive age. These tumors usually grows as solitary, irregular, bulky masses that invade the uterine wall. Diagnosis of leiomyosarcomas depends on the presence of cytologic atypia, a high mitotic index and coagulative tumor cell necrosis. Some cases partially have these features, which help to distinguish between leiomyomas and other smooth muscle tumors.

2. Case Report

Mrs XX, 51 year old, presented to gynecology OPD P4L4A2 with following chief complaints of PV bleeding and bleeding while passing urine for 4 day. She did not have any complaints of abdominal pain, white discharge per vaginum, loss of weight, loss of appetite, no bowel complaints. She has 4 children all born through normal vaginal delivery. She has two spontaneous abortion at 2 ¹/₂ month and 2nd month of amenorrhea for which dilatation curettage was done. Mini-laparotomy for Tubal ligation

* Corresponding author.

E-mail address: alameluvvarsha96@gmail.com (A. V. Muthuraman).

done 19 years back. She has systemic hypertension and ischemic heart disease for the past 10 years and she was on treatment for the same. Patient had significant history of operative interference two times in the past. After one year, total abdominal hysterectomy with bilateral salpingo-oophorectomy was performed with a probable diagnosis of chronic cervicitis and cervical polyp, she had normal pap smear report, intraoperatively no specific findings were noted. Histopathology was suggestive of chronic nonspecific cervicitis, proliferative phase endometrium, Leiomyomatous polyp in cervical canal. Patient came twice in a gap of one month for follow up no complaints and vaults was healthy. In January 2022, patient came with complaints of PV bleeding for 2 days and found to have hyperemic polypoid growth from vault of size 6x6 cm. There was an intra-abdominal extension of the mass. The mass was removed Laparoscopically considering the age and comorbidity.

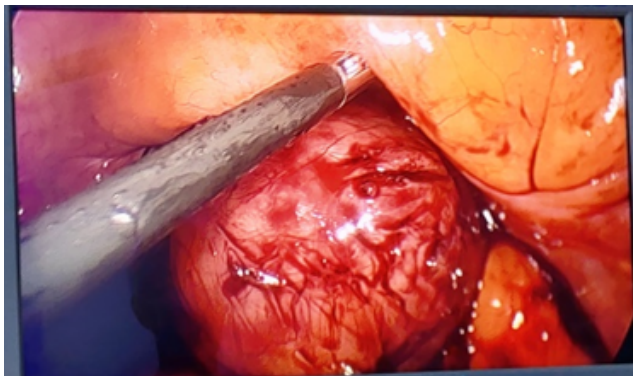


Fig. 1: Laparoscopic excision of mass

Sample has been sent for histopathology and suggestive of mitotically active leiomyoma. On examination at our unit the patient was generally well and systemic examination revealed no abnormalities. On per speculum examination hyperemic polypoid growth, highly vascular, bleed on touch. On pre vaginal examination same mass felt, lay firm to hard consistency of 7 x 6 cm, mass felt in anterior fornix which is nontender and fixed. On per rectal examination same mass felt and rectal mucosa is free.

Patient was investigated with routine preoperative profile. Ultrasound showed three well-defined solid lesion with hypervascularity in the pelvis posterior to urinary bladder and MRI abdomen and pelvis showed evidence of well-defined lesions of altered signal intensities arising from vault measuring 47 (CC) x 46 (TR) x 50 (AP) mm, 47 (AP) x 51 (CC) x 51 (TR) mm and 18 (AP) x 23(CC) x 23(TR) mm, these lesions were interconnected with each other (latter two lesions were situated posterior to former lesion). They appeared hypointense on T1, heterogeneously hyperintense on T2 & STIR and showed enhancement on post contrast study with few non enhancing areas within –

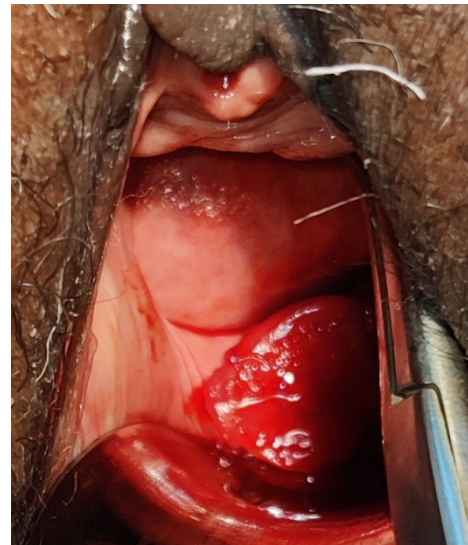


Fig. 2: Hyperemic polypoid growth seen on per speculum examination

Suggestive of fibroid from vault, which was not concerning for malignancy.

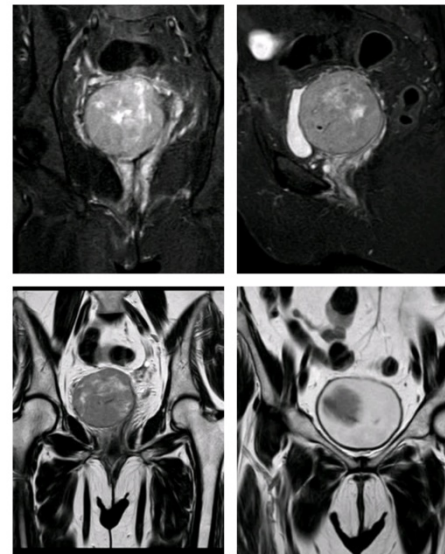


Fig. 3: MRI (Abdomen with Pelvis) plain and contrast

Biopsy had been taken from the vault growth and sent for histopathology found to be Leiomyosarcoma from vault, coagulative necrosis present, mitotic activity $> 5 / \text{mm}^2$ in hot spots. Intra-operative findings were a mass in the vault of vagina adherent to the urinary bladder and rectum. Mass separated from the bladder. Bladder accidentally opened and sutured in two layers. Vagina dissected low down. Vagina removed with vaginal mass with adequate margins. Vagina mobilized and reconstructed. In small bowel there were

two pieces of nodular tissue together measuring 3 x 2 x 1.2 cm. Specimen of radical vaginectomy, revised vaginal margin, small bowel deposit and vaginal polyp were sent to histopathology.

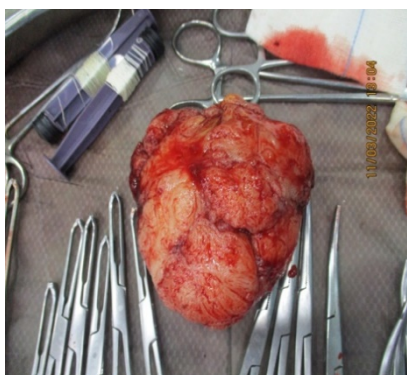

Fig. 4: Mass excised from vault

On Gross- Radical vaginectomy specimen in three pieces, the largest represents nodular mass measuring 9 x 8 x 8 cm. External surface is smooth, rough and bosselated. Cut section shows yellowish grey fleshy appearance with areas of hemorrhage, necrosis and few myxoid areas. Similar lesions were seen on small bowel. On histopathology it revealed Spindle cell sarcoma, suggestive of Leiomyosarcoma with moderate to severe cytologic atypia and increased mitotic activity (focally more than 10 high power field) with focal coagulative necrosis, histological grade was high, tumor borders are infiltrative, revised vaginal margins and vaginal polyp along with small bowel shows tumor.

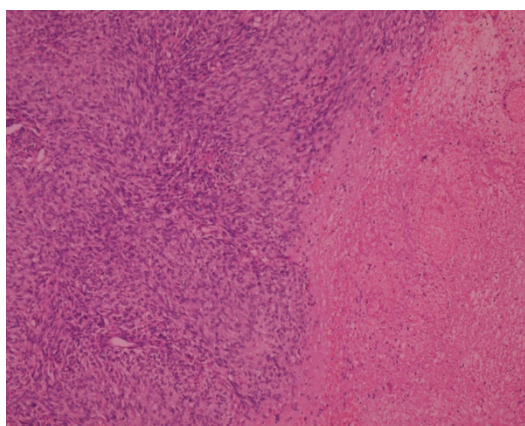


Fig. 5: Slide showing bizarre changes

Immunohistochemical stains were positive for Vimentin, Desmin and SMA in tumor cells and were negative for S100, Melan – A, Myogenin and cytokeratin AE 1/3. An immunohistochemical stains for Ki – 67 was positive and suggested an increased proliferative index (10–15%).

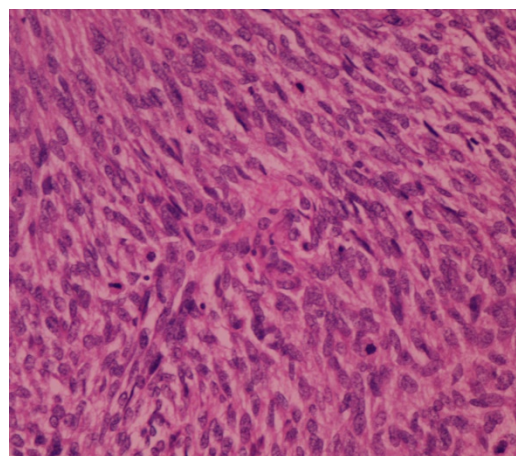


Fig. 6: Slide showing pleomorphic structures and mitotic figures

Surgical resection in sum showed presence of disease in the vagina and metastasis to small bowel, making the final diagnosis Metastatic Leiomyosarcoma of vault. Post – operatively whole body PET CT + regional PET MRI scan was done, FDG avid lesions in vaginal stump with pelvic serosal deposit suggesting “residual viable disease”. No FDG avid distant organ was involved. Post – operatively patient was planned for Radiotherapy followed by chemotherapy. Now patient is undergoing Radiotherapy treatment.

3. Discussion

Leiomyosarcoma arising from vault post-hysterectomy in a case of mitotically active leiomyoma as we know is rare. Leiomyosarcoma is a malignant smooth muscle tumor and is rare form of malignancy with poor prognosis. It accounts for 2-5% of all malignancies.¹ Leiomyosarcoma are most common type of sarcomas accounting for 25-36% of uterine sarcomas.^{2,3} It is most commonly seen in involuntary muscle, uterus, stomach, intestine, retro peritoneum, walls of blood vessels and skin. Leiomyosarcoma have a primary site of origin anywhere in body where there is blood supply. Signs and symptoms consist of pain in the abdomen, abdominal distention, postmenopausal per vaginal bleeding, unintentional weight loss.⁴

Prognosis depends on extent of spread, age, histological type, tumor size, lymph node metastasis.⁵ Tumor more than 5 cm has poor prognosis.⁶ Metastasis occurs in the lung, brain, liver, bones.⁷

Mitotically active leiomyomas occurs commonly in perimenopausal age group, their size is generally small (measuring less than 10 cm in maximum dimension), the morphological aspects of the ordinary leiomyoma apart from a mitotic activity exceeding 5 mitoses per 10 fields examined at high magnification, without atypia or necrosis.^{8,9}

Leiomyomas which are hypercellular suggest the diagnosis of Leiomyosarcoma. Atypical leiomyoma is considered as smooth muscle tumor of uncertain malignant potential (STUMP). This term was first used in the literature by Kempson in 1973.¹⁰

Imaging modalities like CT and MRI are not reliable diagnostic tools.¹¹ Diagnosis of Leiomyosarcoma is made microscopically.

On microscopic examination the coagulation tumor cell necrosis with hyper cellularity and abundant mitosis (> 10 MF / 10 HPF), presence of aneuploidy, high MIB-1 activity and negative p53 and show focal 'bizarre' changes. It also shows atypia on cytology which is also a diagnostic tool.

Staging of Leiomyosarcoma is surgical and local growth of leiomyosarcoma is its unique feature. Leiomyosarcoma extending beyond uterus and cervix has a poor prognosis.

Management consists of surgery, chemotherapy and radiotherapy. Neoadjuvant chemotherapy is used in advanced diseases. Single agent of doxorubicin is effective for advanced cases.¹² This case is unique because the mitotically active leiomyoma which have potential to undergo malignant changes was converted into leiomyosarcoma which is a very rare occurrence.

4. Conclusion

This case report describes a woman with an unexpected leiomyosarcoma, one year after the removal of the uterus without any macroscopic intraabdominal metastasis. This case shows that a leiomyosarcoma always has to be considered in case of a suspect tumor in the lower abdomen, even after previous removal of uterus.

5. Source of Funding

None.

6. Conflict of Interest

None.

References

1. Forney JP, Buschbaum HJ. Classifying staging and treating uterine sarcomas. *Contemporary Ob Gyn*. 1981;18(3):47–69.
2. Norris HJ, Zalouder CJ. Mesenchymal tumour of uterus. In: Blaustein A, editor. Pathology of female genital tract. New York: Springer-Verlag Books; 1982. p. 352–92.
3. Eht G, Jepson J, Steel J, Langholz B, Luxton G. Treatment of uterine sarcomas. *Cancer*. 1990;66:35–9.
4. Wickerham DL, Fisher B, Wolmark N, Bryant J, Costantino J, Bernstein L, et al. Association of tamoxifen and uterine sarcoma. *J Clin Oncol*. 2002;20(11):2758–60.
5. Major FJ, Blessing JA, Silverberg SG, Morrow CP, Creasman WT, Currie JL, et al. Prognostic factors in early stage uterine sarcoma. A Gynaecologic Oncology group study. *Cancer*. 1993;71(4):1702–9.
6. Evans HL, Chawla SP, Simpson C, Finn KP. Smooth muscle neoplasms of the uterus other than ordinary leiomyoma. A study of 46 cases, with emphasis on diagnostic criteria and prognostic factors. *Cancer*. 1988;62(10):2239–47.
7. D'Angelo E, Prat J. Uterine sarcomas: a review. *Gynecol Oncol*. 2010;116(1):131–9.
8. Prayson RA, Hart WR. Mitotically active leiomyomas of the uterus. *Am J Clin Pathol*. 1992;97(1):14–20.
9. Perrone T, Dehner LP. Prognostically favorable "mitotically active" smooth-muscle tumors of the uterus. A clinicopathologic study of ten cases. *Am J Surg Pathol*. 1988;12(1):1–8.
10. Kempson RL. Sarcoma and related neoplasms. In: Norris HJ, Heritig AT, Abell MR, editors. The uterus. Baltimore: Williams and Wilkins; 1973.
11. Pha SE, Byun JY, Jung SE, Lee SL, Cho SM, Hwang SS, et al. CT and MRI of uterine sarcoma and their mimickers. *AJR Am J Roentgenol*. 2003;181(5):1369–74.
12. Piver MS, Lele SB, Marchetti DL, Emrich LJ. Effect of adjuvant chemotherapy on time to recurrence and survival of stage I uterine sarcomas. *J Surg Oncol*. 1988;38(4):233–9.

Author biography

S A Deshpande, Professor

Alamelu Varsha Muthuraman, Post Graduate

Cite this article: Deshpande SA, Muthuraman AV. Metastatic leiomyosarcoma of vault post – hysterectomy. *Indian J Obstet Gynecol Res* 2022;9(3):438-441.