

Content available at: <https://www.ipinnovative.com/open-access-journals>

Indian Journal of Obstetrics and Gynecology Research

Journal homepage: www.ijogr.org

Review Article

Accessory cavitated uterine malformation (ACUM): A hidden face of dysmenorrhea

Rana Mondal^{1,*}, Priya Bhawe¹

¹Bansal Hospital, Bhopal, Madhya Pradesh, India



ARTICLE INFO

Article history:

Received 09-08-2022

Accepted 17-08-2022

Available online 08-11-2022

Keywords:

Accessory cavitated uterine malformations

Dysmenorrhoea

Mullerian anomaly

Dyspareunia

ABSTRACT

Background: Accessory cavitated uterine malformations, or mass (ACUM) is a Mullerian anomaly which increasingly recognized as a cause of severe dysmenorrhoea and pelvic pain.

Objective: To know what ACUMs are and recognize their clinical presentation, able to diagnose an ACUM using ultrasound or MRI; and counsel patients with ACUMs on the different management options, including conservative, medical, and surgery.

Conclusion and Wider Implication: ACUMs are less rare than previously believed; hence ACUM diagnosis is essential in clinically suspicious cases via ultrasound and MRI, and intra-operative assessment of uterine morphology and laparoscopic surgical excision is the definitive treatment for ACUM.

This is an Open Access (OA) journal, and articles are distributed under the terms of the [Creative Commons Attribution-NonCommercial-ShareAlike 4.0 License](https://creativecommons.org/licenses/by-nc-sa/4.0/), which allows others to remix, tweak, and build upon the work non-commercially, as long as appropriate credit is given and the new creations are licensed under the identical terms.

For reprints contact: reprint@ipinnovative.com

1. Introduction

From the literature earliest description of an accessory cavitated uterine mass (ACUM) was given by J.Oliver in the year 1912 when he described a patient presenting with dysmenorrhoea who underwent surgical excision of a tumor from the broad ligament, which was described as "a globular-shaped closed sac, containing chocolate-colored fluid, thick-walled and lined by cuboidal epithelium, which resembled very closely the stroma of normal endometrium".¹ However, throughout the last century, there are not many descriptions regarding this entity until the last two decades, and only occasional case reports have been found throughout the literature. In 2010 P Acien and colleagues described this entity in a case series format² and again in 2012 described this entity as accessory cavitated uterine mass (ACUM) and also discussed this entity's management and origin and pathology subsequent review of case reports.³ Since the last decade, ACUM

has been more recognized myometrial pathology, probably because of increasing awareness among the surgeon and improved imaging technologies that can recognize more of these cases. ACUM has been considered a cause of dysmenorrhoea, especially in young women, and thus young women presenting with severe dysmenorrhoea often with deterioration of the quality-of-life ACUM should be considered. However, there is no known prevalence of this disease, especially in young women, as we can only find the case reports of these entities, and there are no prospective studies to know the incidence or prevalence of the disease. ACUM also can be called 'accessory cavitated uterine malformation' as this truly represents congenital developmental abnormality and omits the negative connotation that the word 'mass' processes. However, the word 'accessory cavitated uterine mass' is more popular; hence we used it. Here we will describe some of these cases we encountered in our practice in recent years and then a short review regarding various aspects of ACUM. (Figure 1)

* Corresponding author.

E-mail address: mondalrana099@gmail.com (R. Mondal).

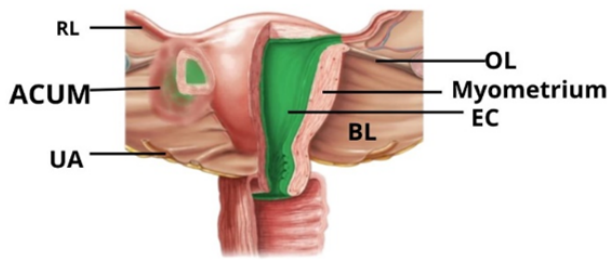


Fig. 1: Diagrammatic representation of ACUM. R.L. Round ligament, ACUM accessory cavitated uterine mass, UA uterine artery, OL ovarian ligament, EC normal endometrial cavity, BL broad ligament

2. Epidemiology

Most of the pieces of literature regarding ACUM are based on the case series and case reports, so the exact characteristic population is not well-defined. Due to the scarcity of cases, the precise prevalence of this condition is not determined. Not only due to the scarce condition but also lack of awareness among the clinicians, we often miss the diagnosis of ACUM. Most authors proposed that ACUM can be recognized only in a nulliparous young woman aged less than 30 years presenting dysmenorrhoea.^{2–5} Although most of the cases found are in women less than 30 years of age, there have been reports that ACUM can also be found in more advanced ages.^{3,6–8} Patients with ACUM do not always need to have dysmenorrhea. ACUM can be seen in asymptomatic women diagnosed incidentally and may have other symptoms like dyspareunia. This condition is probably present in every population, and lack of awareness is perhaps the reason for the low number of diagnosed cases other than the condition's rarity. On reviewing the literature, this condition is more commonly diagnosed in the Japanese population probably due to the excellent awareness of the clinicians in Japan rather than a genuinely increased prevalence of the condition within this population.^{5,9–14}

3. Aetiology

There are two theories regarding ACUM development:¹ an isolated Müllerian duct malformation or² dysfunction of the female gubernaculum. According to the first theory, there is duplication or persistence of an isolated Müllerian duct segment at the level of the attachment of the round ligament. The gubernaculum is composed of muscular fibers that probably derive from the abdominal wall, and when it is fixed and fused with the Müllerian ducts, it grows over the Müllerian ducts. Above this, the Müllerian ducts will give origin to the fallopian tubes, whereas the Müllerian ducts form the normal uterus medially at the point of insertion of the gubernaculum. Sometimes an isolated or duplicated Müllerian part may present here and can give rise to ACUM.

Due to gubernaculum malfunction, migration and fusion of the Müllerian segment may remain incomplete and give rise to ACUM. Probably this may be the reason ACUM seats underneath round ligament.^{2,3,15}

4. Nomenclature

What we describe as accessory cavitated uterine mass (ACUM) is certainly not a new entity, although, in the last decade, it has been more commonly recognized by this name. In the previously published literature, various names were used, as shown in Table 1. In 2010, Acién et al. reviewed the literature to determine how many published cases represented true ACUMs according to their proposed criteria, and since then, ACUM has been a more popularised name. Accessory cavitated uterine malformations are also proposed by some authors⁸ as so it more suits as the condition persists from birth as a malformation¹⁶ and also indicates the benign nature of the condition and omits the negative connotation that the word 'mass' as a matter of fact for some patient term 'mass' may add extra stress on them.

Table 1: Different names available for ACUM

ACUM, also known as	References
Juvenile cystic adenomyoma	5,13,14,17–24
Isolated cystic adenomyoma	4,10–12,25–27
Uterine-like mass	28–30
Accessory uterine cavity	1,31,32
Adenomyotic cyst	20
Accessory cavitated uterine malformations	8
Cystic myometrial lesion	33
Uterine Cystic Adenomyosis	34

5. Clinical Presentation

Approximately 7% of young women have an anatomical abnormality in their reproductive tract; the most frequent symptom of this is intolerable pain.³⁵ In the review of our cases, although the commonest presentation of the ACUM is dysmenorrhoea, they can also present with dyspareunia, dyschezia, and also there may be other pressure symptoms. Moreover, many patients may be asymptomatic and may be found incidentally during diagnostic hysterolaparoscopy for other indications such as infertility and pelvic pain. On reviewing the published literature, there is no doubt that the most common presentation of ACUM is dysmenorrhoea.^{2,3,7,8,13,14,17,20,24,36–41} The pain is usually felt in the ipsilateral site or the central pelvic area, especially during menstruation, and may also proceed the days before menstruation and may be accompanied by chronic pelvic pain.^{2,3,8,29,36,37,41,42} Functional endometrial lining present in the accessory uterine cavity causes secretion of menstrual fluid during the period, and as the secreted fluid is placed in an enclosed space; it gets accumulated during the menstrual time, which during

surgery we found as chocolate material inside the mass and chronic accumulation of this fluid leads to increased pressure within the cavity, and subsequent stretching of the cavity which produces pressure effect on the nerve fibers that are causing the pain and chronic stretched out cavity is the reason for having chronic pelvic pain. However, often pain persists and increases during or even after the onset of menstruation.^{3,9,10,13,20,21,27,28,36,37} other symptoms reported by the patients diagnosed with ACUM are dyspareunia,^{2,5,40} dyschezia,^{12,25,40} and hypogastric pain,^{2,3,36,37} but there is clear uncertainty regarding whether ACUM is the sole reason for these symptoms.

We do not have many descriptions regarding asymptomatic ACUM, but this population certainly does exist, as we have found in one incidental case of ACUM diagnosed during an infertility evaluation. ACUM can also be incidentally diagnosed during routine scanning done in pregnancy.⁸ No published literature mentions ACUM associated with infertility or heavy menstrual bleeding. Probably ACUM will not cause infertility as the endometrial cavity is normal in women with ACUM. Although ACUM is most commonly diagnosed in nulliparous women, it can also be found in parous women.^{3,31,43,44} Although it is challenging to suspect ACUM on clinical examination, some authors have described the woman who had a diagnosis of ACUM had present with clinically palpable, a tender mass that can be felt on abdominal on bimanual examination, and often this case mistaken as fibroid, endometrioma or ovarian cyst.^{2,12,13,25}

6. Investigations and Diagnosis

Diagnosis of ACUM is based on the assessment of uterine morphology, which can be done preoperatively by non-invasive diagnostic methods like ultrasound and MRI. Intraoperative assessment of uterine morphology is the definitive way of diagnosis and treatment, although it is invasive and not without complications. Postoperative assessment of tissue by histopathological examination adds up the icing to the diagnosis.

6.1. Ultrasound

Ultrasound, especially transvaginal ultrasound (TVS), remains the first-line weapon for the gynecologist to diagnose cases of ACUM but often, after TVS, we remain uncertain of the diagnosis of ACUM even on an expert hand, and the reason for that is mainly lack of awareness and often misdiagnosed as subserosal fibroid, degenerated fibroid and endometrioma. Critical diagnostic features of ACUM, according to available literature, are summarised below.

1. On ultrasound, ACUM appears well circumscribed. Spherical-shaped cavitated lesion containing echogenic fluid surrounded by the myometrial

mantle.^{8,13,14,42,44-50}

2. The myometrial mantle and the fluid-filled cavity are the defining features of ultrasound.^{8,45-48,51}
3. The fluid contained within the accessory cavity was either echogenic with a ground-glass appearance or hyperechoic.^{3,5,7,8,14,49,52} This may confuse with endometrioma especially considering young women presenting with dysmenorrhea or dyspareunia.
4. ACUM lesions are primarily spherical.⁵³
5. ACUM lesions are characteristically located in one of the lateral aspects of the anterior myometrium inferior to presumed insertion of the round ligament (3D ultrasound is helpful to locate the interstitial portion of the fallopian tube) and above the location of the uterine artery (on doppler).^{45,49,51,53}
6. On Doppler examination, the Doppler flow of the outer rim of the myometrial mantle will not be markedly different from that of the surrounding myometrium.⁵³
7. On Doppler examination, the content of the cavity will be avascular.^{45,52,53}
8. ACUM lesion will be independent of the normal endometrial cavity.
9. The normal uterus and bilateral ovaries are visualized separately.

In our experience, 3D ultrasound also contributes to the diagnosis. As ACUM can be mistaken for obstructive uterine and other Mullerian anomalies; to avoid this 3D reconstructed image showing a normal interstitial portion of the fallopian tube can confirm the diagnosis of the presence of a normal endometrial cavity and also gives us the idea that there is no communication between uterine cavity and this cavitated lesion. Reconstructed images allow us to visualize the interstitial portion of the fallopian tube, which helps us locate these lesions as they present caudal to the round ligament at the level of the fallopian tube. 3D reconstruction can rule out Mullerian anomalies as this differential diagnosis should be considered in such cases.^{45,45,49,50} Decidual changes observed in ectopic endometrial tissue within an adenomyotic area may be misdiagnosed as a focus of cornual ectopic pregnancy in such cases. Also, 3D images are helpful.⁵⁴

For some patients with ACUM, a transvaginal ultrasound may not be feasible. In such cases, transabdominal or transrectal ultrasound (TRUS) can also be used. In our experience, transabdominal ultrasound can also give us the diagnosis of ACUM (case-4). Transrectal ultrasound is also an acceptable alternative as this is very well tolerated, provides consistent image quality to the transvaginal ultrasound, and is probably superior to the transabdominal ultrasound.⁵⁵ TRUS is a good alternative for obese women with unacceptable vaginal scans.⁵⁵

According to a few authors, only doing TVS is good enough to make the diagnosis of ACUM,⁵³ but others usually request an additional non-invasive imaging modality

to make the diagnosis of ACUM.^{3,36,49,52}

6.2. Magnetic resonance imaging

Most of the published literature regarding sqm has been investigated by magnetic resonance imaging MRI, and in our experience, MRI is a good enough tool to make the diagnosis. MRI can be used to determine the lesion location within or adjacent to the uterus, its size, morphology (shape and boundaries), and also can report signal and enhancement of its different parts compared to the myometrium. Moreover, an associated urogenital malformation or Mullerian gynecological anomaly can be diagnosed as it clearly shows the endometrial cavity and both cornua. MRI examinations include axial, coronal, and sagittal T2-weighted turbo spin echo images, T1-weighted spin-echo images, and axial fat-suppressed T1-weight images with 3–4-mm section thickness. According to available literature, important MRI features found in diagnosed cases of ACUM are summarised below.

1. The typical MR appearance ACUM is a large well-circumscribed round mass within the external myometrium, composed of an inner cystic hemorrhagic layer surrounded by a thick fibrous crown.^{36,43,52,56–59}
2. This cavitated solid nodule mass with cystic (hemorrhagic) components located lateral to the uterus and caudal to insert round ligament and cranial of the uterine artery insertion.^{36,52,56,60}
3. The normal endometrial cavity, along with a normal size uterus, and there is no communication with the normal endometrial cavity.⁵⁷
4. The central hemorrhagic cavity is surrounded by a regular ring with the same signal as the junctional zone.³⁶
5. The cavity will have a thin inner lining that is moderately enhanced after gadolinium contrast and appears hyperintense on T2- weighted images, indistinct from the endometrium.³⁶
6. The myometrial mantle surrounding the cavity is seen as thickened and hypointense tissue on T2-weighted images, demonstrating myometrial hypertrophy.^{51,59}
7. The internal content inside the cavities will have high T1 signal intensity and remain after fat saturation, indicative of hemorrhagic content.^{5,21,24,27,47}

In summary, on MRI, ACUM resembles a non-communicating functional accessory horn within or adjacent to a normal uterus. This mass, most often round-shaped, had a central hemorrhagic cavity surrounded by a regular ring with the same low signal compared to the uterine junctional zone.^{36,48,52} Therefore, MRI can be considered a reliable diagnostic tool for diagnosing ACUM. More importantly, it can also rule out other important causes of pelvic pain like adenomyosis and endometriosis

and other imaging differentials like adenomyoma, non-communicating uterine horn, and degenerating leiomyoma.

6.3. HSG, SIS and HyCoSy

In the past, many authors proposed that to diagnose ACUM, one should rule out the abnormal uterine cavity and congenital uterine anomaly and establish the non-communicating nature of the lesion. Thus they used hysterosalpingography (HSG), Hysterosalpingocontrast-sonography (HyCoSy), or saline infusion sonohysterography (SIS), which are well popular methods to establish normal uterine cavity and fallopian tubes.^{2,3,5,7,10–13,17,23,42} We do not use such methods in our practice.

6.3.1. Assessment of intraoperative uterine morphology

Diagnostic hysterolaparoscopy is one of the optimal modes of diagnosis and treatment for patients with ACUM. In most cases, ACUM appears as a fibroid-looking mass from the outside. An ACUM appears as an asymmetrical uterine bulge on the anterolateral aspect of the uterus caudal to the insertion of ipsilateral round ligament and cranial to the cervico-isthmic junction or insertion of the uterine artery and classically contains altered collected blood secreted from the functional the endometrium lined inside the cavity which appears as a chocolate color fluid on opening the cavity.^{2,3,7,15,37} Although hysteroscopy is not necessary for ACUM, it helps us to know whether the endometrial cavity is normal or not and rules out any presence of communication, and also rules out any obstructive causes of Mullerian anomaly. In our experience, intraoperative diagnosis of ACUM can be made by its characteristic location and morphology.

Diagnosis of ACUM is often delayed as we think delayed ACUM in women in dysmenorrhea is probably due to a lower incidence of ACUM. This is evident by the fact that many documented cases of ACUM published in the literature were undergone diagnostic laparoscopies that failed to diagnose ACUM.^{2,19,28,53} Even on laparoscopy (or sometimes on laparotomy) ACUM one may find it difficult to diagnose¹¹ as from the outside, it often looks like a fibroid (although characteristically placed), and the hysteroscopy cavity will be perfectly normal, so the clinician should actively look for ACUM, especially in young nulliparous women with dysmenorrhea. Sometimes intraoperative ultrasound can be useful to locate ACUM successfully and aid excision from a normal uterus.^{8,10,11,52}

6.4. Histology

Macroscopically excised specimens of ACUM have a uterus-like organization with a central cavity lined by endometrium with hemorrhagic content surrounded by myometrial tissue similar to the myometrium of a healthy

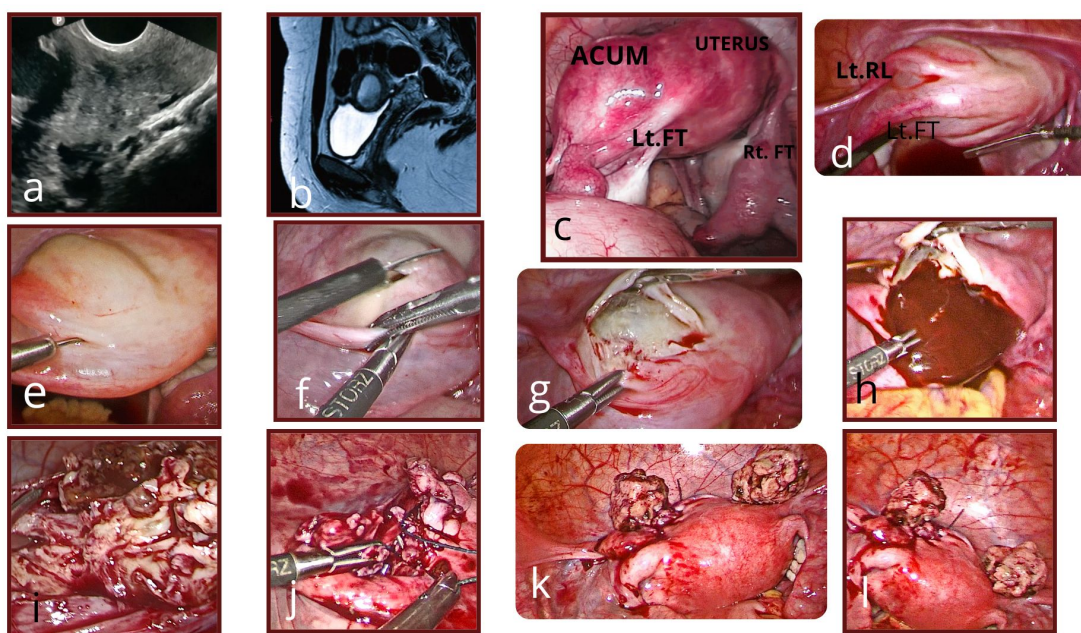


Fig. 2: ACUM (a) Demonstrates a solid mass with a cystic cavity along the uterine wall. (b) T2 weighted MRI showing an accessory cavitated mass along the uterine wall under the round ligament with T2 hyperintense blood degradation products. (c,d) accessory cavitated mass seen caudal to the insertion of left round ligament and in front of the ipsilateral fallopian tube and cranial to the uterocervical junction. (e,f,g) vasopressin was injected sub-serosally at the junction of mass and normal uterus until the whole mass blanches out and the dissection started to excise the mass. (h) characteristic chocolate-colored material inside the cavity seen drained out indicates the presence of functional endometrium. (i) mass is excised, and there was no definitive plane between the uterus and the mass. (j,k,l) after careful inspection of excised bed, a single layer running suture was used to approximate the defect and restore normal uterine anatomy

uterus.^{13,36,53}

On microscopic examination cavity of ACUM is lined by an endometrial gland and stroma. Similar to normal endometrium, they also positively stain for CD10, estrogen receptors (ER), and progesterone receptors (PR).^{5,36}

Often we can get reports of focal adenomyosis in the resected specimen of ACUM.^{2,3,5,10,14} This is due to prolonged blood collection within the cavity causing adenomyotic changes.

The condition may be confused with cystic adenomyosis, where the cysts are usually quite small and do not possess a typical endometrial lining or uterus-like muscle, as seen in ACUM. Although there are no definitive criteria to differentiate ACUM from cystic adenomyosis, well ordered concentric organization of smooth muscle fibers seen in ACUM can differentiate them from cystic adenomyosis, where the smooth muscle fibers are disorganized.^{36,53} The main uterus does not possess features of adenomyosis, but the myometrium of ACUM may show features of adenomyosis.

7. Key to Diagnosis

Diagnosis of ACUM often remains challenging, possibly because it is not a common clinical condition we often encounter daily in our clinic. Even with the advancement

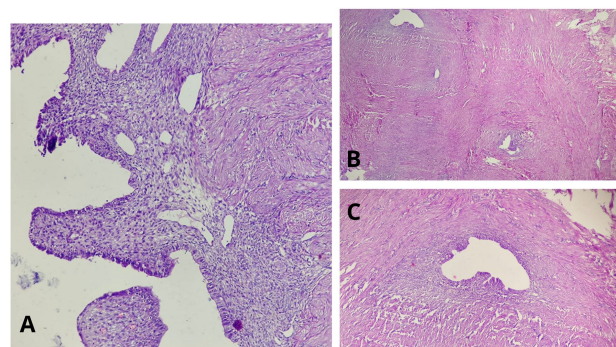


Fig. 3: Histopathology. A: Central cavity lined with functional endometrium and surrounded by smooth muscle (hematoxylin and eosin staining). B, C: Foci of endometrial glands and stroma interspersed between myometrial tissue

of ultrasonography, including 3D ultrasonography and MR imaging, there remains diagnostic confusion regarding ACUM. Usually, during surgery, intra-operative uterine morphology assessment is sufficient enough to diagnose ACUM, and corresponding histopathological findings add up value to the diagnosis. Often a high index suspicion is necessary to diagnose the case of ACUM. Whenever a young and nulliparous patient presents with severe

Table 2: Key diagnostic features of ACUM

Method	Key Diagnostic features
Clinical presentation	1. High index suspicion should be given to young (usually < 30 years) and nulliparous women presenting with severe dysmenorrhea.
Ultrasonography	<ol style="list-style-type: none"> 1. On ultrasound, ACUM appears well circumscribed, spherical-shaped cavitated lesion containing echogenic fluid surrounded by the myometrial mantle. Both the myometrial mantle and the fluid-filled cavity were considered to be defining features of the ultrasound.. 2. Location of the myometrial mantle: cranial to the uterine artery on color doppler and caudal to the interstitial portion of the ipsilateral fallopian tube. 3. The presence of vascularity within the myometrial substance but absence within the cavitated part of the lesion. 4. The Doppler flow observed in the outer rim of the myometrial mantle is not markedly different from that of the surrounding myometrium 5. This lesion is independent of the normal endometrial cavity. 6. Normal uterus, fallopian tubes, and ovaries.
MRI	<ol style="list-style-type: none"> 1. Nodular solid uterine lesion located lateral to uterine wall; (a) on the lateral view, caudal to the round ligament insertion and cranial of the uterine artery insertion, and (b) in transverse view, at or below the level of the uterine round ligament and the ipsilateral fallopian tube as a bulge of intra-myometrial and in the broad ligament. 2. The central hemorrhagic cavity is surrounded by a regular ring which has the same signal compared to the junctional zone. This lesion is independent of the normal endometrial cavity. 3. T1- weighted images show the cyst within the adnexal mass as an area of high signal intensity, while T2-weighted images show it as an area of low signal intensity.
Surgical (intra-operative uterine morphology assessment)	<p>Location:</p> <ol style="list-style-type: none"> 1. Solitary mass lesion located anterolateral to uterine wall caudal to the round ligament insertion and cranial of the uterine artery insertion (above uterocervical junction) and may bulged into the broad ligament, and ipsilateral fallopian tube is posterior to mass. 2. No communication with the uterine cavity or fallopian tubes (can be confirmed by hysteroscopy where hysteroscopic findings consist of a normal uterus) <p>Morphology:</p> <ol style="list-style-type: none"> 1. A cavitated lesion containing functional endometrium (evidenced by chocolate-colored hemorrhagic content inside the cavity) is surrounded by a myometrial tissue similar to healthy uterine tissue.
Histopathological	<ol style="list-style-type: none"> 1. The specimen consists of smooth tissue with endometrial glands and blood. The inner layer of the cavity was lined by endometrial glandular epithelial cells and stroma, and the outer layer appeared similar to normal myometrium. Two key pathognomonic findings to be seen are- <ol style="list-style-type: none"> a. Lined with functional endometrium b. Myometrial tissue that has a concentric organization of smooth muscle

dysmenorrhoea primarily affecting her quality of life, one should add ACUM to the bucket list of their differential diagnosis. Important diagnostic indications are given in Table 3 that we used in our practice.

8. Differential Diagnosis

Clinicians often find the diagnosis of ACUM a challenge, possibly due to unfamiliarity with the condition, and it is better to keep this on the bucket list of differential diagnoses

when young women present with severe dysmenorrhea. Differential diagnosis of ACUM includes non-obstructive congenital uterine anomaly such as unicornuate uterus with rudimentary horn or Robert's uterus, subserosal fibroid or degenerated fibroid, cystic adenomyosis, congenital uterine cyst or myometrial cyst, and ovarian endometrioma.

Table 3: Differential diagnosis of ACUM

	Definition	Clinical features	Pathology	Ultrasound	MRI	Treatment	Histopathology
Accessory cavitated uterine mass	Isolated accessory cavitated mass surrounded by the myometrial mantle Present at the level of round ligament insertion. It is associated with a normal-shaped and functional uterus without communicating to a normal endometrial cavity.	Mostly young and nulliparous women with severe dysmenorrhea.	Mullerian anomaly without uterine malformation caused by duplication and persistence of the ductal Müllerian tissue at the insertion of the round ligament is believed to be due to the gubernaculum dysfunction.	ACUM appears well circumscribed, spherical-shaped cavitated lesion containing echogenic fluid surrounded by the myometrial mantle. Therefore, the myometrial mantle and the fluid-filled cavity were considered to be defining features of the ultrasound.	A nodular uterine lesion with a central cavity containing a cystic component and hemorrhagic content. Hyperintense signal on T1-weighted images. Hypointense signal on T2-weighted images and independent from the normal endometrial cavity.	Laparoscopic excision of the mass is the definitive treatment. Also, conservative management is possible.	Endometrioid epithelium lines the cavity. Epithelial glands and stroma lined the cavity, surrounded by smooth muscle cells.
True cavitated or cystic adenomyoma	Focal adenomyosis that is not in direct continuity with the junctional zone. Has central degeneration and endometriotic fluid accumulation.	Common among older women. They are often associated with fibroids. Presents with heavy, painful periods.	Invagination of the endometrial basalis layer into the myometrium.	Anechoic cyst within the intramural region with aromatic changes seen in the uterus.	Hypointense mass on T2-weighted images. Ill-defined borders, minimal mass effect, multiple bright foci.	Medical management, including hormonal therapies and Mirena insertion. In severe cases, hysterectomy.	Lack of uterus-like smooth muscle organization. Diffusely spread adenomyotic foci in the uterus corpus.
Congenital uterine cyst	Epithelial-lined cysts at variable locations within the myometrium containing simple fluid.	Usually asymptomatic but may cause dysmenorrhoea. Often incidental finding.	Misplaced pluripotent Mullerian remnants.	Appears any anechoic cyst on ultrasound without any color flow surrounding it.	Hypointense fluid-filled mass within the myometrial region.	Often no treatment is required as they are asymptomatic and only found incidentally.	Epithelial-lined cysts with a lack of haemosiderin rim.

Continued on next page

Table 3 continued

Non-communicating rudimentary uterine horn	An isolated cavity fallopian tube attached to it without communicating with the actual cavity. Most unicornuate uteri are associated with a rudimentary uterine horn.	Usually asymptomatic but may cause dysmenorrhoea. Often incidental finding. Sometimes detected during an infertility evaluation. May have a history of miscarriage and recurrent pregnancy loss.	The Mullerian anomaly with a uterine malformation is due to the failure of one of the Mullerian ducts to elongate towards the urogenital sinus while simultaneously contralateral Mullerian duct develops normally.	External uterine fundal contour is not well visualized in 2D ultrasound. However, 3D pelvic ultrasound is helpful as the isthmic portion of the fallopian tube and endometrial cavity well demarcation possible.	The unicornuate uterus is displaced off the midline with normal myometrial zonal anatomy and regular endometrial-to-myometrial width and ratio.	Often no treatment is required. The true uterine cavity only has one fallopian tube. Hysteroscopy shows a single tubal ostium.	Thick myometrial wall. Cavity lined by endometrial.
--	---	--	---	--	---	--	---

Continued on next page

Table 3 continued

Subserosal or degenerated fibroid	Uterine fibroids are benign growths made up of the muscle and connective tissue from the uterus wall. However, fibroids can undergo various forms of degeneration like hyaline, cystic, myxoid, and red.	It can have many clinical features, from asymptomatic to heavy menstrual bleeding and dysmenorrhea dyspareunia. However, subserosal fibroid usually remains asymptomatic, which can cause pressure symptoms if it becomes enormous.	Benign monoclonal lesions mainly comprise smooth muscle cells and fibrous connective tissue.	A fibroid is usually hypoechoic lesions with peripheral blood flow on color doppler. Unless there is degeneration, they do not show any collection within them.	Cystic degeneration shows isointense relative to myometrium on T1; hyperintensity with lack of contrast enhancement of the internal areas on T2. Hemorrhagic degeneration shows hyperintensity on T1 and moderate-to-high intensity on T2. Hyaline degeneration appears isointense on T1 and hypointense on T2, similar to non-degenerated fibroids. Fatty degeneration is consistent with fat on MRI.	It can be managed expectantly; treatment is required only when a patient is symptomatic. It has many treatments, such as simple hormonal contraceptive pills. Mirena insertion. A large fibroid can be managed by myomectomy. Treatment depends on the site, size, and symptoms of the myoma.	A large extracellular matrix is surrounded by a thin pseudocapsule of areolar tissue and compressed smooth muscle fibers. The degenerated fibroid comprises fascicles of elongated smooth muscle cells with eosinophilic cytoplasm and a centrally located cigar-shaped nucleus. It is rich in the vasculature of various calibers and types, including muscle-rich arteries, arterioles, and veins.
-----------------------------------	--	---	--	---	--	---	--

9. Treatment

Various treatment options are available for ACUM, ranging from simple analgesia to complete surgical excision.⁸ According to the most published literature, ACUM is diagnosed chiefly based on its symptoms and is usually treated by surgical management but also other modalities of management such as expected management, medical therapies, and sclerotherapy can also be possible. We prefer surgical excision of ACUM from the normal uterus in our practice.

9.1. Expected management

Although the exact Natural History of foam is still unknown, it is considered a congenital malformation,²⁶ and most of the published cases of ACUM are reported to be benign conditions, so it is possible to be managed expectantly. Nevertheless, no published literature says that symptomatic patients with ACUM have been managed expectantly, probably because of the nature of this condition. Most of the time, patients present with severe dysmenorrhoea and other symptoms affecting their quality-of-life necessitating active management rather than expected management. Nevertheless, expected management is an option for a woman diagnosed with ACUM during pregnancy or incidentally. For example, in their study, Naftalin et al.⁵⁵ found 3 cases of ACUM diagnosed during pregnancy who underwent expectant management. Also, expectant management can be done in asymptomatic women diagnosed with ACUM (e.g., due to uterine evaluation for infertility).

9.2. Medical management

Hormonal treatment such as continuous use of oral contraceptive pills,^{21,22,31,32,34} levonorgestrel-releasing intrauterine system (Mirena),⁵³ and gonadotrophin-releasing hormone agonist (GnRH)^{5,10–13,22,36,51} can be used. Continuous use of suppressive hormonal treatment inhibits ovarian steroidogenesis. It prevents shedding of the endometrium, thus preventing the accumulation of the blood within the accessory uterine cavity, hence preventing the stretching of the cavity, which is the main reason for pain. In a published case series by Naftalin et al.,⁵³ more than half of the selected cohort wanted to avoid primary surgery and choose other options like hormonal treatment, and most of them achieved good enough pain relief to avoid surgery. There are also two other studies where diagnosed case ACUM in teenage girls used the oral contraceptive pill to suppress symptoms such as dysmenorrhoea, and their patients achieved adequate pain relief on 12 months of follow-up.^{21,33}

However, this medical treatment has two potential limitations, inadequate pain control and recurrence of symptoms after stopping therapy. According to many

authors, hormonal treatment is not a good option for women diagnosed with ACUM as they often have adequate pain control and require surgery.^{4,5,13,17,19,23,36} Many patients experience recurrence of their symptoms soon after stopping medical treatment.^{3,5,5,10–12,17,36,42,51} Sometimes clinicians blindly put patients with severe dysmenorrhoea on the oral contraceptive pill to suppress their suffering, and this causes a late diagnosis of ACUM. ACUM is primarily diagnosed in young women who often want to avoid surgery. So, although medical treatment is not a definitive treatment for these patients, they certainly have a role in management for those who do not want surgery or during the period of preoperative evaluation.

10. Surgical Excision

In our experience, surgical management of ACUM is the primary mode of treatment as it completely excises the lesion, and all the secondary symptoms caused by the ACUM, such as dysmenorrhoea, immediately disappear after the surgery. All published cases of surgery of ACUM have reported almost complete resolution of secondary dysmenorrhoea due to ACUM soon after surgery^{2,3,5,36,53} and remain pain-free until follow-up completion,^{4,6,9,17,32,42} which makes excision of ACUM a definitive treatment. Excision can be performed both via laparotomy and laparoscopically.

Laparotomy has all the advantages of open surgery, including quick and easy access. Furthermore, there is greater surgical precision in open surgery, and although ACUM has no definitive plane of dissection in open surgery, better enucleation of ACUM is feasible. Also, complete excision can be performed without spillage of its contents. Moreover, due to characteristic location of ACUM, it is close to vital structures like the uterine artery, urinary bladder, and endometrial cavity. Therefore, surgical excision without disturbing other structures is crucial, especially in young women. Acién et al.^{2,3} described cases of ACUM managed via laparotomy either by excision of ACUM or by hysterectomy for women with a separate indication of hysterectomy.

Laparoscopic excision of ACUM has been favored by many surgeons compared to open surgery because it has the advantages of quicker recovery with reduced postoperative pain, reduced incidence of abdominal adhesions, and also moreover less scar over the abdomen, especially in young women. Most authors believe that sufficient precision in enucleation or excision of ACUM can be managed laparoscopically without difficulty due to the availability of good energy source devices and neat and clean visualization during laparoscopy and fine dissection instruments.^{6,17,58,59,61–63}

We like to perform hysteroscopy before proceeding to laparoscopy to know the normal uterine cavity and rule out any communicating Mullerian anomaly.

Vasopressin infiltration into the uterine–ACUM junction sub-serosal interface to aid with hemostasis has been reported by most authors performing laparoscopic excision.^{5,7,10,11,13,14,17,18,42,44,59,63,64} We also, in our practice, use vasopressin infiltration not only to reduce hemostasis but also to enable easy dissection.

Dividing the round ligament to gain access to the ascending branch of the uterine artery reduces the risk of unintentional injury, had been proposed some authors.^{5,21,21,36,65} We do not think it is always required unless ACUM is too big and adhesions surround it.

Dissection of the ureterovesical fold has also been mentioned to facilitate safe access to the laterally placed ACUM.⁶⁵ But to our experience ACUM usually places cranial to uterocervical fold, and often there is no requirement of performing this extra step.

The overlying serosa and myometrial plane can be incised with a cold knife^{9,13,14,17} and monopolar energy source.^{4–6} We prefer to use a scissor for dissection as we do not know the extent of thermal damage, which can inadvertently injure normal endometrium. A bipolar energy device can also be used. Dissection devices should be chosen based on the surgeon's preference and comfort.

ACUM excision or preferably enucleation should be performed circumferentially along the ACUM–myometrial interface. In contrast to a myomectomy, where dissection advances along a pseudocapsule, no definitive dissection plane can be found, indicating that ACUM is a congenital malformation.^{3,24}

As the boundaries of an ACUM are unclear, intraoperative ultrasound has been described to facilitate delineation of the lesion and to aid excision by some authors.^{13,53,66} Intraoperative ultrasound can also help to avoid inadvertent breach of the uterine cavity. Peyron et al.³⁶ illustrated in their paper that the mean distance of the ACUM from the uterine cavity was 6 mm on MRI, and one can be breached into a normal endometrial cavity during surgical excision, which can have subsequent consequences such as the formation of intrauterine adhesions, development of adenomyosis, especially in young women. We also often perform an intraoperative pelvic ultrasound after excision of ACUM.

Few authors had described the intraoperative assessment of the integrity of the normal uterine cavity post-excision using methylene blue dye chromopertubation.^{20,32,36,65} We think performing a dye test before excision is also good enough as it demonstrates normal uterine cavity and bilateral tubal patency, and also, in cases of women having infertility simultaneously can establish tubal patency. Nevertheless, there is no evidence that ACUM in any way can cause infertility.

ACUM is considered a benign lesion, so most likely, there will not be any recognized hazard due to spillage of its contents. In some of our cases, there was a spillage of

contents during dissection, and on follow-up till now, no recognized complications so far from this.

Various techniques have been described for specimen retrieval, including the use of colpotomy,⁵ morcellation^{10,11,17,24,64} and specimen retrieval in endo bags.^{7,18,53,65} We mostly used power morcellation with or without an endo bag to retrieve the excised tissue.

11. Sclerotherapy

Sclerotherapy is an option for women who do not want to undergo surgery as their primary mode of treatment. The transvaginal ultrasound-guided aspiration and use of sclerotherapy for the treatment of ovarian cysts, including endometrioma, have gained popularity recently.^{67,68}

The principle of use of sclerotherapy remains the same whether it is for an ovarian cyst (endometrioma) or in cases of ACUM. Sclerotherapy is the therapeutic use of sclerosants that causes controlled destruction of undesired target tissues such as the endometrial lining of the accessory uterine cavity.⁶⁹ Sclerosant agents (ethanol, ethanolamine oleate, hypertonic such as saline, glucose, etc.) destroy the cavity lining, resulting in inflammatory changes and subsequent fibrosis of the endometrial lining with eventual obliteration of the accessory cavity.

Merviel et al. first described the use of ethanol sclerotherapy in a case diagnosed with ACUM.⁷⁰ In the study by Naftalin et al., four patients chose to have sclerotherapy and had sufficient pain relief on follow-up.⁵³ But later, half of them had a recurrence of secondary symptoms and underwent surgical management.

Transvaginal sclerotherapy is usually performed under general anesthesia and continuous ultrasound guidance. Usually, an 18 gauge needle is used under continuous ultrasound guidance after puncturing through the anterior vaginal wall, and then through a myometrial mantle needle is inserted into the cavity of the ACUM. First, a small amount of the intracavitary fluid is taken out and sent for cytopathological examination, and the remainder of the fluid is also drained out. Next, a sclerosant agent like 99% ethanol is installed in the cavity under ultrasound guidance, and the needle is withdrawn carefully.

Ethanol sclerotherapy can avoid uterine scarring and the secondary risk of uterine rupture.⁷⁰ Moreover, it avoids all the risks of major surgery. However, there is the risk of inadvertent leakage of sclerosant agents installed in the peritoneum.⁶⁸ This is a recognized complication in alcohol installation for ovarian endometrioma, possibly due to thin walls, but it is less likely in the case of ACUM, which is surrounded by thick myometrium. Certainly, ethanol sclerotherapy has a highly variable recurrence rate, and the risk of recurrence is higher in women treated with ethanol washing than in ethanol retention.⁶⁸

We currently do not use sclerotherapy in our practice, but certainly, this is an option for women with ACUM who

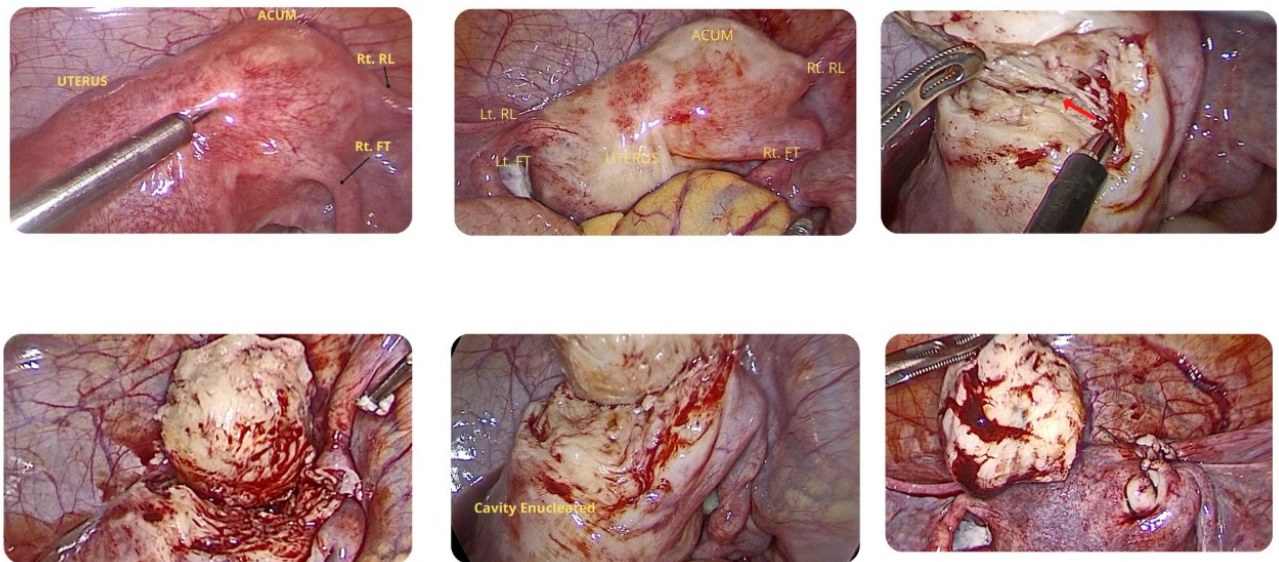


Fig. 4: ACUM is seen in the anterolateral aspect of the uterus adjacent to the insertion right round ligament (Rt.RL) and both fallopian tubes connected to the uterus (Rt. FT and Lt. FT), left round ligament inserted (Lt. RL) in the normal uterus. After subserosal injection, diluted vasopressin enucleation of the cavity is done. During dissection chocolate colored fluid is seen (red arrow), which is very characteristic of ACUM. After the excision of ACUM, the repair is done

do not want to have surgery. But they should be counseled that this is not a curative procedure, and there are variables risk of recurrence of the symptoms and may need another intervention in the near future.

12. Follow-Up

Currently, limited data is available to guide the patients with ACUM for follow-up. In our practice, we usually follow up one week after the surgery and then again at three months and 6 months with a pelvic ultrasound to see whether there is a recurrence of pain or not. As with most patients being young, follow-up is especially required for this group to know whether there is any effect on infertility and pregnancy.

13. Conclusion

ACUM is a recognized Mullerian anomaly that is habitually located underneath round ligament, with an unknown prevalence; that is probably related to a dysfunction of the female gubernaculum and is often underdiagnosed or commonly misdiagnosed as fibroid or obstructed cavitated rudimentary horn with unicornuate uterus due to a lack of knowledge and awareness about ACUM. ACUM is a less rare condition than previously believed; hence ACUM

diagnosis is essential in clinically suspicious cases. With a high index, clinical suspicion, and an appropriate diagnostic tool such as ultrasound and MRI, ACUM can be diagnosed. Laparoscopic surgical excision is the definitive treatment for ACUM as it is a benign condition. Further studies are required, especially a prospective study, to know their long-term effects on women's health, heavy menstrual bleeding and infertility, and whether surgical excision has any long-term consequences.

14. Source of Funding

None.

15. Conflict of Interest

None.

References

1. Oliver J. An accessory uterus distended with menstrual fluid enucleated from the substance of the right broad ligament. *Lancet*. 1912;179(4633):1609.
2. Ación P, Ación M, Fernández F, Mayol MJ, Aranda I. The Cavitated Accessory Uterine Mass: A Müllerian Anomaly in Women With an Otherwise Normal Uterus. *Obstet Gynecol*. 2010;116(5):1101–9.
3. Ación P, Bataller A, Fernández F, Ación MI, Rodríguez JM, Mayol MJ. New cases of accessory and cavitated uterine masses (ACUM): a

- significant cause of severe dysmenorrhea and recurrent pelvic pain in young women. *Hum Reprod.* 2012;27(3):683–94.
4. Protopapas A, Milingos S, Markaki S, Loutradis D, Haidopoulos D, Sotiropoulou M, et al. Cystic uterine tumors. *Gynecol Obstet Invest.* 2008;65(4):275–80.
 5. Takeuchi H, Kitade M, Kikuchi I, Kumakiri J, Kuroda K, Jinushi M. Diagnosis, laparoscopic management, and histopathologic findings of juvenile cystic adenomyoma: a review of nine cases. *Fertil Steril.* 2010;94(3):862–8.
 6. Peters A, Rindos NB, Guido RS, Donnellan NM. Uterine-sparing Laparoscopic Resection of Accessory Cavitated Uterine Masses. *J Minim Invasive Gynecol.* 2018;25(1):24–5.
 7. Supermaniam S, Thye WL. Diagnosis and laparoscopic excision of accessory cavitated uterine mass in young women: Two case reports. *Case Rep Womens Health.* 2020;26:e00187.
 8. Naftalin J, Bean E, Saridogan E, Barton-Smith P, Arora R, Jurkovic D. Imaging in gynecological disease (21): clinical and ultrasound characteristics of accessory cavitated uterine malformations. *Ultrasound Obstet Gynecol.* 2021;57(5):821–8.
 9. Tamura M, Fukaya T, Takaya R, Ip CW, Yajima A. Juvenile adenomyotic cyst of the corpus uteri with dysmenorrhea. *Tohoku J Exp Med.* 1996;178(3):339–383.
 10. Nabeshima H, Murakami T, Terada Y, Noda T, Yaegashi N, Okamura K. Total laparoscopic surgery of cystic adenomyoma under hydroultrasonographic monitoring. *J Am Assoc Gynecol Laparosc.* 2003;10(2):195–9.
 11. Nabeshima H, Murakami T, Nishimoto M, Sugawara N, Sato N. Successful total laparoscopic cystic adenomyomectomy after unsuccessful open surgery using transtrocar ultrasonographic guiding. *J Minim Invasive Gynecol.* 2008;15(2):227–30.
 12. Kamio M, Taguchi S, Oki T, Tsuji T, Iwamoto I, Yoshinaga M. Isolated adenomyotic cyst associated with severe dysmenorrhea. *J Obstet Gynaecol Res.* 2007;33(3):388–91.
 13. Takeda A, Sakai K, Mitsui T, Nakamura H. Laparoscopic management of juvenile cystic adenomyoma of the uterus: report of two cases and review of the literature. *J Minim Invasive Gynecol.* 2007;14(3):370–4.
 14. Kumakiri J, Kikuchi I, Sogawa Y, Jinushi M, Aoki Y, Kitade M, et al. Single-incision laparoscopic surgery using an articulating monopolar for juvenile cystic adenomyoma. *Minim Invasive Ther Allied Technol.* 2013;22(5):312–5.
 15. Ación P, Mayol MJ, Ación M. The female gubernaculum: role in the embryology and development of the genital tract and in the possible genesis of malformations. *Eur J Obstet Gynecol Reprod Biol.* 2011;159(2):426–32.
 16. Rackow BW. Accessory cavitated uterine mass: a new müllerian anomaly? *Fertil Steril.* 2022;117(3):649–50.
 17. Kriplani A, Mahey R, Agarwal N, Bhatla N, Yadav R, Singh MK. Laparoscopic management of juvenile cystic adenomyoma: four cases. *J Minim Invasive Gynecol.* 2011;18(3):343–8.
 18. Chun SS, Hong DG, Seong WJ, Choi MH, Lee TH. Juvenile cystic adenomyoma in a 19-year-old woman: a case report with a proposal for new diagnostic criteria. *J Laparoendosc Adv Surg Tech A.* 2011;21(8):771–4.
 19. Jain N, Goel S. Cystic Adenomyoma simulates uterine malformation: A diagnostic dilemma: Case report of two unusual cases. *J Hum Reprod Sci.* 2012;5(3):285–8.
 20. Cucinella G, Billone V, Pitruzzella I, Monte AIL, Palumbo VD, Perino A. Adenomyotic cyst in a 25-year-old woman: case report. *J Minim Invasive Gynecol.* 2013;20(6):894–8.
 21. Branquinho MM, Marques AL, Leite HB, Silva IS. Juvenile cystic adenomyoma. *BMJ Case Rep.* 2012;2012. doi:bcr2012007006.
 22. Deblaere L, Froyman W, Bosch TVD, Rompuy AV, Kaijser J, Deprest J, et al. Juvenile cystic adenomyosis: A case report and review of the literature. *Australas J Ultrasound Med.* 2019;3(4):295–300.
 23. Dadhwal V, Sharma A, Khoiwal K. Juvenile Cystic Adenomyoma Mimicking a Uterine Anomaly: a Report of Two Cases. *Eurasian J Med.* 2017;49(1):59–61.
 24. Strelec M, Banović M, Banović V, Sirovec A. Juvenile cystic adenomyoma mimicking a Müllerian uterine anomaly successfully treated by laparoscopic excision. *Int J Gynecol Obstet.* 2019;146(2):265–6.
 25. Wang JH, Wu RJ, Xu KH, Lin J. Single large cystic adenomyoma of the uterus after conual pregnancy and curettage. *Fertil Steril.* 2007;88(4):965–7.
 26. Kim MJ. A case of cystic adenomyoma of the uterus after complete abortion without transcervical curettage. *Obstet Gynecol Sci.* 2014;57(2):176–9.
 27. Ho ML, Raptis C, Hulett R, Mcalister WH, Moran K, Bhalla S. Adenomyotic cyst of the uterus in an adolescent. *Pediatr Radiol.* 2008;38(11):1239–42.
 28. Liang YJ, Hao Q, Wu YZ, Wu B. Uterus-like mass in the left broad ligament misdiagnosed as a malformation of the uterus: a case report of a rare condition and review of the literature. *Fertil Steril.* 2010;93(4):1347.
 29. David C, Burette J, Duminil L, Bonneau S, Janvier A, Hoeffel C, et al. Uterus-like mass: A case report. *Eur J Obstet Gynecol Reprod Biol.* 2019;233:162–3.
 30. Na KY, Kim GY, Won KY, Kim HS, Kim SW, Lee CH. Extrapelvic Uterus-like Masses Presenting as Colonic Submucosal Tumor: A Case Study and Review of Literature. *Korean J Pathol.* 2013;47(2):177–81.
 31. Steinkampf MP, Manning MT, Dharia S, Burke KD. An accessory uterine cavity as a cause of pelvic pain. *Obstet Gynecol.* 2004;103(5 Pt 2):1058–61.
 32. Potter DA, Schenken RS. Noncommunicating accessory uterine cavity. *Fertil Steril.* 1998;70(6):1165–6.
 33. Fisseha S, Smith YR, Kumetz LM, Mueller GC, Hussain H, Quint EH. Cystic myometrial lesion in the uterus of an adolescent girl. *Fertil Steril.* 2006;86(3):716–8.
 34. Brosens I, Gordts S, Habiba M, Benagiano G. Uterine Cystic Adenomyosis: A Disease of Younger Women. *J Pediatr Adolesc Gynecol.* 2015;28(6):420–6.
 35. Dietrich JE, Millar DM, Quint EH. Obstructive Reproductive Tract Anomalies. *J Pediatr Adolesc Gynecol.* 2014;27(6):396–402.
 36. Peyron N, Jacquemier E, Devouassoux CM, Raudrant M, Golfier D, F. Accessory cavitated uterine mass: MRI features and surgical correlations of a rare but under-recognised entity. *Eur Radiol.* 2019;29(3):1144–52.
 37. Garofalo A, Alemanno MG, Sochirca O, Pilloni E, Garofalo G, Tin MCF, et al. Accessory and cavitated uterine mass in an adolescent with severe dysmenorrhoea: From the ultrasound diagnosis to surgical treatment. *J Obstet Gynaecol.* 2017;37(2):259–61.
 38. Shah N, Joshi A, Bansode S, Bansode V. Accessory Cavitated Uterine Mass: An Emerging Differential Diagnosis of Dysmenorrhea in Adolescents. *J Minim Invasive Gynecol.* 2021;28(6):1131–2.
 39. Batt RE, Yeh J. The cavitated accessory uterine mass: a Müllerian anomaly in women with an otherwise normal uterus. *Obstet Gynecol.* 2011;117(3):733–4.
 40. Malhotra K, Bajaj B. A case report on ACUM: a rare müllerian anomaly. *Int J Reprod Contracept Obstet Gynecol.* 2020;9(3):1310–4.
 41. Kapczuk K, Jaguszewska E, Kędzia W. 106 Accessory cavitated uterine mass (ACUM): A rare uterine obstructive anomaly diagnosed in menstruating girls and young women with severe dysmenorrhea (case series). *Eur J Obstet Gynecol Reprod Biol.* 2022;273:e45.
 42. Paul PG, Chopade G, Das T, Dhivya N, Patil S, Thomas M. Accessory Cavitated Uterine Mass: A Rare Cause of Severe Dysmenorrhea in Young Women. *J Minim Invasive Gynecol.* 2015;22(7):1300–3.
 43. Azuma Y, Taniguchi F, Wibisono H, Ikebuchi A, Moriyama M, Harada T. A Case Report of an Accessory and Cavitated Uterine Mass Treated with Total Laparoscopic Hysterectomy. *Yonago Acta Med.* 2021;64(2):207–9.
 44. Peters A, Rindos NB, Guido RS, Donnellan NM. Uterine-sparing Laparoscopic Resection of Accessory Cavitated Uterine Masses. *J Minim Invasive Gynecol.* 2018;25(1):24–5.
 45. Shah MV, Pisat S, Jain M, Chatterjee M, Nadkarni S, Bijlani S. Role of 3D Coronal Ultrasound in Diagnosis of Accessory and Cavitated Uterine Mass: A rare Müllerian Anomaly. *J Obstet Gynaecol India.* 2021;71(6):633–6.

46. Putta T, John R, Simon B, Sathyakumar K, Chandramohan A, Eapen A. Imaging Manifestations of Accessory Cavitated Uterine Mass-A Rare Mullerian Anomaly. *Indian J Radiol Imaging*. 2021;31(3):545–50.
47. Jain N, Verma R. Imaging diagnosis of accessory and cavitated uterine mass, a rare mullerian anomaly. *Indian J Radiol Imaging*. 2014;24(2):178–81.
48. Iranpour P, Haseli S, Keshavarz P, Dehghanian A, Khalili N. Pelvic Pain and Adnexal Mass: Be Aware of Accessory and Cavitated Uterine Mass. *Case Rep Med*. 2021;2021:6649663.
49. Ludwin A, Pityński K, Ludwin I, Banas T, Knafel A. Two- and three-dimensional ultrasonography and sonohysterography versus hysteroscopy with laparoscopy in the differential diagnosis of septate, bicornuate, and arcuate uteri. *J Minim Invasive Gynecol*. 2013;20(1):90–9.
50. Salim R, Jurkovic D. Assessing congenital uterine anomalies: the role of three-dimensional ultrasonography. *Best Pract Res Clin Obstet Gynaecol*. 2004;18(1):29–36.
51. Akar ME, Leezer KH, Yalcinkaya TM. Robot-assisted laparoscopic management of a case with juvenile cystic adenomyoma. *Fertil Steril*. 2010;94(3):55–6.
52. Jain N, Verma R. Imaging diagnosis of accessory and cavitated uterine mass, a rare mullerian anomaly. *Indian J Radiol Imaging*. 2014;24(2):178–81.
53. Naftalin J, Bean E, Saridogan E, Barton-Smith P, Arora R, Jurkovic D. Imaging in gynecological disease (21): clinical and ultrasound characteristics of accessory cavitated uterine malformations. *Ultrasound Obstet Gynecol Off J Int Soc Ultrasound Obstet Gynecol*. 2021;57(5):821–8.
54. Kiyak H, Seckin KD, Karakis L, Karacan T, Ozyurek ES, Asoglu MR. Decidualized juvenile cystic adenomyoma mimicking a cornual pregnancy. *Fertil Steril*. 2020;113(2):463–5.
55. Timor-Tritsch IE, Monteagudo A, Rebarber A, Goldstein SR, Tsymbal T. Transrectal scanning: an alternative when transvaginal scanning is not feasible. *Ultrasound Obstet Gynecol*. 2003;21(5):473–9.
56. Mollion M, Host A, Faller E, Garbin O, Ionescu R, Roy C. Report of two cases of Accessory Cavitated Uterine Mass (ACUM): Diagnostic challenge for MRI. *Radiol Case Rep*. 2021;16(11):3465–9.
57. Putta T, John R, Simon B, Sathyakumar K, Chandramohan A, Eapen A. Imaging Manifestations of Accessory Cavitated Uterine Mass-A Rare Mullerian Anomaly. *Indian J Radiol Imaging*. 2021;31(3):545–50.
58. Bedaiwy MA, Henry DN, Elguero S, Pickett S, Greenfield M. Accessory and cavitated uterine mass with functional endometrium in an adolescent: diagnosis and laparoscopic excision technique. *J Pediatr Adolesc Gynecol*. 2013;26(4):89–91.
59. Tokgoz VY, Tekin AB. A rare case of the new entity of müllerian anomalies mimicking the noncommunicating rudimentary cavity with hemi-uterus: accessory cavitated uterine mass. *Fertil Steril*. 2022;117(3):646–8.
60. Betzler N, Brunen M, Anfelter P, Wedlund L, Persson J, Epstein E. Sonographic features of accessory cavitated uterine mass (ACUM) successfully treated with robotic assisted laparoscopic surgery—a case report. *Clin Obstet Gynecol Reprod Med*. 2019;5(6). doi:10.15761/COGRM.1000268.
61. Pabuccu EG, Seval M, Sonmezer M, Atabekoglu C. Laparoscopic Management of Juvenile Cystic Adenomyoma. *J Minim Invasive Gynecol*. 2015;22(6S):S141.
62. Acien P, Acien M. The presentation and management of complex female genital malformations. *Hum Reprod Update*. 2016;22(1):48–69.
63. Park JC, Kim DJ. Successful laparoscopic surgery of accessory cavitated uterine mass in young women with severe dysmenorrhea. *Yeungnam Univ J Med*. 2021;38(3):235–9.
64. Panwar A, Davis AA, Lata K, Sharma S, Kriplani A. Laparoscopic Management of Accessory Cavitated Uterine Mass: A Report of Two Cases and Review of Literature. *J Gynecol Surg*. 2020;36(5):285–8.
65. Bedaiwy MA, Henry DN, Elguero S, Pickett S, Greenfield M. Accessory and cavitated uterine mass with functional endometrium in an adolescent: diagnosis and laparoscopic excision technique. *J Pediatr Adolesc Gynecol*. 2013;26(4):89–91.
66. Bazot M, Deux JF, Dahbi N, Chopier J. Myometrium diseases. *J Radiol*. 2001;82(12 Pt 2):1819–40.
67. Kafali H, Eser A, Duvan CI, Keskin E, Onaran YA. Recurrence of ovarian cyst after sclerotherapy. *Minerva Ginecol*. 2011;63(1):19–24.
68. Cohen A, Almog B, Tulandi T. Sclerotherapy in the management of ovarian endometrioma: systematic review and meta-analysis. *Fertil Steril*. 2017;108(1):117–24.
69. Albanese G, Kondo KL. Pharmacology of sclerotherapy. *Semin Interv Radiol*. 2010;27(4):391–9.
70. Merviel P, Lelievre C, Cambier T, Thomas-Kergastel I, Dupré PF. The first ethanol sclerotherapy of an accessory cavitated uterine mass. *Clin Case Rep*. 2021;9(1):19–22.

Author biography

Rana Mondal, - <https://orcid.org/0000-0001-9826-1775>

Priya Bhav, -

Cite this article: Mondal R, Bhav P. Accessory cavitated uterine malformation (ACUM): A hidden face of dysmenorrhea. *Indian J Obstet Gynecol Res* 2022;9(4):452-465.