

Content available at: <https://www.ipinnovative.com/open-access-journals>

Indian Journal of Obstetrics and Gynecology Research

Journal homepage: [www.ijogr.org](http://www.ijogr.org)

## Case Report

# A rare case of triplet heterotopic pregnancy - A case report

Akshitha Sai Ragam<sup>1,\*</sup>, Aashritha Thonangi<sup>1</sup>, Sheela S R<sup>1</sup>

<sup>1</sup>Dept. of Obstetrics and Gynaecology, Sri Devaraj Urs Medical College, Kolar, Karnataka, India



### ARTICLE INFO

#### Article history:

Received 17-08-2022

Accepted 22-08-2022

Available online 08-11-2022

#### Keywords:

Heterotopic pregnancy

Ovulation induction

### ABSTRACT

Triplet heterotopic pregnancy refers to the presence of specifically 3 concurrent gestations with at least 1 being abnormally implanted. Heterotopic pregnancy is rare and estimated to occur in about 1 per 30,000 spontaneous pregnancies while a higher prevalence may occur in assisted reproduction techniques that may reach up to 1 case per 100 in some literatures. The triplet heterotopic pregnancies are often in association with risk factors, as tubal factor infertility, pelvic infections, in vitro fertilization, more embryos transfer, and use of pharmacologic ovulation induction. A 22-year-old primigravida with history of undergoing ovulation induction treatment with 2 &  $\frac{1}{2}$  months of amenorrhea was brought to the Emergency Department with complaints of pain abdomen, vomiting and generalized weakness since one day. Transvaginal ultrasound revealed a single live intrauterine gestation at 9 weeks 3 days with fetal cardiac activity alongwith a well defined round to oval anechoic lesion likely gestation sac within the left fallopian tube with moderate to gross hemoperitoneum leading to the diagnosis of a heterotopic pregnancy with left ruptured ectopic pregnancy. She underwent an Exploratory Laparotomy under general anesthesia and was found to have a left sided ruptured tubal ectopic at the isthmo-ampullary junction measuring about 4 x 5 cms for which salpingectomy was done along with an incidental finding of a right sided unruptured ectopic pregnancy in the ampullary region which was in the process of tubal abortion for which right salpingotomy was done. Hemoperitoneum of 900 ml was present. Serial USG monitoring and regular antenatal check ups were done for intrauterine pregnancy and patient was followed up till term. She was admitted at 38 weeks gestation and delivered a healthy, term male baby of birth weight 2.86 kgs through caesarean section.

This is an Open Access (OA) journal, and articles are distributed under the terms of the [Creative Commons Attribution-NonCommercial-ShareAlike 4.0 License](https://creativecommons.org/licenses/by-nc-sa/4.0/), which allows others to remix, tweak, and build upon the work non-commercially, as long as appropriate credit is given and the new creations are licensed under the identical terms.

For reprints contact: [reprint@ipinnovative.com](mailto:reprint@ipinnovative.com)

## 1. Introduction

Heterotopic pregnancy is defined as the simultaneous presence of 2 or more pregnancies at different implantation sites, most commonly, one intrauterine and one ectopic. Triplet heterotopic pregnancy refers to the presence of specifically 3 concurrent gestations with atleast 1 being abnormally implanted.<sup>1</sup> It is rare in spontaneous conception, occurring in about 1:30,000, but the prevalence has been rising due to the increasing use of assisted reproduction techniques, reaching upto 1:100 in some

literatures.<sup>2</sup>

## 2. Case Report

A 22-year-old Primigravida with amenorrhoea of 2 &  $\frac{1}{2}$  months, who conceived after the second cycle of ovulation induction with Letrozole, was brought to the Emergency Department with complaints of pain abdomen, vomiting and generalized weakness of one day duration. On presentation, she was pale with vitals of: Pulse rate: 100 bpm, Blood Pressure: 90/60 mmHg, SpO<sub>2</sub>: 98% on room air, Respiratory rate: 18 cpm. Abdominal examination showed a distended abdomen with diffuse abdominal tenderness. Cervical motion tenderness was present on

\* Corresponding author.

E-mail address: [akshi.ragam@gmail.com](mailto:akshi.ragam@gmail.com) (A. S. Ragam).

bimanual examination with per speculum examination showing a posterior cervical os with no bleeding. Urine pregnancy test was positive with the transvaginal ultrasound revealing - a single live intrauterine gestational sac at 9 weeks 3 days with fetal cardiac activity along with a well defined, round to oval, anechoic lesion within the left fallopian tube likely to be a gestation sac, with moderate to gross haemoperitoneum leading to the diagnosis of a heterotopic pregnancy with left ruptured ectopic pregnancy.

She underwent an Exploratory Laparotomy under general anesthesia after taking a written and informed consent and was found to have a left sided ruptured tubal ectopic measuring 4 x 5 cms at the isthmo-ampullary junction for which left salpingectomy was done, with a bulky uterus and haemoperitoneum of around 900 ml. An incidental finding of a right sided unruptured ectopic pregnancy in the ampullary region was identified for which right salpingotomy was done. 2 pints of PRBCs were transfused intraoperatively.

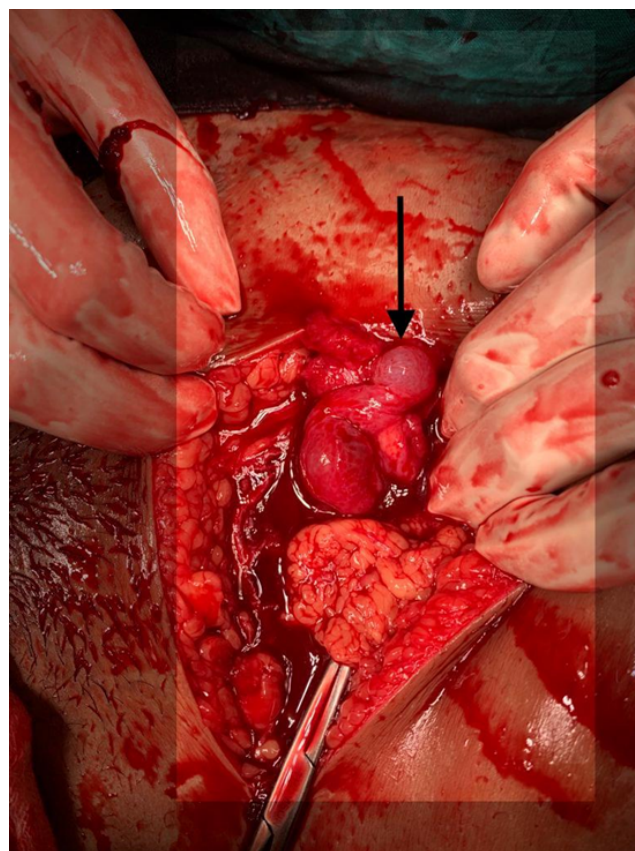
Histopathological examination was consistent with the intra-operative findings and showed features suggestive of products of conception from the right sac and left ruptured tubal ectopic pregnancy. Post-operative period was uneventful. She was discharged on post-operative day 8 with a viable intrauterine gestation at 10 weeks 4 days.

She was closely monitored through regular antenatal check ups and serial USG scans. She was started on micronized progesterone and weekly hydroxyprogesterone injections till 36 weeks gestation. She was admitted at 38 weeks gestation and delivered a healthy male baby of birth weight 2.86 kgs through caesarean section.

### 3. Discussion

Heterotopic pregnancy occurs in various forms such as bilateral or unilateral tubal, abdominal, cervical and ovarian pregnancy. Of which, the most common is tubal heterotopic pregnancy.<sup>3</sup> The use of ovulation-inducing agents has increased the incidence of multiple gestations and heterotopic pregnancies. The incidence is 1 in 900 with clomiphene citrate, whereas with gonadotropins it is around 1%.<sup>4</sup> Other risk factors implicated in the rising incidence are - pelvic infections, pre-existing tubal disease, previous ectopic pregnancy, tubal factor infertility and smoking. It has been observed that around 71% of heterotopic pregnancy cases had one risk factor, while 10% had three or more risk factors.<sup>5</sup> Hence, a thorough history and examination is essential to analyze all the risk factors related to heterotopic pregnancy.

Heterotopic pregnancies are rarely encountered in everyday obstetrics. Furthermore, the presence of a live intrauterine gestation is reassuring due to which the adnexa are often overlooked. Consequently, the patient presents in an emergency after tubal rupture, at which point, saving the life of the mother along with the intrauterine gestation

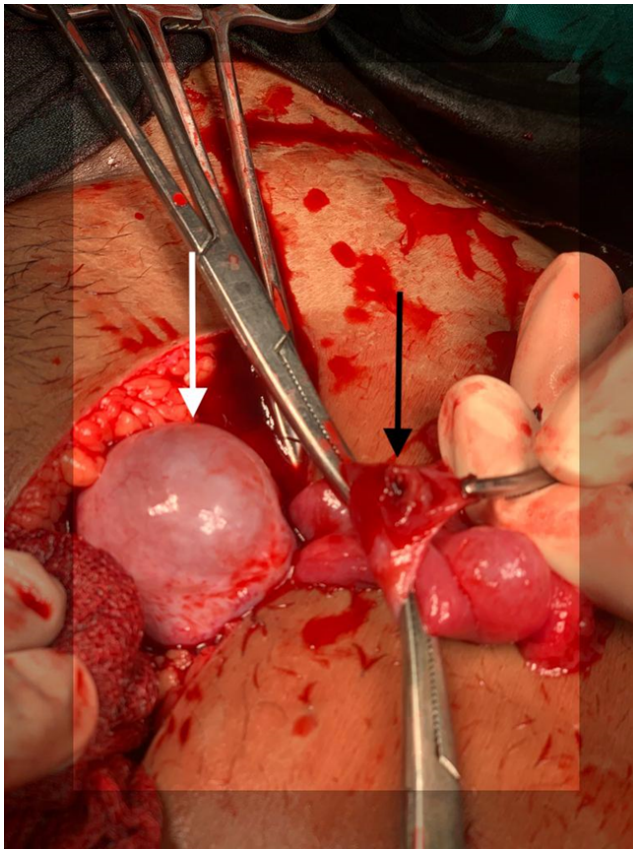


**Fig. 1:** Black arrow showing the right-sided unruptured tubal ectopic pregnancy

becomes a formidable task. In majority of the cases, the patient is referred to a higher centre with provisional diagnosis of appendicitis or ovarian torsion/ rupture or even ovarian hyperstimulation syndrome. In such cases, the clinician should have a high index of suspicion.<sup>6</sup> The main diagnostic aid is a transvaginal ultrasound (TVS), whose sensitivity and specificity for detecting a heterotopic pregnancy is around 92.4% and 100% respectively.<sup>7</sup>

They have a varied clinical presentation and can present with pain abdomen, bleeding per vagina, syncope among many others. Of all the presentations, 50% are asymptomatic while a majority of them - around 78.5%, are diagnosed after rupture, with acute abdomen symptoms. And in only 57% of cases, the diagnosis of triplet heterotopic pregnancy was pre-operatively made.<sup>8</sup>

Once the diagnosis is made, the main aim of the management is to halt the development of the ectopic pregnancy while simultaneously preserving the intrauterine pregnancy. The main modality of treatment is through surgery i.e, laparotomy or laparoscopy, the decision guided by the haemodynamic status of the patient. Laparoscopy is almost always preferred over laparotomy due to better visualization, lesser uterine manipulation and



**Fig. 2:** Black arrow showing the left-sided ruptured tubal ectopic pregnancy; white arrow showing the bulky uterus

faster recovery, with exception to cases complicated with clinical shock and intra-abdominal hemorrhage where open procedures are favoured.<sup>5</sup> Various conservative methods such as the USG - guided local infiltration of hyperosmolar glucose or potassium chloride have been reported but the success rate is controversial. A review of literature revealed that 55% of tubal heterotopic pregnancies treated conservatively required a subsequent salpingectomy.<sup>9</sup> The prognosis of the intrauterine gestation after treatment of the ectopic pregnancy is good with the rate of live births in heterotopic triplets being around 60%.<sup>8</sup>

#### 4. Conclusion

Heterotopic pregnancy is a potentially life-threatening condition that, although rare, has grave implications for both the mother and fetus. Furthermore, the diagnosis of heterotopic pregnancy remains one of the greatest challenges in obstetrical emergencies.<sup>7</sup> The importance of

the need for a systematic exploration of the pelvis with during the first ultrasound, irrespective of the presence or absence of any risk factors, should be emphasized. It is also essential to educate women for early antenatal consultation and to improve the access to antenatal clinics for the timely diagnosis and management of ectopic pregnancy while ensuring the viability of the intrauterine gestation.

#### 5. Source of Funding

None.

#### 6. Conflict of Interest

None.

#### References

1. Riestenberg CK, Nixon MD, Harris ID, Farah-Eways L. Heterotopic Triplet Pregnancy in Gonadotropin Stimulation Cycle: A Case Report. *J Reprod Med.* 2017;62(3-4):190–3.
2. Ali T, Tawab MA, Elhariri MA, Ayad AA. Heterotopic pregnancy: a case report. *Egypt J Radiol Nucl Med.* 2020;51(1):1–4.
3. Habana A, Dokras A, Giraldo JL, Jones EE. 2000.
4. Wallach EE, Tal J, Haddad S, Gordon N. Heterotopic pregnancy after ovulation induction and assisted reproductive technologies: a literature review from 1971 to 1993. *Fertil Steril.* 1996;66:1–12.
5. Talbot K, Simpson R, Price N, Jackson SR. Heterotopic pregnancy. *J Obstet Gynaecol.* 2011;31(1):7–12.
6. Agarwal P, Goyal KR, Agarwal A. A rare case of triplet heterotopic pregnancy with a live intrauterine and bilateral tubal ectopic. *Int J Reprod.* 2020;9(7):3087–90.
7. Li XH, Ouyang Y, Lu GX. Value of transvaginal sonography in diagnosing heterotopic pregnancy after in-vitro fertilization with embryo transfer. *Ultrasound in Obstetrics & Gynecology.* 2013;41(5):563–9.
8. Bugatto F, Quintero-Prado R, Kirk-Grohar J, Melero-Jiménez V, Hervías-Vivancos B, Bartha JL, et al. Heterotopic triplets: tubal ectopic and twin intrauterine pregnancy. A review of obstetric outcomes with a case report. *Arch Gynecol Obstet.* 2010;282(6):601–6.
9. Goldstein JS, Ratts VS, Philpott T, Dahan MH. Risk of surgery after use of potassium chloride for treatment of tubal heterotopic pregnancy. *Obstet Gynecol.* 2006;107(2):506–8.

#### Author biography

**Akshitha Sai Ragam**, Resident

**Aashritha Thonangi**, Assistant Professor

**Sheela S R**, Professor

**Cite this article:** Ragam AS, Thonangi A, Sheela S R. A rare case of triplet heterotopic pregnancy - A case report. *Indian J Obstet Gynecol Res* 2022;9(4):575-577.