

## Asherman's Syndrome: Commutable to pregnancy

Sravani Chithra Ch<sup>1,\*</sup>, Rahul Manchanda<sup>2</sup>, Nidhi Jain<sup>3</sup>, Anshika Lekhi<sup>4</sup>

<sup>1</sup>MD, <sup>2</sup>MD, FICOG, FICS, FICMCH, HOD, <sup>3</sup>MS, <sup>4</sup>DGO, Manchanda's Endoscopic Centre, PSRI Hospital

**\*Corresponding Author:**

Email: drsravanichithra@yahoo.com

### Abstract

Asherman's Syndrome is an acquired uterine condition, characterized by the formation of adhesions or scar tissue inside the uterus and/or the cervix. Patients usually present with infertility, recurrent pregnancy loss, menstrual irregularities and cyclic pelvic pain.

The cause of intrauterine adhesions is mostly iatrogenic (40%) as in dilatation and curettage (D&C) for a miscarriage, abortion, or retained products of conception. Other causes include pelvic infection and pelvic tuberculosis.

Here we present a 30yrs old woman with history of one D&C for incomplete abortion, who was anxious to conceive. On hysteroscopy she was diagnosed with moderate Asherman's syndrome. Hysteroscopic adhesiolysis was done and an intrauterine device was inserted. Second look hysteroscopy was done after one month which showed a well formed cavity. Now, 8 months after surgery she has conceived and successfully achieved 18 weeks gestation.

The authors present this case to show that hysteroscopy aids and provides a real-time view of the cavity, enabling accurate diagnosis, grading and concurrent treatment of intra uterine adhesions, hence improving the chances of pregnancy.

**Keywords:** Asherman's, iatrogenic, hysteroscopy, pregnancy.

Access this article online	
Quick Response Code:	Website:
	www.innovativepublication.com
	DOI:
	10.5958/2394-2754.2016.00022.9

### Introduction

Asherman's syndrome, named after Joseph Asherman, is a rare condition but one which is being increasingly recognized with the wider use of hysteroscopy for the assessment of subfertile women. It is an acquired uterine condition, characterized by the formation of adhesions or scar tissue inside the uterus and/or the cervix.

Asherman's syndrome (intrauterine adhesions) are most commonly caused by infections or iatrogenic uterine trauma. This condition is suspected in women with a history of ammenorrhoea or hypomenorrhoea not responsive to hormonal treatment, and infertility.

Hysterosalpingography can help in the diagnosis but hysteroscopy confirms the diagnosis, the type and extent of adhesions and also enables subsequent treatment by breaking the adhesions, with minimal trauma.<sup>[1]</sup>

Hysteroscopy has evolved from a diagnostic procedure into a therapeutic approach and plays an important role in the management of Asherman's syndrome.

### Case Report

A 30yrs old P0L0A1, anxious to conceive came with complaints of severe spasmodic dysmenorrhea. She had

history of an incomplete abortion in 2014 for which dilatation and curettage was done. She had regular 30 days cycles with bleeding for 3 days.

On examination abdomen was soft, no tenderness or mass felt. Investigations: Routine blood parameters were within normal limits. Thyroid and hormonal profile were normal.

Imaging by ultrasonography revealed a bulky uterus with multiple subserous fibroids with largest measuring 5×4 cm. Bilateral ovaries were normal. Endometrial thickness was 5mm.

Diagnostic and operative hysteroscopy with adhesiolysis with laparoscopic myomectomy with chromopertubation was done.

On hysteroscopy the cervical canal was normal. Uterine cavity was reduced in size. Dense fibromuscular adhesions were seen obliterating more than one third of cavity (Fig. 1). Right ostium was occluded with adhesions (Fig. 2), left ostium was visualized and normal. Adhesiolysis was done with scissors and an intrauterine device without copper was placed.

Laparoscopic myomectomy was also done in the same sitting and four subserous fibroids with the largest measuring 5×5 cm were removed. Chromopertubation test showed bilateral free spill.

Her post-operative period was uneventful. She got her period four weeks after the surgery after which relook hysteroscopy was done which showed a well formed uterine cavity (Fig. 3).

Now, 8 months after surgery she has conceived and successfully achieved 18 weeks gestation (Fig. 4& 5).

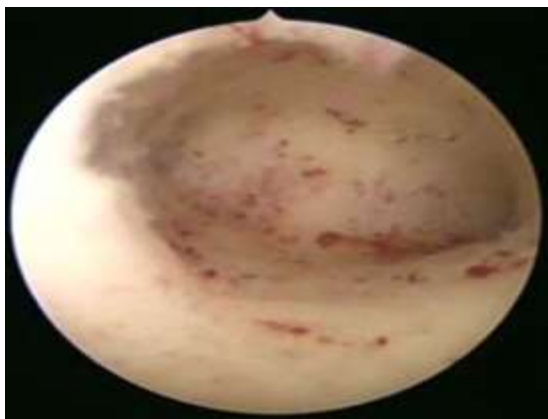

Fig. 1:

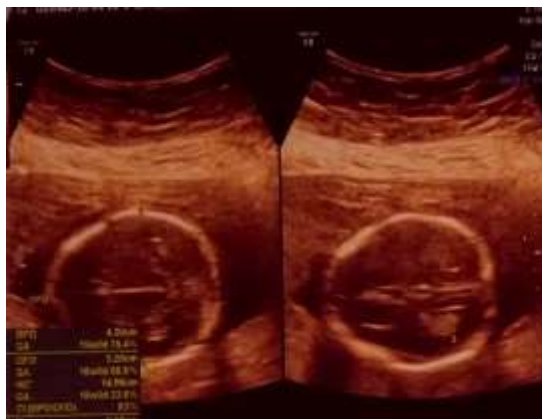

Fig. 4:

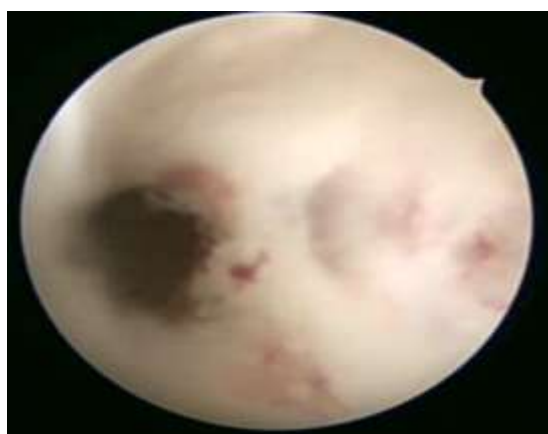

Fig. 2: Right ostium occluded by adhesions

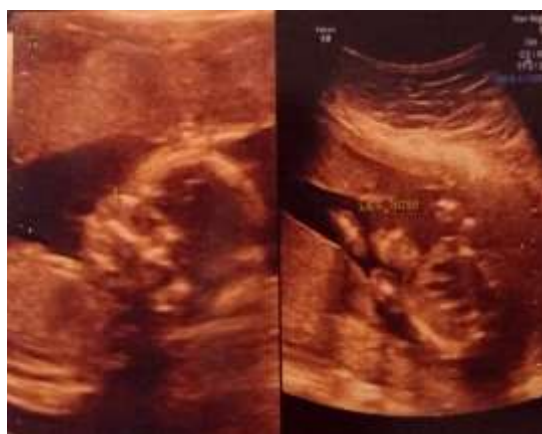

Fig. 5:

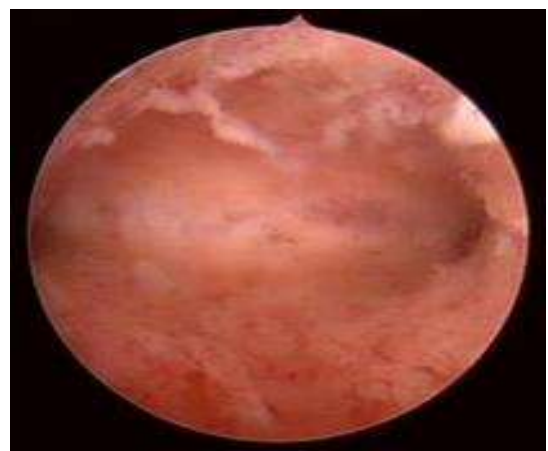


Fig. 3:

### Discussion

Earliest reports of Asherman's syndrome were made by Fritsch in 1894, Bass in 1927 and Stamer in 1946.

The risk factors for developing intrauterine adhesions are either iatrogenic factors like dilatation and curettage (40%), caesarean sections and myomectomies or pelvic infections and tuberculosis.

The risk increases with the number of D&C's performed. After a single D&C the risk is 16%, while the risk increases to 32% after 3 or more D&C's.

In 1948 Asherman listed the etiology of the condition as curettage after delivery, miscarriage, or a molar pregnancy, or after manual removal of the placenta or uterine packing. He also extended the condition to include partial or complete obliteration of the uterine cavity secondary to trauma to the uterine body.<sup>[2]</sup>

The condition is now becoming increasingly recognized as a cause of infertility, menstrual disturbance, pelvic pain and pregnancy complications.

Patients usually present with secondary amenorrhea, hypomenorrhea, infertility, recurrent abortions or dysmenorrhea.

The diagnosis of Asherman's syndrome cannot be made by physical examination, as it fails to reveal any abnormalities.<sup>[3]</sup>

Transcervical sounding may not reveal the endometrial adhesions but may show the cervical obstruction.<sup>[4]</sup>

Hysterosalpingography (HSG) using contrast dye, sonohysterography, also called saline infusion sonography<sup>[5]</sup> and three dimensional ultrasonography may be helpful in the evaluation of IUA's <sup>[6]</sup> but are not confirmatory.

Compared to the radiological investigations, hysteroscopy reveals the extent, morphological characteristics of adhesions, and the quality of the endometrium more accurately.

The extent and severity of adhesions can be noted using various classifications. The grading systems include:

- i. Marsh et al grading system (1978)
- ii. American Fertility Society classification(1988)
- iii. Valle and Sciarra's classification (1988)
- iv. Donnez and Nisolle classification (1994)

According to AFS classification our patient having uterine cavity 1/3 to 2/3 obliterated, dense fibrous adhesions and normal menstrual cycle falls under moderate Asherman's syndrome with a score of 6.

**Table 1: Marsh et al Grading System**

Classification	Condition
Mild	Flimsy adhesions occupying less than 1/4 <sup>th</sup> of uterine cavity. Ostial areas and fundal region minimally involved or clear.
Moderate	1/4 <sup>th</sup> to 3/4 <sup>th</sup> of cavity involved. Ostial areas and upper fundus involved. No agglutination of uterine walls.
Severe	>3/4 <sup>th</sup> cavity involved. Occlusion of both ostia and upper fundus. Agglutination of uterine walls.

**Table 2: American Fertility Society classification**

Extent of cavity involved	< one third 1	One third to two third 2	>Two thirds 4
Type of adhesions	Flimsy 1	Flimsy and dense 2	Dense 4
Menstrual pattern	Normal 0	Hypomenorrhea 2	Amenorrhea 4
Prognostic classification			
Stage I (mild)	1-4		
Stage II (moderate)	5-8		
Stage III (severe)	9-12		

**Table 3: Valle and Sciarra's classification**

Mild	Filmy adhesions composed of basal endometrium producing partial or complete uterine cavity occlusion.
Moderate	Fibromuscular adhesions that are characteristically thick, still covered by endometrium that may bleed on division, partially or totally occluding the uterine cavity.
Severe	Composed of connective tissue with no endometrial lining and likely to bleed upon division, partially or totally occluding the uterine cavity.

**Table 4: Donnez and Nisolle classification**

I - Central adhesions	a) Thin filmy adhesions (endometrial adhesions) b) Myofibrous (connective adhesions)
II - Marginal adhesions (always myofibrous or connective)	a) Wedge like projection b) Obliteration of one horn
III - Uterine cavity absent on HSG	a) Occlusion of the internal os (upper cavity normal) b) Extensive agglutination of uterine walls (absence of uterine cavity - true Asherman's)

The three main objectives of treating Asherman's syndrome are to restore the size and shape of the uterine cavity, to restore normal endometrial function and to restore fertility or treat other symptoms.

Surgery is the criterion standard in the management of Asherman's syndrome, and there is no role for medical treatment.

Mild adhesions may be lysed while distending the cavity or by blunt dissection. The more lateral the adhesions are, and greater their density, the more

difficult becomes the dissection and the greater the risk of complications such as perforation.

Different Hysteroscopic techniques have been described for adhesiolysis. We have used the hysteroscopic scissors (valle & sciarra) for adhesiolysis.<sup>[7]</sup> Resectoscope with monopolar or bipolar probe can also be used.

Nd-YAG laser, monopolar and bipolar electrosurgical instruments are used for adhesiolysis under direct vision. They help in accurate cutting and hemostasis simultaneously.

But they have their own disadvantages like visceral damage if perforation of uterus occurs, extensive endometrial damage causing recurrence of IUA's and cervical dilatation is needed.

We have used scissors in our patient, which is a mechanical method with an advantage of precise cutting and less damage to the endometrium and cervical dilatation is not required.

The most common problem with Asherman's syndrome is that it frequently recurs. Techniques used to prevent recurrence include the use of estrogen post-procedure, repeat office hysteroscopy to break up scar tissue as it forms, and placement of an intrauterine device or a foley's catheter.

We place an IUD post adhesiolysis and give our patients conjugated estrogen of 1.25mg on QID basis for 21 days followed by medroxy progesterone acetate 10 mg BD for 7 days to improve endometrial regeneration and prevention of recurrence.

Insertion of an intrauterine device (IUD) provides a physical barrier between the uterine walls, separating the endometrial layers after lysis of IUAs. Pabuccu R et al in their study examined the use of the IUD after hysteroscopic adhesiolysis by comparing two groups, and showed that there was no difference in pregnancy rates or live births.<sup>[8]</sup>

The recurrence rate is high in this syndrome with rate of 2 of 3 patients with severe adhesions. Consequently, regardless of the surgical intervention used, reassessment of the uterine cavity is necessary. We reassess our patients after four weeks.

**Conclusion**

Intrauterine adhesions should be classified accurately because it is a prognostic factor for fertility outcome. The first objective of treatment is to restore the uterine cavity to normal. Secondary objectives include treating associated symptoms and preventing recurrence of adhesions. Hysteroscopy plays a vital role in accurately assessing and classifying Asherman's syndrome and also in concurrent treatment thereby enhancing the chances of pregnancy.

**References**

1. Roma DA, Ubada B, Ubada A, et al. Diagnostic value of hysterosalpingography in the detection of intrauterine

abnormalities: a comparison with hysteroscopy. *AJR Am J Roentgenol.* 2004;183:1405–1409.

2. Asherman JG 1948 Amenorrhoea Traumatica (Atretica). *Journal of Obstetrics and Gynaecology of the British Empire*55, 23–30.

3. Jones WE. Traumatic intrauterine adhesions. *Am J Obstet Gynecol.* 1964;89:304–313.

4. Netter AP, Musset R, Lambert A, Salomon Y. Traumatic uterine synechiae: a common cause of menstrual insufficiency, sterility, and abortion. *Am J Obstet Gynecol.* 1956;71:368–375.

5. Soares SR, Barbosa dos Reis MMB, Carnargos AF. Diagnostic accuracy of sonohysterography, transvaginal sonography, and hysterosalpingography in patients with uterine cavity diseases. *FertilSteril.* 2000;73:406–410.

6. Sylvestre C, Child T, Tulandi T, Tan S. A prospective study to evaluate the efficacy of two and three dimensional sonohysterography in women with intrauterine adhesions. *Fertil Steril.* 2003;79:1222–1225.

7. Valle RF, Sciarra JJ 1988 Intrauterine adhesions: hysteroscopic diagnosis, classification, treatment, and reproductive outcome. *American Journal of Obstetrics and Gynecology*158,1459–1470.

8. Pabuccu R, Onalan G, Kaya C, et al. Efficiency and pregnancy outcome of serial intrauterine device guided hysteroscopic adhesiolysis of intrauterine synechiae. *FertilSteril.* 2008;90:1973–1977.