

Ruptured Ectopic Pregnancy after Tubal ligation: A case report

Kamala Verma¹, Girish Chandra Baniya^{2*}

¹Assistant Professor, Dept. of Obstetrics & Gynecology, ²Medical Officer, Dept. of Psychiatry, S.P. Medical College & Associate Group of P.B.M. Hospital, Bikaner Rajasthan

***Corresponding Author:**

Email: girishdrbaniya@gmail.com

Abstract

Diagnosis of ectopic pregnancy in a sterilized female may be missed many times and it is associated with greater risk of maternal morbidity and mortality. Risk of ectopic pregnancy after failure of tubal ligation is not only limited to initial years but also seen many years after the procedure. So due consideration should be given to ectopic gestation as a part of the differential diagnosis in acute abdomen of reproductive age group female even in the presence of tubal ligation history.

Keywords: Tubal ligation; Ectopic pregnancy; Sterilization failure.

Access this article online	
Quick Response Code:	Website: www.innovativepublication.com
	DOI: 10.5958/2394-2754.2016.00039.4

Introduction

Fallopian tube ligation is a common and widely accepted permanent method of female contraception. It is highly effective in pregnancy prevention. Failure rate of tubal sterilization is very low. But in case if pregnancy occur following sterilization, chances of ectopic is high.

Ectopic pregnancy is an important cause of morbidity and mortality in reproductive age group of females. It is a significant cause of first trimester maternal mortality⁽¹⁾. So its early diagnosis and treatment is essential in preventing complication.

Therefore, possibility of ectopic gestation should be kept in mind for differential diagnosis of acute pain abdomen in any women of reproductive age even she had history of tubal ligation.

Here we report a case of ruptured ectopic pregnancy in a patient who had undergone bilateral tubal ligation 10 years ago as a method of contraception.

Case Report

A 37 years old patient G3 P2 L2 A0 presented to our emergency department with history of two-month amenorrhea and lower pain abdomen for two days. She also complained of per vaginal spotting since 5 days. She had history of interval laparoscopic bilateral tubal ligation 10 year ago. On examination patient was in shock. She was pale, her pulse was 120 per minute and BP was 80/60 mmHg, lower abdominal tenderness was present. On per speculum examination slight bleeding was present. On per vaginal examination cervix was soft, os closed, cervical motion tenderness was present and

uterus size could not be assessed. Her urine pregnancy test was positive. USG pelvis showed empty uterus and a mixed echogenic mass of 55×49mm in size in left adnexa with free fluid in cul-de-sac.

A diagnosis of ruptured ectopic pregnancy was made. Emergency exploratory laparotomy was performed under general anesthesia and two units of whole blood transfused. During laparotomy approximately 2 liters of hemoperitoneum was present. Uterus was normal in size. Left tubal rupture in ampullary region was present. Ruptured gestation sac with embryo was present in peritoneal cavity. Silicon rings was present in isthmic region of both tubes. Left sided salpingectomy done. Right tube religated. Both ovaries were normal. Peritoneal cavity irrigated with normal saline. Tissue saved and sent for histopathological examination and report showed specimen of tubal pregnancy containing chronic villi. Post-operative period was uneventful and she was discharged on 8th day.

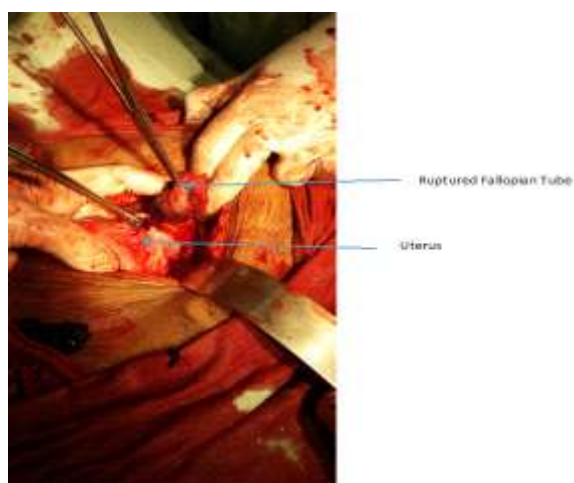


Fig. 1: Intraoperative picture showing uterus with left tubal ruptured ectopic pregnancy in ampullary region

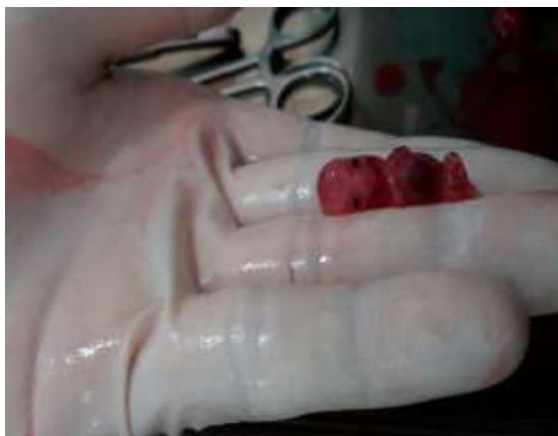

Fig. 2: Embryo extracted from peritoneal cavity

Discussion

Although pregnancy after tubal sterilization is uncommon but if occurs then it may be ectopic. Various studies suggest that incidence of ligation failure is 0.13–1.3% of which 15–33 % will be ectopic⁽²⁾. Risk of failure is not limited to initial years of sterilization. In a large multicenter study, the annual risk of ectopic pregnancy for all methods combined in the 4th through 10th year after ligation was no lower than in the first 3 years⁽³⁾. The risk of ectopic pregnancy depends on method of tubal occlusion, operative technique, age of patient and condition of tube. Risk of ectopic pregnancy is high after electrocoagulation⁽⁴⁾. The incidence of ectopic pregnancy after sterilization is high when it is performed during postpartum period because the edematous and congested tube increase the risk of incomplete occlusion of lumen of tube. Also risk of failure is high in young female because of their greater fecundability. Ectopic pregnancy may be due to formation of tubo-peritoneal fistula after ligation through which sperm may pass but the fertilized ovum cannot pass and implantation occurs in distal segment of the tube⁽⁵⁾.

Diagnosis of ectopic pregnancy in post sterilized women needs a high degree of suspicion. Clinical sign and symptoms should be carefully evaluated. Urine pregnancy test, serum β -HCG titer and ultrasonography are helpful in making diagnosis.

In this case report patient was young and had bilateral laparoscopic tubal ligation 10 year ago. It indicates that failure is not limited to initial few years of sterilization, it may occur even long after the procedure. During laparotomy ruptured gestational sac with an embryo was found in peritoneal cavity. This is rarely seen in ruptured ectopic cases.

Conclusion

It is concluded that ectopic pregnancy is a surgical emergency that can cause significant risk for the patient's life, therefore more attention must be given to rule out pregnancy including ectopic pregnancy while evaluating the post sterilized women with missed period, pain abdomen or irregular bleeding. All patients

undergoing tubal ligation should be informed that pregnancy either intrauterine or ectopic may occur long after the sterilization.

References

1. Ameh N, Madugu NH, Bawa US, Adelaiye MS, Akpa M. Tubal ectopic pregnancy after bilateral tubal ligation: A case report. *Nigerian journal of medicine : journal of the National Association of Resident Doctors of Nigeria*. 2006;15:453-4.
2. Obajimi GO, Balogun FO, Nwose U, Obajimi OM. Right ampullary ectopic pregnancy following bilateral tubal ligation using spring clips. *Annals of Ibadan postgraduate medicine*. 2013;11:34-6.
3. Peterson HB, Xia Z, Hughes JM, Wilcox LS, Tylor LR, Trussell J. The risk of ectopic pregnancy after tubal sterilization. *U.S. Collaborative Review of Sterilization Working Group*. *The New England journal of medicine*. 1997;336:762-7.
4. Hulka JF, Omran K, Lieberman BA, Gordon AG. Laparoscopic sterilization with the spring clip: instrumentation development and current clinical experience. *American journal of obstetrics and gynecology*. 1979;135:1016-20.
5. Kirubamani NH. Does Tubal Sterilization offer a Permanent Solution? *Indian Journal of Science and Technology*. 2014;7:418.