

Content available at: <https://www.ipinnovative.com/open-access-journals>

Indian Journal of Obstetrics and Gynecology Research

Journal homepage: www.ijogr.org

Case Report

A rare case of ovarian torsion in premenarcheal age- Case report and review of literature

Fozia Jeelani Wani^{1*}, Yoga Nagendhar¹, Rani Reddy¹

¹Dept. of Obstetrics and Gynecology, Apollo Institute of Medical Sciences and Research, Hyderabad, Telangana, India



ARTICLE INFO

Article history:

Received 25-07-2023

Accepted 05-09-2023

Available online 22-11-2023

Keywords:

Ovarian torsion

Laparoscopy

Oophoropexy

Recurrence

ABSTRACT

Ovarian torsion in childhood and adolescence is rare gynecological emergency. We report a case of ovarian torsion in eleven-year-old pre-menarcheal girl who presented with acute lower left abdominal pain and vomiting. On examination her vital signs were stable, secondary sexual characters were absent, abdomen was scaphoid with tenderness in left iliac fossa. Ultrasonography with doppler study showed a heterogenous mass measuring about 58x31mm in left adnexal region close to uterus with minimal vascularity. MRI findings were consistent with ovarian torsion. Patient underwent emergency laparoscopy and left ovary was found to be enlarged, blue-black with hemorrhagic cyst with two twists along Infundibulo-pelvic ligament. Ovarian Sparing Surgery involving de-torsion of torsed ovary with drainage of hemorrhagic cyst was performed. Right ovary was found to be normal in size with multicystic appearance. Bilateral oophoropexy using sandwich technique was done in order to prevent future recurrences.

This case report emphasizes on importance of immediate diagnosis with ultrasound and MRI. Surgical management in form of laparoscopy with ovarian sparing surgery in young patients is important to preserve their fertility.

This is an Open Access (OA) journal, and articles are distributed under the terms of the [Creative Commons Attribution-NonCommercial-ShareAlike 4.0 License](https://creativecommons.org/licenses/by-nc-sa/4.0/), which allows others to remix, tweak, and build upon the work non-commercially, as long as appropriate credit is given and the new creations are licensed under the identical terms.

For reprints contact: reprint@ipinnovative.com

1. Introduction

Ovarian torsion (OT) is a rare condition that has been reported in the fetuses, neonates, infants and through adolescence. Incidence of OT in paediatric population is approximately 4.9 per 100,000 girls per year.¹ Paediatric OT has been found to occur more in normal adnexa than in abnormal adnexa.² This may be due to lax and long infundibulo-pelvic ligament owing to the incomplete descent of the ovaries from the abdomen into the pelvis. OT can be associated with functional ovarian cyst or benign neoplasm³ and rarely with malignancy (1.8%).⁴ OT is more common on right side due to relative mobility of caecum. Usual presentation of OT is pain abdomen which may mimic other pathologies related to the gastrointestinal and

urinary tracts. We report a rare case of ovarian torsion in a young pre-menarcheal girl managed with laparoscopic detorsion, aspiration of haemorrhagic cyst and bilateral oophoropexy.

2. Case Report

A previously healthy eleven-year-old girl presented with a two days history of intermittent left lower abdomen pain and dysuria followed by non-projectile vomiting for one day. A day before she was examined by pediatrician and was diagnosed with acute gastroenteritis and managed conservatively. However, her symptoms worsened and she was brought to our hospital with severe abdominal pain. She had similar complaint 6 months ago which was managed conservatively. She was born as full-term, had history of febrile seizures at 2 years of age and was last

* Corresponding author.

E-mail address: drfozia80@gmail.com (F. J. Wani).

vaccinated at 5 years of age. Her axillary temperature was 98.4°F, pulse rate of 100 per minute, blood pressure of 110/70 mmHg, respiratory rate of 18 breaths per min, and oxygen saturation was 100% on room air. Her secondary sexual characters were absent. Her height was 128 cm and weight of 25 kgs which was less than 3rd percentile for her age. Her abdomen was scaphoid with normal bowel sounds. Tenderness was present in lower abdomen which was more severe in left iliac fossa. Involuntary guarding and rigidity were present however there was no rebound tenderness. There was no hepatosplenomegaly, or costovertebral angle tenderness. Rest of the systemic examination was normal. Her complete urine examination was within normal limits. The patient's white blood count was elevated while hemoglobin, hematocrit and platelets were within normal levels. The pain and vomiting were relieved temporarily with intravenous analgesics and antiemetics. Ultrasonography with doppler study revealed heterogenous mass measuring about 58 x 31mm in left adnexal region close to uterus, bulky left ovary with peripherally arranged follicles and heterogenous stroma, minimal vascularity in adnexal mass with possibility of left sided adnexal torsion. Right ovary was normal with minimal free fluid in the pelvis. MRI pelvis showed normal sized uterus deviated to the left, normal right ovary, enlarged left ovary, 32 cc, heterogeneously hypointense with peripheral arranged follicles and thickened left adnexal structures with twisting of vascular pedicle suggestive of adnexal torsion.

Patient was taken up for emergency laparoscopy which revealed enlarged left ovary with a hemorrhagic cyst, bluish-black in colour with two twists in pedicle, diagnosed as ovarian torsion (Figure 1). Right ovary was normal with few superficial small cysts and uterus was normal for age. Detorsion, aspiration of hemorrhagic cyst with bilateral oophoropexy was done. Oophoropexy was done by approximating the round ligament to the ovarian ligament beneath the fallopian tube using Sandwich technique (Figures 2 and 3). The patient was discharged on postoperative day 3 in stable condition. Follow-up ultrasound performed after one month showed reduced size of left ovary (38 x 30mm) and normal right ovary. At six months follow-up USG showed normal left ovary (17x7x6 mm) with few follicles and normal right ovary.

3. Discussion

More than 50% of pediatric OT occurs between 9 and 12 years of age.⁵ Two peaks in the age distribution of pediatric OT have been reported, first peak is seen in infants and second at the age of 12 years.^{5,6} Torsion initially compromises venous and lymphatic channels leading to oedema and enlargement of ovary, later arterial compromise leads to thrombosis and ischemia. If left untreated the torsed ovary may rarely atrophy. The presenting symptom in OT is groin or flank pain with abdominal tenderness (88%),

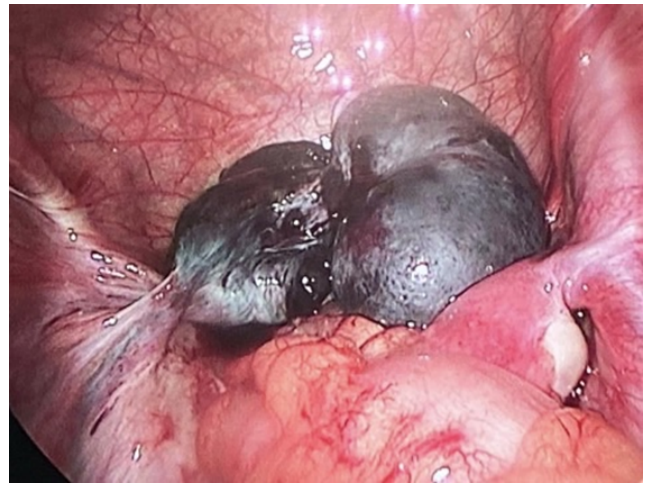


Figure 1: Laparoscopic view of torsion of left ovary with hemorrhagic ovarian cyst

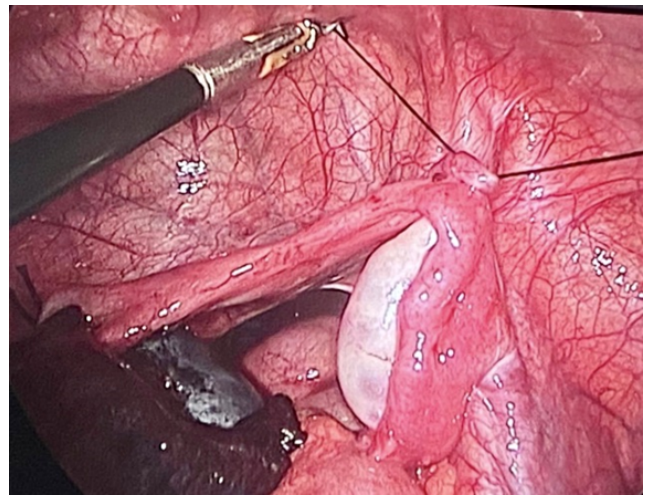


Figure 2: Laparoscopic view of Oophoropexy of contralateral ovary

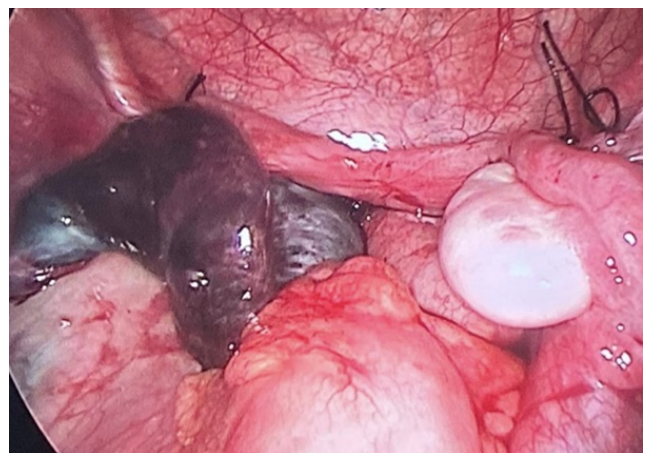

Figure 3: Laparoscopic view showing bilateral Oophoropexy

nausea (62%) and vomiting (67%).⁷ Rebound tenderness and peritoneal signs are present in 12-27% of cases.⁷ Some patients present with repeated attacks of acute onset pain interspersed with asymptomatic intervals representing repeated episodes of torsion and detorsion. Our case presented with severe pain abdomen and vomiting which was initially thought to be related to gastrointestinal tract but as the pain persisted, USG and MRI were performed, lead to diagnosis of ovarian torsion. Ultrasound is the imaging modality of choice in diagnosing OT in pediatric patients due to its high sensitivity (92%) and specificity (96%).⁸ The diagnostic features are the presence of a unilateral enlarged ovary, peripheral displaced follicles with stromal oedema, complex adnexal mass and fallopian tube thickening. Doppler flow study shows loss of blood flow and whirl pool sign in the vessels with torsion. However, Doppler study has been found to be normal in 60% of cases with OT confirmed surgically.⁹ This can be due to intermittent torsion or collateral blood supply from the utero-ovarian vessels or infundibulo-pelvic vessels making Doppler flow study an unreliable tool for diagnosis. Both CT and MRI are important for diagnosis of OT and to rule out other differential diagnosis but it may not be feasible in a resource-poor setup.¹⁰ In case of suspected OT diagnostic laparoscopy should be considered and not deferred with fear of negative laparoscopy. However, to reduce unnecessary surgical intervention various authors have developed few indices to predict ovarian torsion. One of the indices include combined clinical and radiological indicators like presence of vomiting, adnexal volume and the adnexal-volume ratio (volume of affected ovary/volume of unaffected ovary).¹¹ Cyrille Huchon et al. published a scoring system which included five criteria's that were independently associated with adnexal torsion.¹² These were unilateral abdominal or lumbar pain, pain duration less than 8 hours, vomiting, absence of leucorrhoea or metrorrhagia and ovarian cyst more than 5 cm by ultrasound.

In our case emergency laparoscopy with de-torsion of ovary, aspiration of cyst and bilateral oophoropexy by sandwich technique was performed which is described as treatment of choice in various other studies.¹³ Various techniques of oophoropexy involve fixation of ovary to posterior abdominal wall or pelvic wall, plication of utero-ovarian ligaments and sandwich technique.¹⁴ Sandwich technique involves approximation of the ovarian ligament and the round ligament with 2 to 3 interrupted sutures passed through the avascular space under the tube without affecting tubal motility or its relation to ovary. Trend of conservative surgeries to preserve ovaries regardless of the colour of ovaries and duration of torsion has been rising in recent years. Chance of conservative surgery with preservation of ovaries decreases with increase in time since onset of symptoms. Ovarian ischemia is classified according to Parelkar et al into four grades.¹⁵ Grade 1 is normal-sized, slightly discoloured ovary which revert

to normal colour after detorsion. Grade 2 is dark red to brown, mildly enlarged ovary which become hyperemic with multiple pinpoint petechiae after detorsion. Grade 3 is brown to black, grossly enlarged ovary with hematoma, with slight improvement in colour after detorsion and hematoma evacuation. Grade 4 is completely black, grossly enlarged ovary with hematoma in which no improvement occurs in colour after detorsion and hematoma evacuation.

Harkins G. in 2007 reported improvement in colour of ovaries after detorsion which was not evident during surgery but confirmed at second-look laparoscopy after 36 hours.¹⁶ Oelsner and colleagues reported that even in presence of necrotic appearance of ovaries with torsion ovarian function is preserved in 88-100% cases.¹⁷

The ovarian torsion may recur rarely (12% cases), more in cases without ovarian mass (86%) cases than with ovarian mass (13%).¹⁸ Ovarian sparing surgery as well may be complicated with recurrent torsion or reduced ovarian function. Geimanaite L et al. reported 51 cases of ovarian torsion with ovarian sparing surgeries done in 31 cases. Follow up of 20 cases with ovarian sparing surgeries showed multi follicular ovaries in 17 cases, normal size pauci-follicular ovary in one case, micro follicles in another one and one case had no ovarian material detectable by ultrasound.¹⁹ Recurrence rate after oophoropexy is uncommon. Berzotti et al. reported recurrence rate of 5.2% after oophoropexy.¹⁸ Thus bilateral oophoropexy was justified in our case to prevent recurrence and ovarian torsion in contralateral ovary.

4. Conclusion

The present case highlights the importance of prompt diagnosis, high suspicion index and management of ovarian torsion in pediatric patients. The use of ultrasound as a first-line imaging modality especially in resource poor setting is a boon. Conservative surgical intervention with ovarian sparing surgery and oophoropexy is the most effective treatment to achieve the best outcomes and prevent recurrences.

5. Source of Funding

None.

6. Conflict of Interest

None.

References

1. Schuh AM, Klein EJ, Allred RJ, Christensen A, Brown JC. Pediatric adnexal torsion: not just a Postmenarchal problem. *J Emerg Med.* 2017;52(2):169–75.
2. Pansky M, Smorgick N, Herman A, Schneider D, Halperin R. Torsion of normal adnexa in postmenarchal women and risk of recurrence. *Obstet Gynecol.* 2007;109(2 Pt 1):355–9.

3. Spinelli C, Buti I, Pucci V, Liserre J, Alberti E, Nencini L, et al. Adnexal torsion in children and adolescents: new trends to conservative surgical approach -our experience and review of literature. *Gynecol Endocrinol.* 2013;29(1):54–8.
4. Oltmann SC, Fischer A, Barber R, Huang R, Hicks B, Garcia N. Pediatric ovarian malignancy presenting as ovarian torsion: incidence and relevance. *J Pediatr Surg.* 2010;45(1):135–9.
5. Oltmann SC, Fischer A, Barber R, Huang R, Hicks B, Garcia N. Cannot exclude torsion: a 15-year review. *J Pediatr Surg.* 2009;44(6):1212–6.
6. Kokoska ER, Keller MS, Weber TR. Acute ovarian torsion in children. *Am J Surg.* 2000;180:462–5.
7. Gasser CRB, Gehri M, Joseph JM, Pauchard JY. Is It Ovarian Torsion? A Systematic Literature Review and Evaluation of Prediction Signs. *Pediatr Emerg Care.* 2016;32(4):256–61.
8. Bronstein ME, Pandya S, Snyder CW, Shi Q, Muensterer OJ. A meta-analysis of B-mode ultrasound, Doppler ultrasound, and computed tomography to diagnose pediatric ovarian torsion. *Eur J Pediatr Surg.* 2015;25(1):82–6.
9. Sasaki KJ, Miller CE. Adnexal torsion: review of the literature. *J Minim Invasive Gynecol.* 2014;21(2):196–202.
10. Lorenc AP, Swenson D, Tubbs RJ, Lazarus E. Ovarian and tubal torsion: imaging findings on US, CT, and MRI. *Emerg Radiol.* 2014;21(2):179–87.
11. Schwartz BI, Huppert JS, Chen C, Huang B, Reed JL. Creation of a Composite Score to Predict Adnexal Torsion in Children and Adolescents. *J Pediatr Adolesc Gynecol.* 2018;31(2):132–7.
12. Huchon C, Staraci S, Fauconnier A. Adnexal torsion: a predictive score for pre-operative diagnosis. *Hum Reprod.* 2010;25(9):2276–80.
13. Cass DL. Ovarian torsion. *Semin Pediatr Surg.* 2005;14:86.
14. Hosny TA. Oophoropexy for ovarian torsion: a new easier technique. *Gynecol Surg.* 2017;14(1):7.
15. Parelkar SV, Mundada D, Sanghvi BV, Joshi PB, Oak SN, Kapadnis SP, et al. Should the ovary always be conserved in torsion? A tertiary care institute experience. *J Pediatr Surg.* 2014;49(3):465–8.
16. Harkins G. Ovarian torsion treated with untwisting: Second look 36 hours after untwisting. *J Minim Invasive Gynecol.* 2007;14(3):270.
17. Oelsner G, Shashar D. Adnexal torsion. *Clin Obstet Gynecol.* 2006;49:459–63.
18. Bertozzi M, Esposito C, Vella C, Briganti V, Zampieri N, Codrich D, et al. Pediatric Ovarian Torsion and its Recurrence: A Multicenter Study. *J Pediatr Adolesc Gynecol.* 2017;30(3):413–7.
19. Geimanaite L, Trainavicius K. Ovarian torsion in children: management and outcomes. *J Pediatr Surg.* 2013;48(9):1946–53.

Author biography

Fozia Jeelani Wani, Assistant Professor

Yoga Nagendhar, Senior Consultant

Rani Reddy, Professor

Cite this article: Wani FJ, Nagendhar Y, Reddy R. A rare case of ovarian torsion in premenarcheal age- Case report and review of literature. *Indian J Obstet Gynecol Res* 2023;10(4):494-497.