

Content available at: <https://www.ipinnovative.com/open-access-journals>

Indian Journal of Obstetrics and Gynecology Research

Journal homepage: [www.ijogr.org](http://www.ijogr.org)

## Case Report

# Management of venous thromboembolism as a complication after Total laparoscopic hysterectomy with bilateral salpingectomy: A case report

Anjani Dixit <sup>1</sup>\*<sup>1</sup>Dept. of Obstetrics and Gynecology, Pristyn Care, Bengaluru, Karnataka, India

### ARTICLE INFO

#### Article history:

Received 27-07-2023

Accepted 07-08-2023

Available online 22-11-2023

#### Keywords:

Total laparoscopic hysterectomy

Bilateral salpingectomy

Venous thromboembolism

Endometrial hyperplasia

### ABSTRACT

Total laparoscopic hysterectomy (TLH) is a common procedure in gynecology, often performed to treat various gynecologic conditions. This case report presents a patient who underwent TLH with bilateral salpingectomy and subsequently developed a pulmonary embolism (PE) postoperatively. The patient, a 49-year-old woman with a history of adenomyosis and abnormal uterine bleeding (AUB) associated with endometrial hyperplasia – AUB-M, developed difficulty breathing and chest pain two days after surgery. Diagnostic tests revealed acute PE affecting both main pulmonary arteries. The patient received prompt medical treatment in the intensive care unit (ICU), including anticoagulation therapy, diuretics, oxygen support, and antibiotics. Her condition gradually improved, and she was discharged on oral anticoagulation medication after five days. The case highlights the importance of considering venous thromboembolism (VTE) as a potential complication, even in low-risk patients, and the need for further research to identify additional risk factors and improve preoperative care to prevent such life-threatening complications.

This is an Open Access (OA) journal, and articles are distributed under the terms of the [Creative Commons Attribution-NonCommercial-ShareAlike 4.0 License](https://creativecommons.org/licenses/by-nc-sa/4.0/), which allows others to remix, tweak, and build upon the work non-commercially, as long as appropriate credit is given and the new creations are licensed under the identical terms.

For reprints contact: [reprint@ipinnovative.com](mailto:reprint@ipinnovative.com)

## 1. Introduction

Total laparoscopic hysterectomy (TLH) represents an advanced laparoscopic technique in the field of gynecology. Indications for TLH include a variety of gynecologic conditions such as abnormal uterine bleeding (AUB), fibroids, endometriosis, adenomyosis, pelvic organ prolapse, and cancer. AUB is frequently associated with endometrial hyperplasia (AUB-M), which is often an indication of TLH in perimenopausal women. It refers to a condition where there is excessive growth of the endometrial lining of the uterus. This can cause irregular, heavy, or prolonged menstrual bleeding. If left untreated, endometrial hyperplasia can increase the risk of developing endometrial cancer.<sup>1</sup>

Postoperative complications of hysterectomy can include bleeding, infection, thrombosis, damage to surrounding

structures, and bowel or bladder problems. Various factors can increase the risk of developing venous thromboembolism (VTE).<sup>2</sup> These include a past medical history of VTE, recent major surgery, prolonged use of general anesthesia (GA), pregnancy, prolonged periods of immobility, age over 50 years, obesity, and the presence of an underlying malignancy. Additionally, major trauma and the use of venous catheters can increase the risk of deep vein thrombosis (DVT) or pulmonary embolism (PE) in any location.<sup>3</sup>

Here we present a case of TLH and bilateral salpingectomy in a patient who developed PE postoperatively which was successfully managed medically.

## 2. Case Presentation

A 49-year-old woman, moderately built and nourished with normal body mass index (BMI), reported a chief complaint of heavy menstrual bleeding accompanied by blood clots

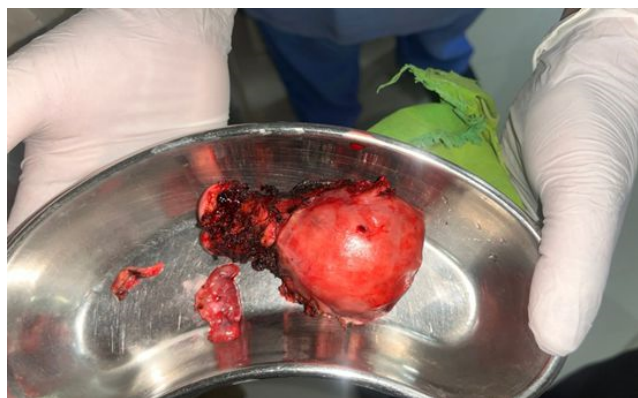\* Corresponding author.

E-mail address: [dr.anjani.dixit@pristyncare.com](mailto:dr.anjani.dixit@pristyncare.com) (A. Dixit).

on and off for the last two months managing with 3-4 sanitary napkins per day. The patient had a history of meningioma, diagnosed two years ago. On serial magnetic resonance imaging (MRI) meningioma was static in its growth. The patient is on a medication tablet of Levipil 500 mg thrice daily and a tablet of Nicerbium once daily. An endometrial biopsy was performed that was suggestive of cystic hyperplasia without atypia. Based on the clinical presentation and investigational findings the patient was diagnosed with adenomyosis and AUB-M.

### 2.1. Investigations

Upon examination, her vitals were found to be normal. Systemic examination and blood examination were within normal limits. Based on the results of Echocardiography, chambers were found to be normal and the ejection fraction (EF) was reported to be 60%. After the assessment of physical fitness, a pre-anesthesia check (PAC) was performed. The patient received an American Society of Anesthesiologists (ASA) score of 2. Subsequently, the patient underwent TLH (Fig. 1) and bilateral salpingectomy under GA.



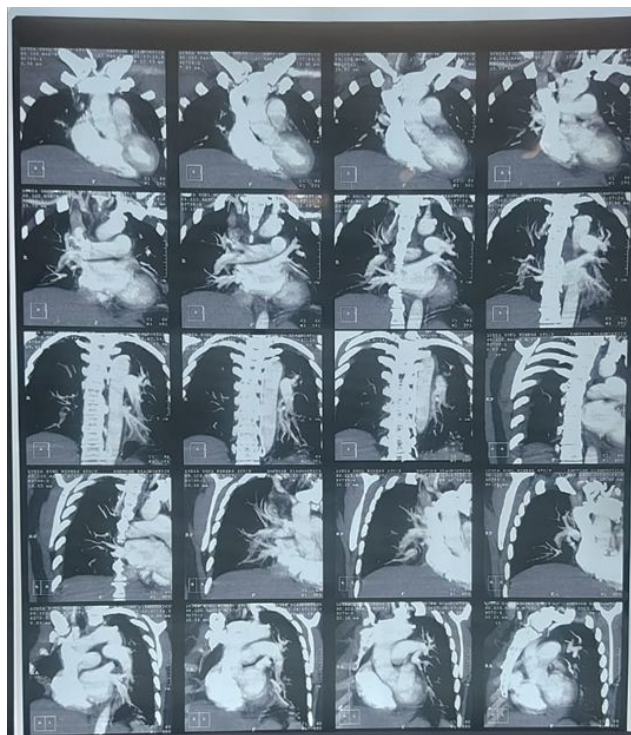**Figure 1:** Patient's uterus after total laparoscopic hysterectomy with bilateral salpingectomy

### 2.2. Treatment procedure

She was kept in the Trendelenburg position during the laparoscopic procedure. Intraoperatively, the uterus was observed to be slightly bulky. The left side tube and ovaries were found to adhere to the lateral pelvic wall and large intestines. The right-side tube and ovaries were free. Both right and left side fallopian tubes and ovaries were normal in morphology. Adhesiolysis of left side adnexa was performed and hemostasis was achieved. The uterus along with both the fallopian tubes was removed and sent for histopathological examination. Total operation time was 2 hours.

### 2.3. Postoperative course of the patient

Post-surgery, the vitals of the patients were found to be normal. The patient was mobilized early 8-10 hours after the surgery. Twelve hours after the surgery Enoxaparin 1mg/kg (60 mg) was given. On the 2nd day post-operation, the patient started complaining about difficulty in breathing and chest pain. Upon examination, her pulse rate was high (104 bpm) with Spo<sub>2</sub>- 95% at room air and BP - 110/70mmHg. Crepitations were noted on the left lower side of the respiratory system. Electrocardiogram (ECG) showed sinus tachycardia with non-specific ST and T-wave changes (ST-T). Repeated 2D echocardiogram showed dilation in the right atrium, right ventricle, and EF (60%). Immediately computed tomography pulmonary angiogram (CTPA) was done which (Fig. 2) revealed wedge-shaped opacities in both lower lobes with pulmonary thromboembolism affecting both main pulmonary arteries and branching into segmental and subsegmental arteries. Acute PE was diagnosed, which is a life-threatening condition that occurs when a blood clot travels to the lungs and obstructs blood flow.



**Figure 2:** Computed tomography pulmonary angiogram of the patient

The patient was immediately shifted to the intensive care unit (ICU) for continued care and received prompt treatment, including injectable low-molecular-weight heparin (LMWH) 1 mg/kg enoxaparin, diuretics, oxygen support, nebulization, antibiotics, and other supportive drugs. After continuous vital monitoring, the oxygen

support was gradually weaned off.

As the patient's condition gradually improved, she was discharged after 5 days on oral anticoagulation medicines.

### 3. Discussion

Irregular bleeding in the uterus, especially during menopause, is a significant indicator of endometrial hyperplasia. A substantial proportion, about 10-20%, of postmenopausal bleeding cases can be attributed to either hyperplasia or cancer. Therefore, it is crucial to promptly investigate any anomalous bleeding by performing either imaging or collecting tissue samples for pathology analysis.<sup>1</sup> VTE is a medical condition characterized by the formation of a blood clot within a vein. This condition encompasses two distinct disorders: DVT, in which a blood clot forms within the deep veins of the body, and PE, which occurs when a blood clot dislodges from its original site and migrates through the bloodstream to obstruct the pulmonary arteries of the lungs. Several factors have been identified as potential risk factors for VTE, including but not limited to age, race, cancer, use of pharmacological thromboprophylaxis, duration of surgery, ASA score, and BMI.<sup>2,4</sup> ASA physical status (ASAPS) classification system consists of six categories ranging from ASA 1 to ASA 6, with ASA 1 representing healthy patient and ASA 6 representing the most severe condition.<sup>5</sup>

The three primary surgical approaches for hysterectomy are the abdominal, laparoscopic, and vaginal routes. In the context of benign indications, hysterectomy procedures are not frequently associated with the development of VTE. In a study conducted in 2018 by Jorgensen et al. Out of 8,273 patients who underwent hysterectomy via vaginal (768), abdominal (4,697), and laparoscopic (2,808) approaches, the incidence of VTE was found to be 0.7% highlighting the rarity of this condition. In the same study it was found that, in comparison to laparotomy, laparoscopic surgery is linked with a 78% reduced chance of developing VTE, while vaginal surgery has been associated with a 93% lower risk of VTE.<sup>4</sup>

In various studies, it was observed that patients with VTE had a longer operation and hospitalization time and had an ASA score of 3 or more than 3.<sup>6</sup> It's said that large myoma surgeries are at higher risk of developing VTE due to the compression effect on large veins- leading to blood stasis, endothelial damage, and increased propensity to a hypercoagulable state (Virchow Triad).<sup>7,8</sup> But in the presented case, the uterus was slightly bulky with no myoma. The duration of surgery was also 120 minutes and the ASA score was 2. Thus, our patient was at low risk of developing such a grave complication but still, the patient developed VTE which was managed later. Therefore, this case signifies the importance of considering the postoperative risk of VTE even in a low risk patient.

### 4. Conclusion

Risk stratification is important but more important than that is high suspicion for postoperative VTE even if the patient falls in the low-risk category. More studies are needed to explore more factors that can help in patient risk stratification and help guide to modify pre-operative care so that such life-threatening complications can be avoided.

### 5. Source of Funding

None.

### 6. Conflict of Interest

None.


### 7. Acknowledgement

None.

### References

1. Ring KL, Mills AM, Modesitt SC. Endometrial Hyperplasia. *Obstet Gynecol.* 2022;140(6):1061–75.
2. Khan F, Tritschler T, Kahn SR, Rodger MA. Venous thromboembolism. *Lancet.* 2021;398(10294):64–77.
3. Nartey YA, Botchway ET, Lovi J. Case report: a challenging case of bilateral pulmonary embolism, deep venous thrombosis and bleeding uterine fibroids in a resource poor setting in Ghana. *PAMJ - Clin Med.* 2020;2(55):55. doi:10.11604/pamj-cm.2020.2.55.21201.
4. Jorgensen EM, Li A, Modest AM, Leung K, Simas TAM, Hur HC. Incidence of Venous Thromboembolism After Different Modes of Gynecologic Surgery. *Obstet Gynecol.* 2018;132(5):1275–84.
5. Doyle DJ, Hendrix JM, Garmon EH. American Society of Anesthesiologists Classification (Internet). Treasure Island (FL): StatPearls Publishing; 2023.
6. Shaikh MA, Jeong HS, Mastro A, Davis K, Lysikowski J, Kenkel JM. Analysis of the American Society of Anesthesiologists Physical Status Classification System and Caprini Risk Assessment Model in Predicting Venous Thromboembolic Outcomes in Plastic Surgery Patients. *Aesthet Surg J.* 2016;36(4):497–505.
7. Huang HK, Kor CT, Chen CP, Chen HT, Yang PT, Tsai CD, et al. Increased Risk of Venous Thromboembolism in Women with Uterine Leiomyoma: A Nationwide, Population-Based Case-Control Study. *Acta Cardiol Sin.* 2018;34(1):66–76.
8. Kushner A, West WP, Suheb K, Pillarisetty MZ, Triad LSV. Virchow Triad (Internet). Treasure Island (FL): StatPearls Publishing; 2022. Available from: <https://www.ncbi.nlm.nih.gov/books/NBK539697/>.

### Author biography

Anjani Dixit, Consultant Gynecologist Laparoscopy Surgeon and Fertility Specialist  <https://orcid.org/0000-0002-4687-1464>

**Cite this article:** Dixit A. Management of venous thromboembolism as a complication after Total laparoscopic hysterectomy with bilateral salpingectomy: A case report. *Indian J Obstet Gynecol Res* 2023;10(4):505-507.