

Content available at: <https://www.ipinnovative.com/open-access-journals>

Indian Journal of Obstetrics and Gynecology Research

Journal homepage: [www.ijogr.org](http://www.ijogr.org)

## Case Series

## Genetic abnormalities in sonographically detected heart diseases in antenatal period: A case series

Yogeshkumar Siddhyeshwar Chaudhary<sup>1\*</sup>, Sachin Shridhar Patil<sup>2</sup>,  
Varun Ashok Thakur<sup>3</sup><sup>1</sup>Bhakti Sonography Clinic, Chinchwad, Maharashtra, India<sup>2</sup>Neo Diagnostic Center, Chinchwad, Maharashtra, India<sup>3</sup>Shri Mauli Diagnostic Center, Pimpri-Chinchwad, Maharashtra, India

## ARTICLE INFO

## Article history:

Received 05-04-2023

Accepted 31-08-2023

Available online 22-11-2023

## Keywords:

Congenital heart disease

Genetic abnormalities

Prenatal

Cardiac genetic

Ultrasound

## ABSTRACT

**Background:** Recent advances in molecular genetic techniques have found evidence of the role of genetic factors in the development of CHD. Approximately 30% of CHD is thought to be related to genetic syndromes accompanied by extra-cardiac anomalies. We describe the cases of cardiac anomalies detected on prenatal ultrasound, which helped us in suspecting the genetic abnormality in fetus which were later confirmed by definitive testing.

**Materials and Methods:** Prospective evaluation and follow up of 10 cases done which showed cardiac and extracardiac findings suspicious of chromosomal disorder.

**Result and Conclusion:** Definitive testing showed genetic abnormality in (N = 10) cases. We could detect Trisomy 21 in (N = 3), Trisomy 18 in (N=2), Trisomy 13 in (N=2), Triploidy in (N=1) and Monosomy X (Turners) in (N=2) cases in our series. Detection of abnormal cardiac findings can definitely improve the detection rate of genetic disorders and positive yield of genetic testing.

This is an Open Access (OA) journal, and articles are distributed under the terms of the [Creative Commons Attribution-NonCommercial-ShareAlike 4.0 License](https://creativecommons.org/licenses/by-nc-sa/4.0/), which allows others to remix, tweak, and build upon the work non-commercially, as long as appropriate credit is given and the new creations are licensed under the identical terms.

For reprints contact: [reprint@ipinnovative.com](mailto:reprint@ipinnovative.com)

## 1. Introduction

Recent advances in molecular genetic techniques have found evidence of the role of genetic factors in the development of congenital heart disease (CHD). Approximately 30% of CHDs are thought to be related to genetic syndromes accompanied by extra-cardiac anomalies. In our case series, we could diagnose (N=10) cases in which cardiac anomalies along with the extra cardiac findings in fetus has helped us in suspecting the underlying genetic abnormality which was later confirmed by definitive genetic testing. We feel that the targeted genetic testing based on ultrasound findings can definitely increase the positive yield of genetic test.

## 2. Introduction

Current research indicates that congenital heart disease (CHD) is the most common birth defect affecting nearly 10 to 12 per 1000 live born infants (1%–1.2%).<sup>1–3</sup> It is an important cause of morbidity and mortality during infancy and childhood. The etiology of CHD is multifaceted including environmental, genetic, and stochastic factors.<sup>4,5</sup> Knowing the basis of the CHD will aid in the counseling of parents and help them to attain a complete understanding of the fetal cardiac defect.<sup>6</sup>

Ongoing advances in molecular genetics are leading to an increasingly better understanding of the etiology of congenital heart diseases (CHDs). In the past, the specific role of genetic factors in the pathogenesis of these defects was not completely appreciated. Except for a few cases,

\* Corresponding author.

E-mail address: [dryogi76@gmail.com](mailto:dryogi76@gmail.com) (Y. S. Chaudhary).

it was thought that the most common cardiac lesions in the general population were those occurring in patients with chromosomal abnormalities, such as Down syndrome (DS).<sup>7</sup> Recent advances in molecular genetic techniques have found the evidence of role of genetic factors in the development of CHD. Approximately 30% of CHDs are thought to be related to genetic syndromes accompanied by extra-cardiac anomalies.<sup>8</sup> Single-gene disorders are found in 3% to 5%, gross chromosomal anomalies/aneuploidy in 8% to 10%, and pathogenic CNVs in 3% to 25% of those with CHD as part of a syndrome, and in 3% to 10% among those with isolated congenital heart disease.<sup>9</sup>

It is known that underlying genetic conditions have an increasingly recognized impact on the anatomical and functional complexity of CHDs and could represent additional risk factors or even protective factors for cardiac surgery and clinical outcomes.<sup>10–14</sup> It is even more clear that early identification of the genetic causes of CHDs is expected to allow our understanding of the underlying pathogenetic mechanisms that influence the clinical and surgical outcome of a specific subtype of CHD.<sup>15</sup> Similarly, the identification of genotype–phenotype correlations is predicted to guide a more effective personalized management of patients with cardiac defects, improving quality of life and long-term outcome.<sup>14</sup> Recent studies showed that precision medicine using genotype–phenotype correlation data is able to guide not only risk stratification, but also identification of treatments that can modify the molecular mechanism of the disease.<sup>16–18</sup>

In our case series, we have described different cardiac anomalies along with the extracardiac findings in fetus which has helped us in suspecting the underlying genetic abnormality in fetus which was later confirmed by definitive genetic testing. Cardiac anomalies provide direct or indirect clue for genetic abnormalities on ultrasound in all trimesters hence it becomes relatively easy to suspect and diagnose the underlying genetic etiology. Targeted genetic testing based on ultrasound findings can definitely increase the positive yield of genetic test.

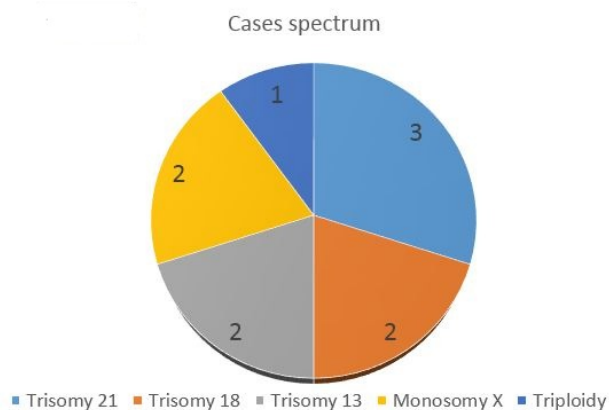
### 3. Materials and Methods

Prospective evaluation of 10 cases was done between gestational age of 12 weeks to 34 weeks with detailed ultrasound examination as per the ISUOG guidelines. Careful evaluation was done to look for cardiac and extra-cardiac anomalies. Detailed counselling was done as per the ultrasound findings and definitive genetic testing was advised to the family either before or after the termination as per the severity of the anomaly. Multidisciplinary approach was followed with involvement of imaging specialist, obstetrician, geneticist and fetal medicine specialists to reach the final diagnosis. Definitive genetic tests done were karyotype (KT), Fluorescent in situ hybridization (FISH), Chromosomal microarray (CMA), Quantitative fluorescent

PCR (QF-PCR) and whole exome sequencing (WES) as per the indication.

### 4. Results

Definitive testing showed genetic abnormality in (N = 10) cases. We could detect Trisomy 21 in (N = 3), Trisomy 18 in (N=2), Trisomy 13 in (N=2), Triploidy in (N=1) and Turners syndrome [Monosomy X] in (N=2) cases in our series (Figure 1). Detailed summary of cases is as per the table contents (Table 1). Out of 10 cases, only in one case diagnosis was made before termination by amniocentesis, in two cases diagnosis was made after the delivery, in 6 cases diagnosis was made after the termination of pregnancy in view of major anomalies and in one case parental test was done which showed genetic abnormality. Common indirect ultrasound findings detected were increased nuchal translucency (NT), tricuspid regurgitation (TR) and short nasal bone (NB). Common cardiac anomalies found associated with genetic disease were atrio-ventricular septal defect (AVSD), Tetralogy of Fallot (TOF), Common arterial trunk (CAT) and Coarctation of aorta.



**Figure 1:** Cases spectrum

We discuss here few representative cases from our antenatal case series which revealed indirect cardiac findings and typical cardiac anomalies associated with underlying genetic abnormality in fetus.

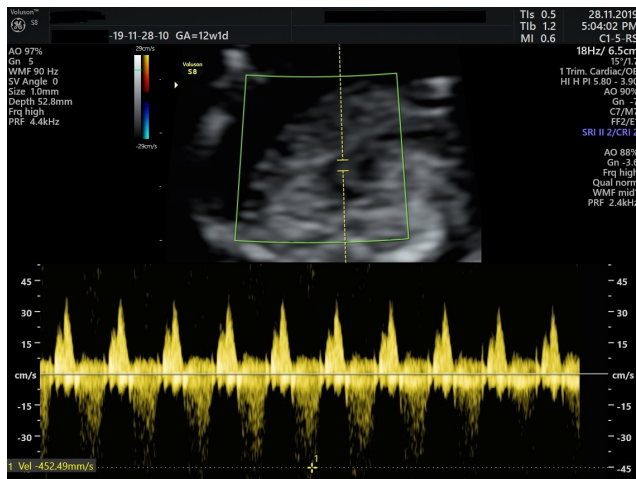
#### 4.1. Case 1

Primi, age 26yrs came for NT scan at 12 weeks of gestation without any significant prior history. Study revealed non ossified nasal bone, tricuspid regurgitation, reversal of 'a' wave in ductus venosus (DV) and mild renal pyelectasis. In view of multiple soft markers of aneuploidy the option of definitive genetic test was offered. However chorionic villous sampling (CVS) was denied by parents and they opted for an early anomaly scan. Follow up scan at 16 week revealed short nasal bone, tricuspid regurgitation

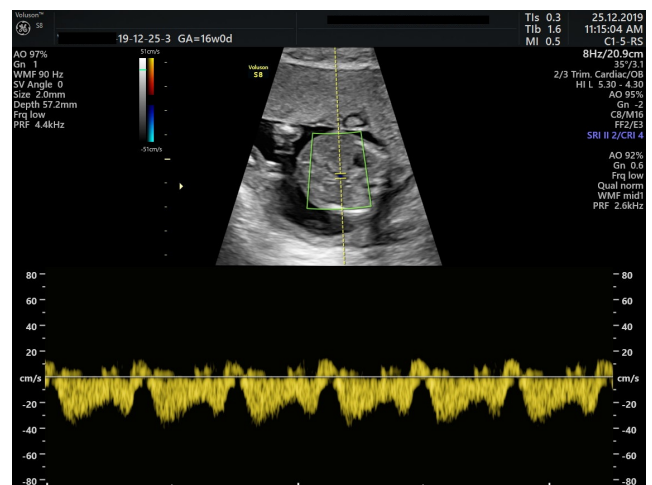
**Table 1:** Cases summary

No.	Gestational age (Weeks)	Cardiac anomaly	Test done	Diagnosis
1	12 and 16	Tricuspid regurgitation	FISH	Trisomy 21
2	35	Atrioventricular septal defect	CMA	Trisomy 21
3	18	Tetralogy of Fallots	CMA	Trisomy 18
4	12 and 16	Interrupted aortic arch	QF-PCR	Trisomy 18
5	16	Persistent left sided superior vena cava (PLSVC)	QF-PCR	Triploidy
6	12	Coarctation of Aorta	QF-PCR	Monosomy X
7	12 and 18	Tricuspid regurgitation	CMA	Trisomy 21
8	12 and 14	Tetralogy of Fallot	Karyotype	Trisomy 13
9	12	Coarctation of Aorta	QF-PCR	Monosomy X
10	13	Aberrant right subclavian artery (ARSA), Polyvalvular dysplasia	Karyotype (Father)	Trisomy 13

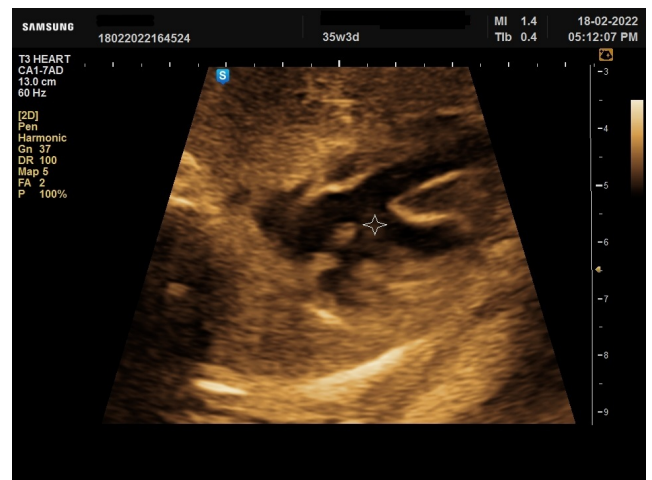(Figure 2), reversal of ‘a’ wave in ductus (Figure 3), mild renal pyelectasis and brachycephaly. No other anomaly was found in fetus. In view of these findings definitive test was planned. Amniocentesis was done and extended FISH revealed Trisomy 21. After the final diagnosis couple opted for termination.



**Figure 2:** Tricuspid regurgitation



**Figure 3:** Reversal of ‘a’ wave



**Figure 4:** AVSD

**4.2. Case 2**

Primi, 29 yrs, screen negative came for growth scan at 35 weeks of gestation. Study revealed balanced atrioventricular septal defect (Figure 4) and short nasal bone. There was also a mild hydroamnios and short femur. Doppler findings were within normal limits. In view of these findings possibility of Downs syndrome was considered and post natal evaluation was recommended. However, there was a full term fetal demise. Post natal fetal genetic testing (QF-PCR) revealed Trisomy 21.

### 4.3. Case 3

Primi, 32 yrs, previous history of one first trimester pregnancy loss, came for an anomaly scan at 18 weeks of gestation. Cardiac evaluation revealed small membranous ventricular septal defect (VSD) with overriding of aorta & small pulmonary artery but forward flow ('Y' sign) which is suggestive of tetralogy of fallot (Figure 5). Other findings in this fetus were partial agenesis of corpus callosum and Blakes pouch cyst. Post termination CMA revealed Trisomy 18.

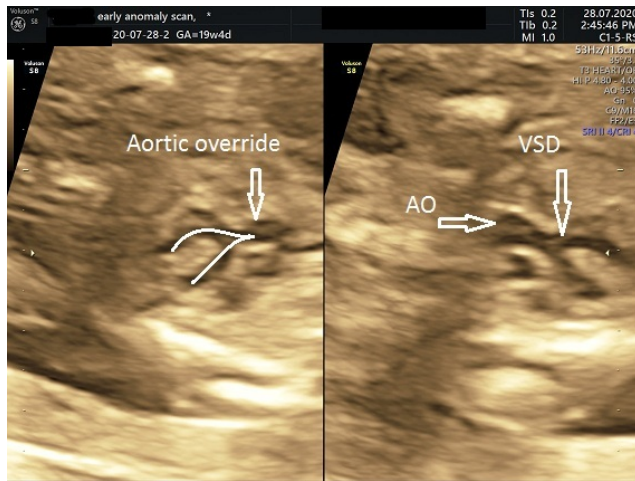


Figure 5: Fallots tetralogy

### 4.4. Case 4

26yrs, second gravida with previous history of first trimester termination of pregnancy due to fetal inencephaly, now came for NT scan. There was a thick NT, short nasal bone and small left ventricle, small aorta on cardiac evaluation. Decided to do an early anomaly scan and definitive test later. 16 weeks scan revealed small left ventricle and small left atrium (Figure 6), tricuspid regurgitation, aortic arch interruption and choroid plexus cysts (CPC). Other findings were short nasal bone, short neck, echogenic bowel and small low set ears. Couple opted for termination of pregnancy and QF-PCR revealed trisomy 18. Exome sequencing revealed trisomy 18 like syndrome (autosomal recessive) pathogenic and Fabry disease (X linked recessive) likely pathogenic.

### 4.5. Case 5

25 yrs, primi came for an early anomaly scan in view of 12 weeks scan showed prominent NT. First trimester screening was low risk. 16 weeks scan revealed cardiomegaly with dilated right atrium and right ventricle, persistent left superior vena cava, aberrant right subclavian artery (Figure 7), and dilated coronary sinus. Additional

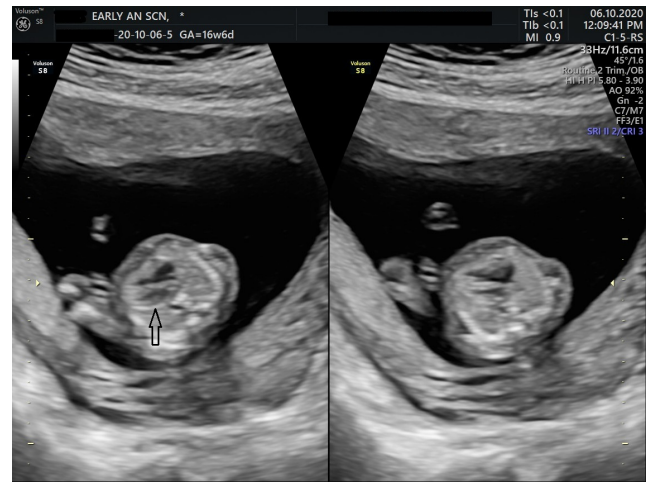


Figure 6: Small left ventricle

findings in this fetus were choroid plexus cyst, dilated fourth ventricle, reversal of 'a' wave in ductus, clenched hands, micrognathia & large size head with small belly. In view of suspected syndromic condition couple opted for termination and QF-PCR revealed Triploidy.

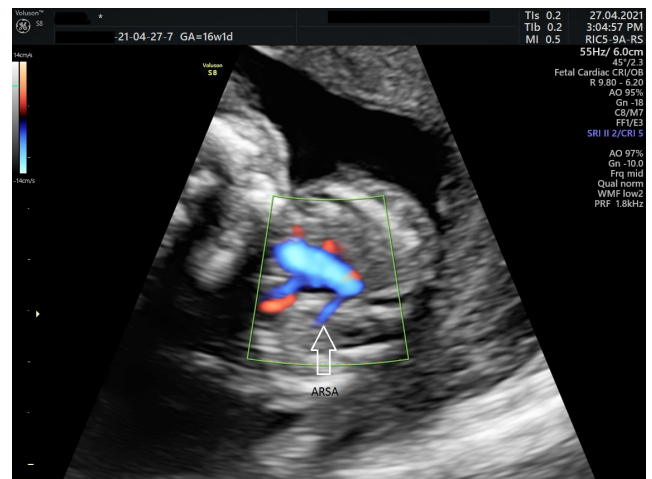
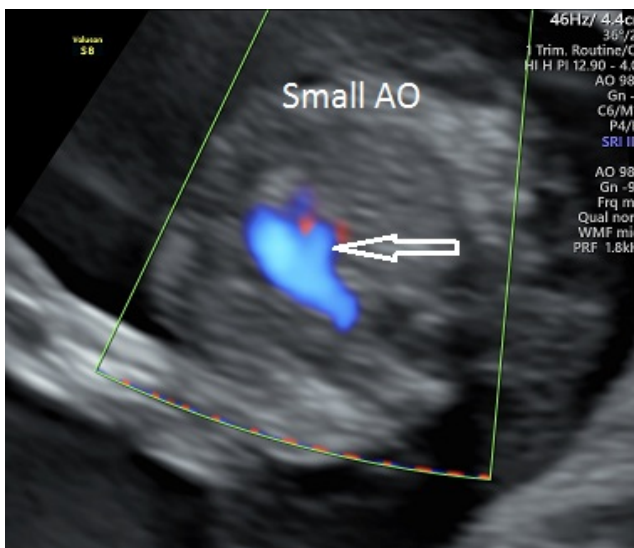


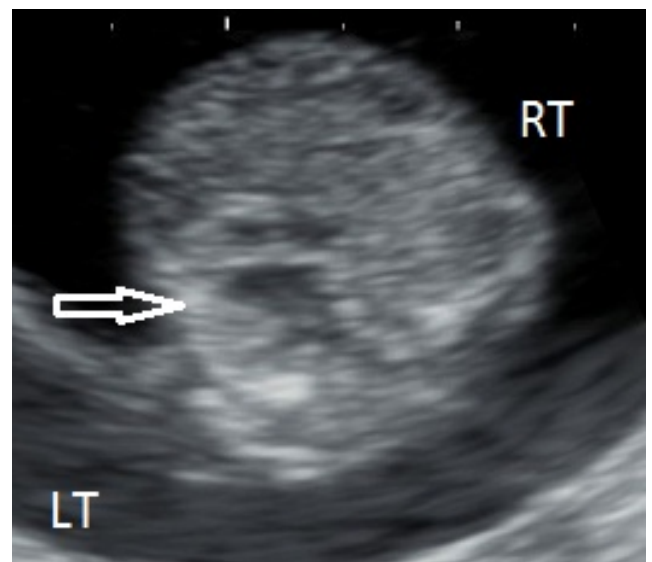
Figure 7: ARSA

### 4.6. Case 6

27 yrs, third gravida with previous two first trimester abortions, came for NT scan at 12 weeks, which revealed thick NT, fetal hydrops, and small left ventricle, small aorta but forward flow suggesting coarctation of aorta (Figure 8). There was a fetal tachycardia with fetal heart rate 186 beats per minute. Post termination QF-PCR revealed Monosomy-X.



**Figure 8:** Small AO



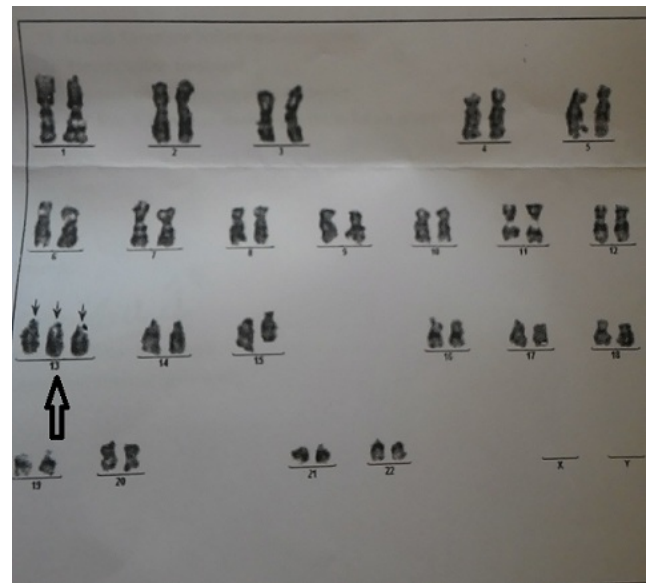
**Figure 9:** Left lung hypoplasia

#### 4.7. Case 7

36yrs, second gravida came for NT scan which showed short nasal bone, NT mes. 2.2 mm, tricuspid regurgitation and mild pyelectasis. Screening test came low risk. Anomaly scan revealed only tricuspid regurgitation otherwise no significant abnormality in fetus. They decided to continue the pregnancy. There was a late onset intrauterine growth restriction on follow up scans, with long bone shortening in third trimester. Term delivery conducted and baby revealed dysmorphic features and genetic testing showed Trisomy 21.

#### 4.8. Case 8

28 yrs, second gravida came for NT scan which revealed, membranous VSD and smaller pulmonary artery suggestive of tetralogy of Fallots, cardiac shift to left due to left lung hypoplasia (Figure 9). Findings were same at the 14 weeks follow up scan. No other abnormality was seen in fetus. Parents decided to terminate the pregnancy and post termination karyotype revealed trisomy 13 (Figure 10).



**Figure 10:** Karyotype trisomy 13

## 5. Discussion

In recent times increased routine prenatal ultrasound screening, improvement in ultrasound technology and expertise of fetal medicine specialist and radiologist, has increased prenatal detection of congenital heart defects.<sup>19,20</sup> Genetic testing for congenital HD has increased over the past 10 years<sup>21,22</sup> and is particularly helpful in diagnosing syndromes responsible for CHD and related noncardiac phenotypes that might require clinical management.<sup>22–24</sup> The earliest identifiable genetic cause of CHD is aneuploidy (e.g., trisomies like 13, 18, 21) on fetal

ultrasound and maternal serum biomarkers screening. Due to earlier detection of fetal anomalies on ultrasound and broader availability of screening and diagnostic genetic tests prenatally, it is now routine practice to get the testing done early in antenatal period.<sup>25</sup> Occurrence of specific associations between CHDs and extracardiac (EC) malformations, including those defining genetic syndromes, has been reported within a high percentage of children with an atrioventricular canal defect (AVCD) (approximately 75%) and, less frequently, in children with a ventricular septal defect (VSD), patent ductus arteriosus (PDA) and Tetralogy of Fallot (TOF) (about 25%). Extremely

rare associations have been reported when considering other cardiac defects, such as transposition of the great arteries (TGA) and pulmonary atresia (PA) with intact interventricular septum.<sup>26</sup>

In our cases we carefully looked for minor cardiac findings like tricuspid regurgitation and reversal of 'a' wave in ductus as well as major anomalies like atrioventricular septal defect, membranous VSD, outlet anomalies and coarctation of aorta which have more association with underlying genetic abnormality. In the cases of more than two soft markers and an obvious cardiac anomaly, definitive genetic testing was considered over the screening tests which has increased the yield of positive genetic diagnosis.

Understanding the genetic etiology in patients with both congenital heart disease and other anomalies can help the clinicians in parenteral counselling and effective planning of post-natal surgical and medical management and follow-up.<sup>27</sup> Important reasons for determining the genetic cause can include (1) assessing recurrence risks in subsequent pregnancy for the same parents and in their close relatives; (2) evaluating for associated extracardiac involvement; (3) assessing risk for neurodevelopmental delays for newborns and infants and (4) providing more accurate prognosis for the CHD and outcomes for CHD related interventions.<sup>9</sup> Hence the genetic counselling should become an integral part of our practice.

## 6. Conclusion

Careful cardiac evaluation for anomalies can definitely improve the detection rate of genetic disorders and positive yield of genetic testing. Cardiac anomalies can act as a simple window for more complex genetic syndromes in the fetus. Cardiac screening should be incorporated in the prenatal ultrasound examination from 11-14 weeks onwards and in cases of obvious cardiac anomalies and more than two soft markers, definitive genetic testing should be preferred. In lately diagnosed cases perinatal genetic testing also can be offered which helps in planning of postnatal management and prediction of its outcome.

Besides the complexity of the cardiac anomaly, its genetic origin has a crucial impact on postnatal outcome and understanding the recurrence risk, hence the definitive genetic testing should be offered to every cardiac anomaly detected in prenatal life.

## 7. Source of Funding

None.

## 8. Conflict of Interest

None.

## Acknowledgements

We thank, Dr. Shrikant T. Ambardekar, Dr. Rupanjal Akash Thube, Dr. Soumya Kulkarni, Dr. Harshwardhan Ingley, for

comments and cases follow up that greatly improved the manuscript.

## References

1. Linde DVD, Konings EE, Slager MA, Witsenburg M, Helbing WA, Takkenberg JJ, et al. Birth prevalence of congenital heart disease worldwide: a systematic review and meta-analysis. *J Am Coll Cardiol.* 2011;58(21):2241–7.
2. Hoffman JIE, Kaplan S. The incidence of congenital heart disease. *J Am Coll Cardiol.* 2002;39(12):1890–900.
3. Wren C. The epidemiology of cardiovascular malformations. In: Moller JH, editor. *Pediatric Cardiovascular Medicine.* UK: West Sussex: Blackwell Publishing; 2012. p. 268–75.
4. Jenkins KJ, Correa A, Feinstein JA, Botto L, Britt AE, Daniels SR, et al. Noninherited risk factors and congenital cardiovascular defects: Current knowledge: A scientific statement from the American Heart Association Council on cardiovascular disease in the young: Endorsed by the American Academy of Pediatrics. *Circulation.* 2007;115(23):2995–3014.
5. Pierpont ME, Basson CT, Benson DW, Gelb BD, Giglia TM, Goldmuntz E, et al. Genetic basis for congenital heart defects: Current knowledge: A scientific statement from the American Heart Association congenital cardiac defects committee, council on cardiovascular disease in the young: Endorsed by the American Academy of Pediatrics. *Circulation.* 2007;115(23):3015–38.
6. Williams IA, Shaw R, Kleinman CS, Gersony WM, Prakash A, Levasseur SM. Parental understanding of neonatal congenital heart disease. *Pediatric Cardiology.* 2008;29(6):1059–1065.
7. Nora JJ. Causes of congenital heart diseases: Old and new modes, mechanisms, and models. *Am Heart J.* 1993;125(5 Pt 1):1409–19.
8. Eskedal LT, Hagemo PS, Eskild A, Frøslie KF, Seiler S, Thaulow E. A population-based study relevant to seasonal variations in causes of death in children undergoing surgery for congenital cardiac malformations. *Cardiol Young.* 2007;17(4):423–31.
9. Pierpont. Genetic Basis for Congenital HD: Revisited, A Scientific Statement From the American Heart Association. *Circulation.* 2018;138:653–711.
10. Anacleto S, Ciommo VD, Michielon G, Digilio MC, Formigari R, Picchio FM, et al. Conotruncal heart defects: impact of genetic syndromes on immediate operative mortality. *Ital Heart J.* 2004;5(8):624–8.
11. Formigari R, Donato RMD, Gargiulo G, Carlo DD, Feltri C, Picchio FM, et al. Better surgical prognosis for patients with complete atrioventricular septal defect and Down's syndrome. *Ann Thorac Surg.* 2004;78(2):666–72.
12. Carotti A, Digilio MC, Piacentini G, Saffirio C, Donato RMD, Marino B. Cardiac defects and results of cardiac surgery in 22q11.2 deletion syndrome. *Dev Disabil Res Rev.* 2008;14:35–42.
13. Formigari R, Michielon G, Digilio MC, Piacentini G, Carotti A, Giardini A, et al. Genetic syndromes and congenital heart defects: How is surgical management affected? *Eur J Cardiothorac Surg.* 2009;35:606–14.
14. Russell MW, Chung WK, Kaltman JR, Miller TA. Advances in the understanding of the genetic determinants of congenital heart disease and their impact on clinical outcomes. *J Am Heart Assoc.* 2018;7:e006906.
15. Digilio MC, Marino B. What is new in genetics of congenital heart defects? *Front Pediatr.* 2016;4:120. doi:10.3389/fped.2016.00120.
16. Habashi JP, Judge DP, Holm TM, Cohn RD, Loeys BL, Cooper TK, et al. Losartan, an AT1 antagonist, prevents aortic aneurysm in a mouse model of Marfan syndrome. *Science.* 2006;312(5770):117–21.
17. Marin TM, Keith K, Davies B, Conner DA, Guha P, Kalaitzidis D, et al. Rapamycin reverses hypertrophic cardiomyopathy in a mouse model of LEOPARD syndrome-associated PTPN11 mutation. *J Clin Invest.* 2011;121(3):1026–43.

18. Lania G, Bresciani A, Bisbocci M, Francone A, Colonna V, Altamura S, et al. Vitamin B12 ameliorates the phenotype of a mouse model of Di George syndrome. *Hum Mol Genet.* 2016;25(20):4369–75.
19. Friedberg MK, Silverman NH, Moon-Grady AJ, Tong E, Nourse J, Sorenson B, et al. Prenatal detection of congenital heart disease. *J Pediatr.* 2009;155:26–31.
20. Carvalho JS, Mavrides E, Shinebourne EA. Improving the effectiveness of routine prenatal screening for major congenital heart defects. *Heart.* 2002;88(4):387–91.
21. Glessner JT, Bick AG, Ito K, Homsy J, Rodriguez-Murillo L, Fromer M, et al. Increased frequency of de novo copy number variants in congenital heart disease by integrative analysis of single nucleotide polymorphism array and exome sequence data. *Circ Res.* 2014;115(10):884–96.
22. Richards AA, Garg V. Genetics of congenital heart disease. *Curr Cardiol Rev.* 2010;6(2):91–7.
23. Pierpont ME, Basson CT, Benson DW, Gelb BD, Giglia TM, Goldmuntz E, et al. Genetic basis for congenital heart defects: current knowledge: a scientific statement from the American Heart Association Congenital Cardiac Defects Committee, Council on Cardiovascular Disease in the Young. *Circulation.* 2007;115(23):3015–38.
24. Fahed AC, Gelb BD, Seidman JG, Seidman CE. Genetics of congenital heart disease: the glass half empty. *Circ Res.* 2013;112(4):707–20.
25. Findley N. Prenatal genetic diagnosis of congenital heart defects. *Transl Pediatr.* 2021;10(8):2157–70.
26. Greenwood RD, Rosenthal A, Parisi L, Fyler DC, Nadas AS. Extracardiac abnormalities in infants with congenital heart disease. *Pediatrics.* 1975;55(4):485–92.
27. Ko JM. Genetic Syndromes associated with Congenital Heart Disease. *Korean Circ J.* 2015;45(5):357–61.

## Author biography

**Yogeshkumar Siddhyeshwar Chaudhary**, Radiologist

**Sachin Shridhar Patil**, Radiologist

**Varun Ashok Thakur**, Fetal Medicine Specialist

**Cite this article:** Chaudhary YS, Patil SS, Thakur VA. Genetic abnormalities in sonographically detected heart diseases in antenatal period: A case series. *Indian J Obstet Gynecol Res* 2023;10(4):511-517.