

Content available at: <https://www.ipinnovative.com/open-access-journals>

Indian Journal of Obstetrics and Gynecology Research

Journal homepage: www.ijogr.org

Case Report

Ohvira syndrome with rare presentations – A case report

Sujatha M. S¹, Sinchana N², Prathap Talwar¹, Rudresh Hirmath², Dheshna N. J^{1*}

¹Dept. of Obstetrics and Gynecology, JSS Medical College, JSS Academy of Higher Education and Research, Mysore, Karnataka, India

²Dept. of Radiodiagnosis, JSS Academy of Higher Education and Research, Mysuru, Karnataka, India



ARTICLE INFO

Article history:

Received 06-09-2023

Accepted 30-10-2023

Available online 17-02-2024

Keywords:

OHVIRA

Herlyn Werner Wunderlich Syndrome

Pyometra

Mullerian anomalies

ABSTRACT

Herlyn Werner Wunderlich syndrome is a very rare congenital anomaly of the urogenital tract involving Mullerian ducts and mesonephric ducts. It is synonymous with OHVIRA syndrome which is Obstructed Hemivagina with Ipsilateral Renal Agenesis syndrome. Very few case reports have been reported regarding the syndrome. Herein, we report a case of 20 year old unmarried female with unusual presentation of OHVIRA syndrome with complaints of spotting per vagina and with vaginal cyst on examination. Diagnosis was confirmed by MRI which showed features of OHVIRA with pyometra caused by the obstructed hemivagina. She was managed surgically by diagnostic laparoscopy and per vaginal resection of the vaginal septum and drainage of around 50cc of pyometra followed by visualisation of two separate cervical canals post procedure. As a rare entity, a high degree of clinical suspicion is necessary to diagnose and intervene at the right time to ensure optimum results and prevent complications and preserve fertility.

This is an Open Access (OA) journal, and articles are distributed under the terms of the [Creative Commons Attribution-NonCommercial-ShareAlike 4.0 License](https://creativecommons.org/licenses/by-nc-sa/4.0/), which allows others to remix, tweak, and build upon the work non-commercially, as long as appropriate credit is given and the new creations are licensed under the identical terms.

For reprints contact: reprint@ipinnovative.com

1. Introduction

OHVIRA syndrome, also known as Herlyn-Werner-Wunderlich syndrome (HWW syndrome), is a Mullerian duct anomaly which is associated with uterus didelphys, unilateral obstructed hemivagina, and ipsilateral renal agenesis. OHVIRA syndrome belongs to the group of ORTAs (Obstructive reproductive tract abnormalities) with incidence varying between 0.1% and 3.8% in the general female population and 7% in all mullerian anomalies.¹ The patient presents with varying symptoms with most common symptoms being pelvic pain, vaginal mass and rarely primary infertility ; and usually presenting after menarche.² The average age of diagnosis ranged from 10-29 years with 14 years as the median age and pain being the most common symptom.³

2. Case Report

A 20-year old unmarried patient who was apparently normal one month ago when she developed spotting per vagina for one week, changed around 1 pad per day and was associated with white discharge per vagina. It was not associated with pain or passage of clots. She had no history of similar complaints in the past. Menarche attained at 11 years of age with past cycles of regular length and no menstrual complaints. Patient had consulted on OPD basis for the same for which USG abdomen and pelvis was done and it showed a bicornuate uterus with early PCOS changes and right lateral wall vaginal cyst. Patient was a known case of unilateral renal agenesis since birth. To rule out anomalies, MRI pelvis was done which showed OHVIRA syndrome with pyometra. Other haematological parameters were within normal limits.

* Corresponding author.

E-mail address: dr.dheshna97@gmail.com (Dheshna N. J).

2.1. Examination

General physical examination – normal, secondary sexual characters well developed, Tanner stage : 5,

Vitals – stable.

Per Abdomen: Soft, no palpable mass.

2.2. Local examination

External genitalia normal, Bulge of 5X5 cm seen in the vagina on the right side, non tender.

2.3. Investigations

USG: Bicornuate uterus; early polycystic ovaries ; Right lateral vaginal wall cyst – 8.1x3.3cm.

MRI:

1. Right kidney agenesis.
2. Uterine didelphys with obstructed hemi vagina resulting in pyometra and mass effect over left vaginal cavity with ipsilateral renal agenesis – HWW syndrome.(Figures 1, 2, 3, 4 and 5)

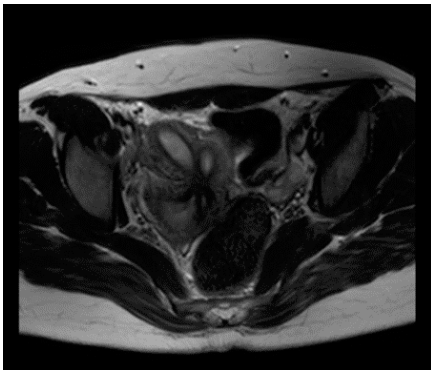


Figure 1: Uterus anteverted and anteflexed. Two separate uterine horns (cornu) noted with two separate cervical canals

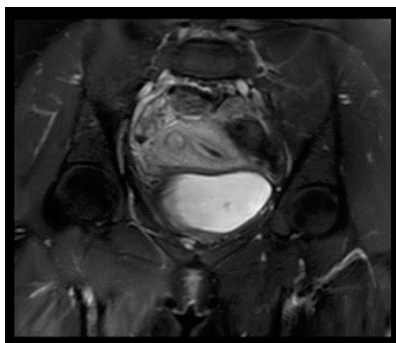

Figure 2: On post-contrast sequences the myometrium shows normal enhancement pattern. The collection in the distended right vaginal cavity shows peripheral enhancement

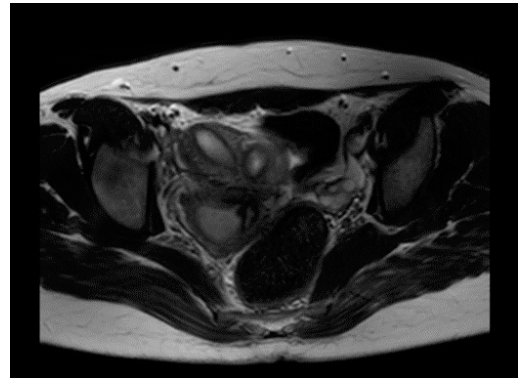


Figure 3: There is e/o dilated right vaginal cavity and filled with T1 hypointense and T2 hyperintense fluid showing diffusion restriction on DWI sequences. The dilated right vaginal cavity is causing mild mass effect over the collapsed left vaginal cavity

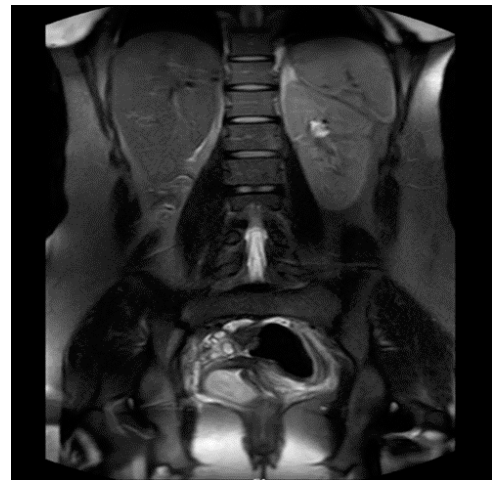

Figure 4: Both ovaries shows normal enhancement. Right kidney is not visualised in right renal fossa and ectopic locations - Likely agenesis. Left kidney shows compensatory hypertrophy

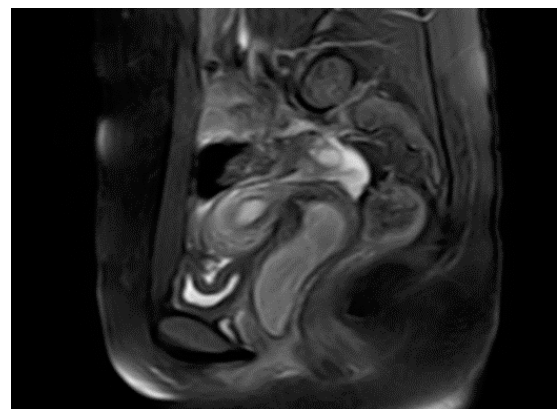


Figure 5: Features suggestive of uterine didelphys with obstructed right hemi vagina resulting in Pyocolpos with ipsilateral renal agenesis - Herlyn-Werner-Wunderlich syndrome

2.4. Procedure

Patient was planned for diagnostic laparoscopy with hysteroscopic septal resection. Under GA, laparoscopic ports created and instruments inserted.(Figure 6) On laparoscopy - bicornuate uterus seen and B/L tubes and ovaries were normal. On per vaginal examination, vaginal bulge on right side of 5x5cm.(Figure 7) Left side cervix seen and easily cannulated.(Figure 8) The Vaginal septum was excised and 50cc of pus was drained.(Figure 9) Right part of cervix was later felt and cannulated.(Figure 10) Later, the vaginal edges were sutured.(Figure 11) Pus drained was sent for culture and sensitivity and was found to be *escherichia coli* patient was started on appropriate antibiotics. Postoperative period was uneventful. Patient did not have any further menstrual irregularities.

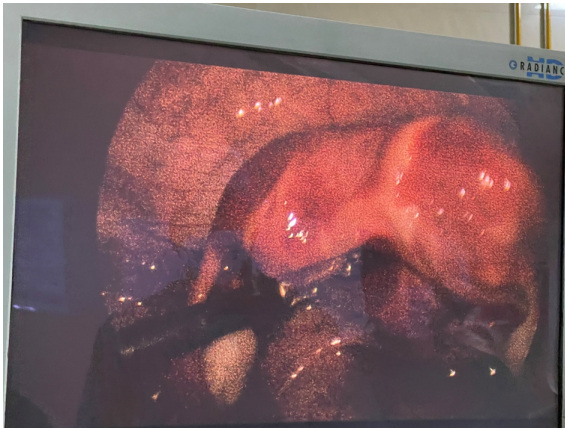

Figure 6: Diagnostic laparoscopy showing uterus didelphys with normal tubes

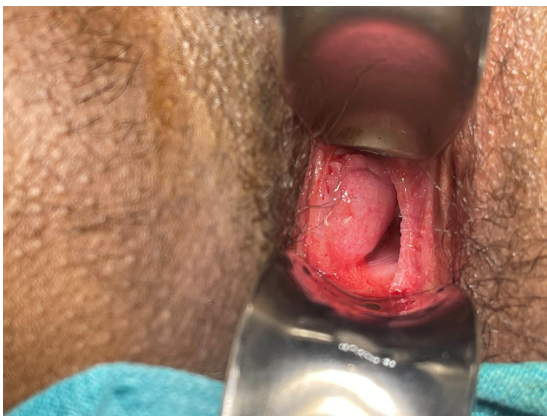

Figure 7: Local examination showing a bulge on the right vaginal wall

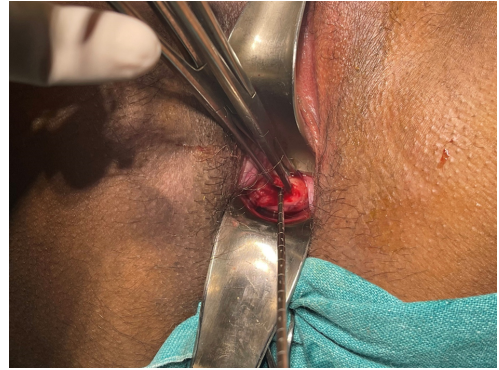


Figure 8: Left cervix visualised and easily cannulated

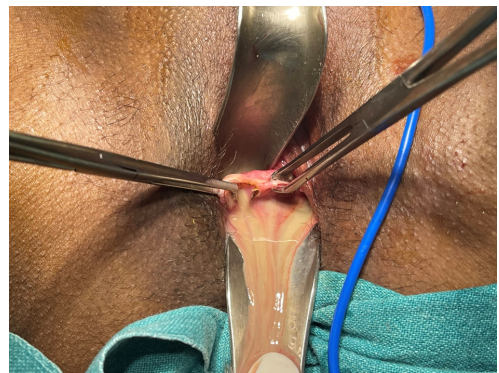

Figure 9: Cyst opened and 50cc pus drained

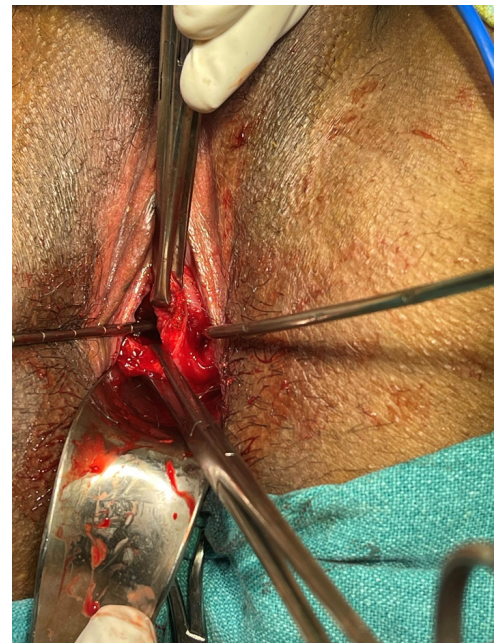

Figure 10: Right cervix visualised and cannulated

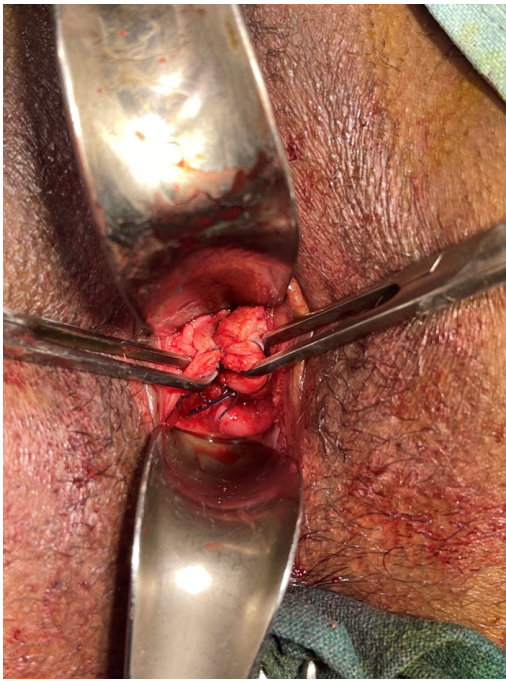


Figure 11: Vaginal mucosa edges sutured

3. Discussion

Purslow, in 1922, first reported this syndrome of obstructed hemivagina and ipsilateral renal anomaly.⁴ Subsequently, in 1983, Herlyn and Werner recognised similar cases analogous to the anomaly and since then the anomaly has been termed as “Herlyn – Werner - Wunderlich” syndrome.⁵ To aid in easy communication of the syndrome, in 2007, Smith and Laufer proposed the acronym of OHVIRA.⁶

Various extragenital anomalies are most often associated with female reproductive tract anomalies since the embryonal development of the urinary system occurs in close relationship with the reproductive system giving rise to either isolated or combined anomalies. Abnormality in the development of one of the mesonephric ducts with secondary involvement of the ipsilateral paramesonephric duct gives rise to mullerian duct anomalies. At around 5 weeks after conception, the ureteric bud forms from the wolffian duct close to the entry into the cloaca and expands dorsocranially into the metanephric blastema, causing the development of the metanephric nephrons. The kidney on that side will not develop if the ureteric bud does not form or contacts the metanephric blastema. It is possible to detect the Mullerian duct as early as 44 to 48 days after pregnancy. Its cells expand caudally utilising the epithelium as a guide when they come into touch with the wolffian duct. The Mullerian duct is interrupted or fails to develop when the Wolffian duct is disrupted or if it fails to form.⁷ The uterus, fallopian tubes, cervix, and upper 2/3 of the vagina are formed by the paired mullerian

ducts, whereas the lower 1/3 of the vagina is formed by the urogenital sinus. This syndrome’s emergence can be attributed to an embryological arrest that concurrently affected the mullerian and metanephric ducts during the eighth week of gestation.⁸

The most frequently occurring are of renal abnormalities (17.3%), among which 64.6% is contributed by renal agenesis. Renal anomalies were prominently found in patients with didelphic uterus as well (29.1%) with 23.6% of the patients having renal agenesis and obstructed hemivagina. Conditions like renal dysplasia, double collecting system and ectopic ureter were also rarely found.⁸ Other Abnormalities were also present that were associated with the skeletal system (12-19%), cardiovascular system and gastrointestinal malformations (12%).⁹

OHVIRA is a type III anomaly according to the AFS and ESHRE / ESGE classifications.^{10,11} According to the new clinical and embryological classification of female genital tract malformations modified from Acien,1992, OHVIRA belongs to class II.⁹

High level of clinical acumen is required for the early diagnosis of this syndrome and prompt correction of the abnormality to preserve the fertility of female. The modalities available for diagnosis and surgical planning include Ultrasound and MRI. Even though USG can help in diagnosis, MRI is superior to USG in that it aids in better characterization of uterine shape and relationship of adjacent organs with the uterus due to wider field of view and multiplanar images.¹² It also indicates the presence of pyometra / hematosalpinx which are uncommon presentations associated with the syndrome.

The preferred method of treating obstructed hemivagina is resection of the vaginal septum. A limited resection-marsupialization and the insertion of a Foley’s catheter may be carried out during an initial surgical procedure in situations when the obstructed hemivagina reaches the hymeneal ring, enabling the remaining vaginal septum to be removed later. In addition, particularly in young girls, hysteroscopic excision of the septum under transabdominal ultrasound guidance may be performed to preserve hymenal integrity.¹³ Unless tubal disease is suspected, diagnostic laparoscopy is not often advised.

4. Conclusion

Early diagnosis and surgical correction of the hemivagina is essential for preserving the reproductive potential of the patients. With the development of high tech diagnostic tools, such rare syndromes can be diagnosed early and defects can be promptly corrected for the patient to have a normal reproductive life.

5. Source of Funding

None.

6. Conflicts of Interest

The authors declare no conflicts of interest

Acknowledgment


None.

References

- Burgis J. Obstructive Müllerian anomalies: case report, diagnosis, and management. *Am J Obstet Gynecol.* 2001;185(2):338–44.
- Mandava A, Prabhakar RR, Smitha S. OHVIRA syndrome (obstructed hemivagina and ipsilateral renal anomaly) with uterus didelphys, an unusual presentation. *J Pediatr Adolesc Gynecol.* 2012;25(2):23–5.
- Smith NA, Laufer MR. Obstructed hemivagina and ipsilateral renal anomaly (OHVIRA) syndrome: management and follow-up. *Fertil Steril.* 2007;87(4):918–22.
- Purslow CE. A Case of Unilateral Hæmatokolpos, Hæmatometra and Hæmatosalpinx. *Int J Obstet Gynaecol.* 1922;29(4):643.
- Smith NA, Laufer MR. Obstructed hemivagina and ipsilateral renal anomaly (OHVIRA) syndrome: management and follow-up. *Fertil Steril.* 2007;87:918–40.
- The American Fertility Society classifications of adnexal adhesions, distal tubal occlusion, tubal occlusion secondary to tubal ligation, tubal pregnancies, Müllerian anomalies and intrauterine adhesions. *Fertil Steril.* 1988;49(6):944–55.
- Stassart JP, Nagel TC, Prem KA, Phipps WR. Uterus didelphys, obstructed hemivagina, and ipsilateral renal agenesis: the University of Minnesota experience. *Fertil Steril.* 1992;57(4):756–61.
- Jindal G, Kachhawa S, Meena GL, Dhakar G. Uterus didelphys with unilateral obstructed hemivagina with hematometrocolpos and hematosalpinx with ipsilateral renal agenesis. *J Hum Reprod Sci.* 2009;2(2):87–9.
- Sharma R, Mishra P, Seth S, Agarwal N. OHVIRA syndrome—diagnostic dilemmas and review of literature. *J South Asian Fed Obstet Gynaecol.* 2020;12(6):422.
- Grimbizis GF, Gordts S, Sardo ADS. The ESHRE-ESGE consensus on the classification of female genital tract congenital anomalies. *Gynecol Surg.* 2013;10:199–212.
- Ación P, Ación M, Sánchez-Ferrer M. Complex malformations of the female genital tract. New types and revision of classification. *Hum Reprod.* 2004;19(10):2377–84.
- Yilmaz S, Yildiz AE, Fitoz S. Herlyn-Werner-Wunderlich syndrome: sonographic and magnetic resonance (MR) imaging findings of this rare urogenital anomaly. *Pol J Radiol.* 2017;82:216–9.
- Jindal G, Kachhawa S, Meena GL, Dhakar G. Uterus didelphys with unilateral obstructed hemivagina with hematometrocolpos and hematosalpinx with ipsilateral renal agenesis. *J Hum Reprod Sci.* 2009;2(2):87–9.


Author biography

Sujatha M. S, Professor

Sinchana N, Senior Resident  <https://orcid.org/0009-0004-9809-0135>

Prathap Talwar, Associate Professor

Rudresh Hirmath, Professor and HOD

Dheshna N. J, MBBS Student  <https://orcid.org/0009-0002-8091-8788>

Cite this article: Sujatha M. S, Sinchana N, Talwar P, Hirmath R, Dheshna N. J. Ohvira syndrome with rare presentations – A case report. *Indian J Obstet Gynecol Res* 2024;11(1):100-104.