

Content available at: <https://www.ipinnovative.com/open-access-journals>

Indian Journal of Obstetrics and Gynecology Research

Journal homepage: [www.ijogr.org](http://www.ijogr.org)

## Case Series

## Histopathological insights into ovarian tumors: A case series perspective

Archi Arun Chawla<sup>1</sup>, Priyanka Nimbalkar Jadhav<sup>1</sup>, Shilpi Sahu<sup>1</sup>,  
Apeksha Suresh Savale<sup>1\*</sup><sup>1</sup>Dept. of Pathology, MGM Medical College and Hospital, Navi Mumbai, Maharashtra, India

## ARTICLE INFO

## Article history:

Received 05-03-2024

Accepted 12-04-2024

Available online 20-08-2024

## Keywords:

Ovary

Ovarian cancer

Epithelial ovarian cancer

## ABSTRACT

**Background:** Ovarian cancer stands as the third most prevalent cancer among women in India and contributes to 6% of cancer-related fatalities emphasizing its significant impact on mortality. Usually, it manifests with nonspecific symptoms in correlation with age, leading to a frequent oversight in early diagnosis causing more advanced stages when intervention becomes challenging.

**Case Series:** Case records of six patients shed light on the diverse spectrum of ovarian neoplasms encountered in clinical practice, highlighting the complexity and heterogeneity within this disease entity of different age groups. In our case series, we found that the overall burden of ovarian cancer was heaviest in the age group 20–45, while the increase was the largest in the age group 50 years and above.

**Discussion:** Given their asymptomatic nature, late onset of symptoms, and lack of effective screening facilities, ovarian cancers are known as the “silent killer”. Hence, histopathological examination plays a prime role in diagnosis and for primary optimum treatment management. Tumor markers such as AFP, LDH, and beta hCG serve as supplementary tools in the initial diagnostic process, monitoring treatment response, and post-treatment surveillance. Proactive measures targeting diverse risk factors are essential for effective prevention and treatment strategies.

**Conclusion:** This case series underscores the critical importance of timely diagnosis of ovarian tumors, particularly in young females. Heightened vigilance is warranted given the potential for diverse presentations, therefore precise categorization into specific histological types is crucial for clinicians to devise timely management strategies for affected patients.

This is an Open Access (OA) journal, and articles are distributed under the terms of the [Creative Commons Attribution-NonCommercial-ShareAlike 4.0 License](https://creativecommons.org/licenses/by-nc-sa/4.0/), which allows others to remix, tweak, and build upon the work non-commercially, as long as appropriate credit is given and the new creations are licensed under the identical terms.

For reprints contact: [reprint@ipinnovative.com](mailto:reprint@ipinnovative.com)

## 1. Introduction

Ovarian cancer stands as the third most prevalent cancer among women in India and contributes to 6% of cancer-related fatalities. Furthermore, it ranks as the fifth leading cause of death attributable to malignancy in women, emphasizing its significant impact on mortality within the population.

Pathology of the ovary is the most difficult gynecologic disease to evaluate clinically.<sup>1</sup> Typically, ovarian cancer

manifests with nonspecific symptoms in correlation with age, leading to a frequent oversight in early diagnosis. As a result, it is commonly identified in later, more advanced stages when intervention becomes challenging.

The overall outcome of ovarian tumors is influenced by grading, microscopic findings, and final staging. TNM system founded by the American Joint Committee on Cancer and the International Federation of Gynaecology and Obstetrics staging system is used for staging in ovarian malignancies. Microscopic typing and gradation are done by the World Health Organization (WHO) classification. It is important to identify various histological types to predict

\* Corresponding author.

E-mail address: [arcm96@gmail.com](mailto:arcm96@gmail.com) (A. S. Savale).

tumor nature and ascertain treatment protocol as prognosis depends on the degree of differentiation.<sup>2</sup>

This study presents a case series comprising six cases that exhibit diverse clinical presentations. It underscores the significance of gross findings and histopathological examination in accurately staging and promptly treating the condition. Often overlooked, these findings can inadvertently lead to malignant transformations, emphasizing the critical need for thorough examination and timely intervention.

## 2. Case Presentation

### 2.1. Case 1

A 22-year-old nulliparous female presented with a chief complaint of abdominal lump and bloating persisting for 2-3 months, along with breathlessness and severe diffuse pain exacerbated by movement, with radiation to the left side. She reported irregular menses with associated pain, last menstrual period (LMP) on 24/11/23, and occasional brownish vaginal discharge linked to abdominal discomfort. The patient denied any significant past surgical or medical history. On clinical examination, the abdomen was soft and mobile, with a 6 x 4 cm mass palpable in the paraumbilical area, exhibiting regular margins, mild tenderness, and the presence of free fluid.

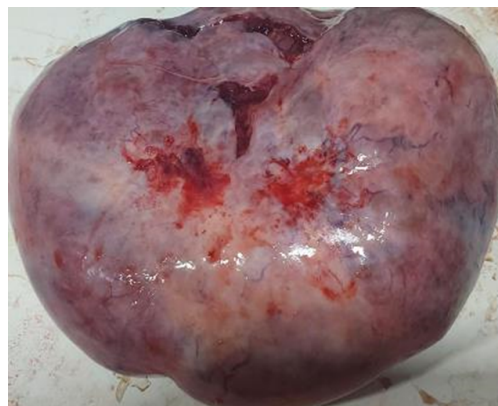The Ultrasonography (USG) showed a hyperechoic lesion originating from the left suprapubic area reaching upto the paraumbilical area likely suggestive of ovarian neoplasm with distorted architecture of left ovary. The patient was advised a CECT for further evaluation. A contrast-enhanced computed tomography (CECT) scan performed on 23/11/23 revealed the presence of a large, well-defined oval complex cystic lesion situated in the pelvic region, extending superiorly into the abdominal cavity along the midline specifically the paraumbilical area. The right ovary appeared normal, and the left ovary was not visualized separately, suggesting the involvement of the left ovary and indicating a probable origin from this structure. The final CECT impression was indicative of an ovarian neoplasm. Additionally, mild ascites and bilateral pleural effusion were also observed on imaging.

Other tests revealed elevated tumor markers: Alpha fetoprotein – 2.44 IU/L (0.5-5.5IU/l), CA 19.9 – 400.06 U/ml (<37 U/ml), CA 125 – 92.7 U/ml (<35 U/ml), CEA – 21.71 ng/ml (<2.5ng/ml). The patient was advised to undergo Left salpingo-oophorectomy surgery and the specimen was sent for Histopathological examination for diagnosis and evaluation.

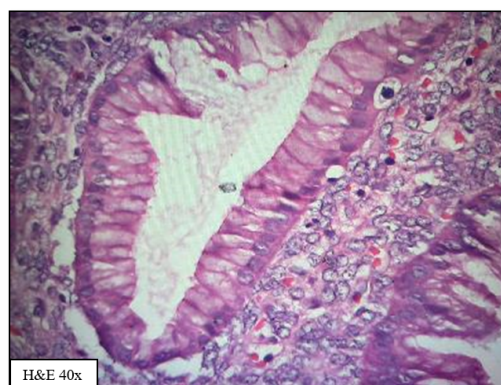
The received specimen from the Left Salpingo-oophorectomy measured 24.5 x 20 x 9.5 cm, with the left fallopian tube measuring 12 cm in length. Macroscopically, the left ovary displayed a smooth, glistening surface with surgical nicks evident (Figure 1). Upon cut opening,

multiple loculated cysts draining mucinous fluid with focal solid areas were observed. Conversely, the left fallopian tube appeared unremarkable, with the lumen identified. The histopathological examination revealed features consistent with a well-differentiated mucinous adenocarcinoma (Figure 2), Grade 1, and staging indicated pT1c1, pNx, pMx. The FIGO stage was classified as Ic1 as the surgical nicks were evident.

The patient had an uneventful postoperative period after which she was referred to higher oncology center where they started her on taxane chemotherapy and has presently completed 2 cycles.



**Figure 1:** Macroscopically, the left ovary displayed a smooth, glistening surface with surgical nicks evident



**Figure 2:** A focus of intramucosal carcinoma in a mucinous cystadenocarcinoma of the ovary. The lining epithelium shows columnar cells also papillary architecture and moderate to severe cytologic atypia (H&E 40x)

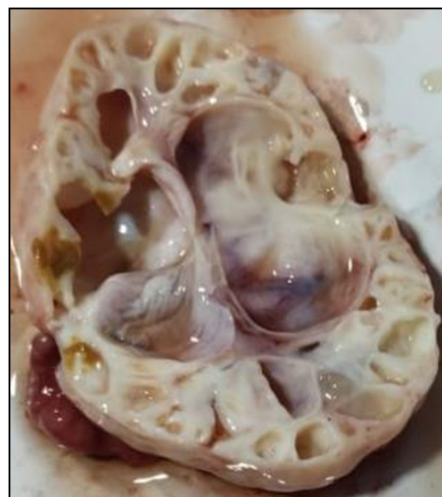
### 2.2. Case 2

A 52-year-old female presented with a 2–3 month history of localized lower abdominal pain on the right side, non-radiating, with no specific exacerbating or alleviating factors noted. She also reported experiencing burning sensations

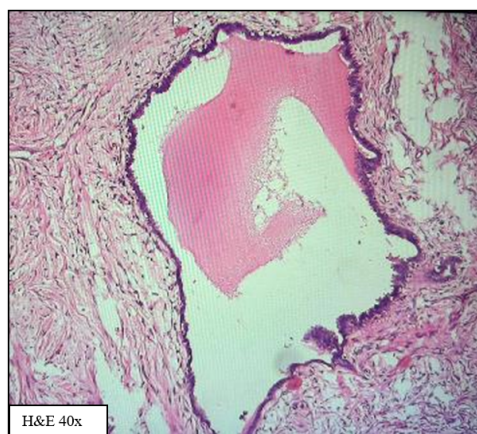during urination intermittently over the past 8 months, with pain intensifying before voiding. There were no associated symptoms of weight loss, changes in appetite, or bowel irregularities. The patient had been post-menopausal for 5 years and had a history of four vaginal deliveries over her 36-year marriage, with tubal ligation performed subsequently. Additionally, she had a medical history significant for a previous diagnosis of carcinoma of the right breast, for which she underwent a right modified radical mastectomy surgery along with chemotherapy and 3 cycles of radiotherapy in 2012- 2013. The patient was scheduled for full body scans as a yearly follow-up where Imaging studies, including USG, PET-CT and CT abdomen pelvis were performed. The Ultrasonography revealed a multilobulated, cystic hyperechoic lesion separated by a few septae in the right adnexa suggestive of ovarian cystadenofibroma. On further investigation the PET-CT was performed which revealed a lobulated complex cystic lesion in the right adnexa with no metabolic activity, suggestive of a neoplastic origin of the ovary. Increased metabolic activity was also noted in a few right axillary and internal mammary lymph nodes, raising suspicion for metastasis. Furthermore, a uterine polyp was identified. A CT imaging of the abdomen and pelvis was also performed which additionally identified a mildly enhancing complex mass in the right adnexa, characterized by cystic areas surrounded by mildly enhancing solid components and septae, prompting consideration of a Krukenberg tumor along with a posterior subserosal fibroid observed in the fundus of the uterus.

Other tests performed are Alpha fetoprotein – 4.64 IU/L (0.5-5.5IU/L), CA 19.9 – 40.06 U/ml (<37 U/ml) which was mildly raised, CA 125 – 12.9 U/ml (<35 U/ml) and CEA – 1.71 ng/ml (<2.5ng/ml). The patient was planned for a Frozen section for oophorectomy surgery followed by salpingectomy.

The histopathology department received a single grey-white to grey-brown multiloculated, soft to-firm tissue piece measuring 8 cm x 6 cm x 2 cm comprising of solid and cystic areas on the cut surface with serous fluid oozing out (Figure 3). The frozen section analysis performed on 21/12/23 indicated histomorphological features suggestive of a surface epithelial tumor of the ovary, with final confirmation provided by examination of paraffin sections only. Subsequent histopathological examination revealed histomorphological features consistent with a diagnosis of serous cystadenofibroma of the ovary (Figure 4). The absence of metastatic characteristics confirms the lesion as benign. In the post-operative period of the patient, 2 units of PRBC were transfused and was kept on antibiotics and analgesics. She was discharged uneventfully on postoperative day 10 and is currently stable and put on a 3-month follow-up.



**Figure 3:** Left ovary comprising of multiple cysts filled with clear fluid and smooth inner surface



**Figure 4:** Serous cystadenomas of the ovary are thin-walled unilocular cysts that are lined by ciliated pseudostratified cuboidal or columnar epithelium (resembling that lining the fallopian tube)

### 2.3. Case 3

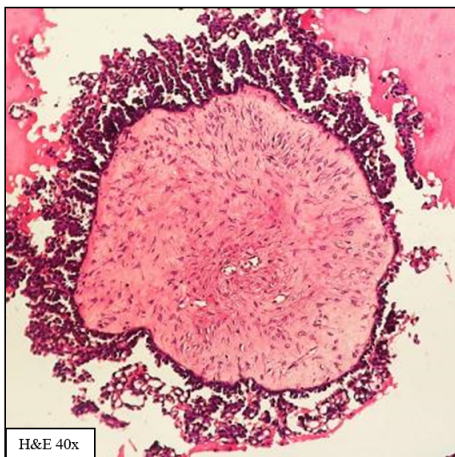
A 65-year-old female presented with a chief complaint of right-sided abdominal pain persisting for 2 months, described as dull and non-radiating, without associated loss of appetite. She had a history of hysterectomy performed 13 years prior and had been married for 30 years with a past obstetric history of three pregnancies and two vaginal deliveries. Her medical history was unremarkable for hypertension, tuberculosis, diabetes mellitus, thyroid disorders, or epilepsy. Ultrasonography examination of the abdomen and pelvis revealed a thick-walled cystic lesion with internal solid papillary projection greater than 3 cm, measuring 4.3 x 3.5 cm in the right adnexa, likely comprising the ureter, further suggestive of cystadenoma.

Additionally, the MRI of the pelvis was performed and showed a thin-walled, peripheral enhancing cystic lesion in the right adnexa, with MRI characteristics suggestive of a benign etiology of the ovary such as ovarian cystadenoma. A CT abdomen-pelvis was also advised that demonstrated a well-defined, mildly heterogeneous enhancing solid lesion in the right adnexa, consistent with a benign ovarian neoplastic etiology with metabolic activity.

Other tests such as Alpha-fetoprotein was 6.84 IU/L (0.5-5.5IU/L), CA 19.9 was 50.06 U/ml (<37 U/ml), CA 125 was 22.7 U/ml (<35 U/ml) and CEA was 0.51 ng/ml (<2.5ng/ml).

Considering the age of the patient along with raised AFP and CA19.9 the patient was posted for a Frozen section for a laparoscopic unilateral salphingo-oophorectomy followed by Hysterectomy which was sent for routine Histopathological diagnosis.

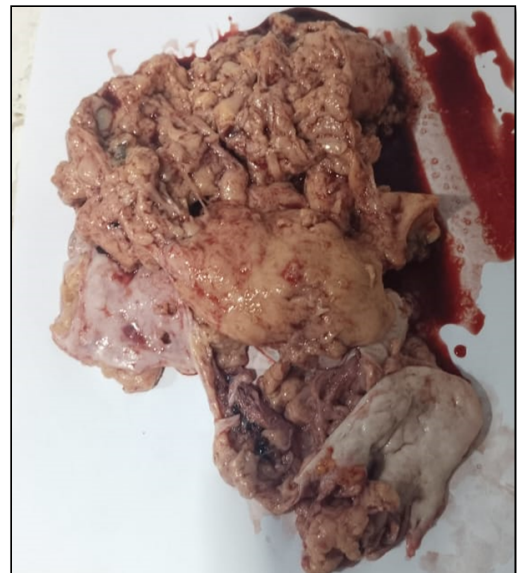During Frozen we received a single, grey-white to grey-brown soft to firm tissue piece measuring 5 x 4.5 x 1.2 cm with a cut surface comprising of solid and cystic areas along with an attached fallopian tube measuring 1.8 cm in length. The frozen section analysis indicated histomorphological features suggestive of a serous cystadenoma, with final confirmation provided upon examination of paraffin sections. However, upon examination of the paraffin sections, the findings were suggestive of a borderline serous ovarian tumor which underscores the importance of histopathological examination in borderline lesions which if not diagnosed on time can transform into malignant. (Figure 5) The patient was discharged uneventfully and was advised for a follow-up in the next 6 months along with a PET CT scan.



**Figure 5:** The papillary structures show a hierarchical branching pattern from large to progressively smaller papillae ultimately leading to smaller detached tufts of epithelial cells in cleft-like spaces. The papillae are lined by ciliated pseudostratified cuboidal or columnar epithelium. (H&E 40 x)

#### 2.4. Case 4

A 30-year-old woman presented with a chief complaint of persistent suprapubic intraabdominal swelling lasting for 8 months, accompanied by burning during urination and mild tenderness. She also reported a history of decreased appetite, along with episodes of nausea and vomiting. Her menstrual history revealed irregular heavy periods with clot passage, with the last menstrual period noted on 10/12/23. In terms of obstetric history, she had been married for 20 years and had experienced two pregnancies, two live births, and two abortions, all delivered vaginally, with tubal ligation performed 8 years prior. There were no notable medical conditions or comorbidities in her past medical history.



**Figure 6:** Macroscopically the Adult granulosa cell tumor (GCT) of the ovary is unilateral (>95% of cases), smooth, lobulated tumor with a predominantly solid or solid and cystic, yellow to tan-white cut surface

Ultrasonography was performed revealing an enlarged hypoechoic enhancing lesion measuring 12 x 11 x 10 cm with irregular architecture in the left adnexa suggestive of benign etiology, followed by a CT scan on 11/11/23 that revealed a large lobulated, multi-loculated solid cystic lesion measuring 10.5 x 11.2 x 11.7 cm in the lower abdomen and pelvis, likely originating from the left ovary, suggestive of a serous or mucinous cystadenoma with a suspected neoplastic origin. A subsequent ultrasound scan was performed from a different medical institute that indicated a large, mixed, solid, and cystic multiloculated lesion measuring 11.6 x 10.8 x 8.6 cm in the left adnexa, also suggestive of a neoplastic origin. With contrasting reports the patient was posted for Left laparoscopic Salphingo-oophorectomy for a frozen section. Additional tests, including alpha-fetoprotein, CA 19.9, CA 125, and

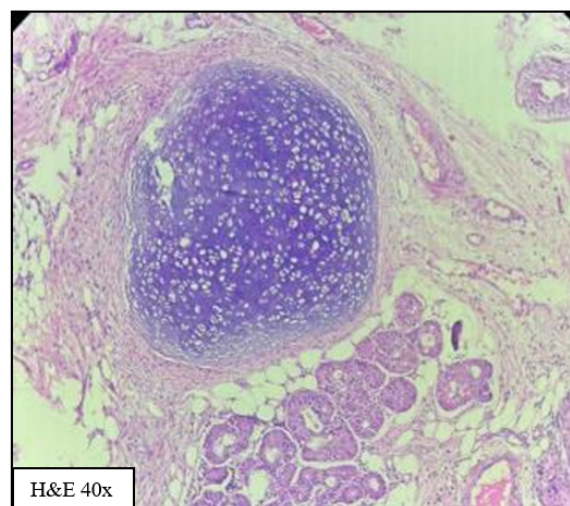
CEA, were within normal ranges. The histopathology section received a specimen of the left ovarian cyst with the fallopian tube, along with the yellow, tan brown fatty contents of the ovarian cyst, measured 22 x 20 x 4 cm, with an attached fallopian tube measuring 3.5 cm in length. Grossly the specimen was extremely different to the radiological descriptions given. Further evaluation via frozen section analysis suggested histomorphological features consistent with a Sex Cord Stromal Tumor, ultimately confirmed as a Granulosa cell Tumor, Adult type, staged as pT1pNxpMx according to pTNM staging criteria, and FIGO Stage 1 upon examination of paraffin sections. The patient was transfused 4 PRBC blood, along with discharge uneventful discharge on post-operative day 16. After a month she was started on additional chemotherapy as advised by oncologist, and is still under follow-up.

### 2.5. Case 5

A 37-year-old woman presents with abrupt and intense pain in her right abdomen, which extends to the left flank. Notably, she experiences no bowel or bladder issues, fever, vomiting, or vaginal bleeding, and has no significant medical or surgical history. During examination, a palpable lump measuring 7 x 7 cm is detected in the right iliac and umbilical regions. Further investigations, including tests for alpha fetoprotein, CA 19.9, CA 125, and CEA, yield values within normal ranges. Ultrasonography was not performed however the patient had done a CT scan of the abdomen and pelvis that revealed a well-defined, smooth-marginated, predominantly cystic mass measuring 14.1 x 12.2 x 11.2 cm originating from the left adnexa, suggestive of a probable left mature cystic adnexal teratoma (dermoid cyst) with involvement of surrounding structures. Upon macroscopic examination, the ovary displays a single fluid-filled cyst with a greyish-white appearance, measuring 13 x 13 x 9 cm. The exterior surface appears tense, and upon incision, approximately 300 ml of pale yellowish serous fluid is observed to exude, with the presence of multiple hairs and pultaceous material (Figure 7). The patient was posted for a radical hysterectomy with bilateral salpingo-oophorectomy. Histomorphological analysis confirmed the diagnosis of a Dermoid cyst and its contents were visualised in microscopic examination comprising of cartilage, bone and skin adnexa. The patient was discharged uneventfully on post-operative day 3 along with antibiotics and analgesics.

### 2.6. Case 6

A 38-year-old female presented with lower abdominal pain and a three-month history of a gradually enlarging mass in February 2020. She reported no associated menstrual, bladder, or bowel issues. Upon abdominal examination, a cystic mass measuring 15.0 cm by 20.0 cm was palpated, corresponding to a uterus size of 30 weeks. The mass was



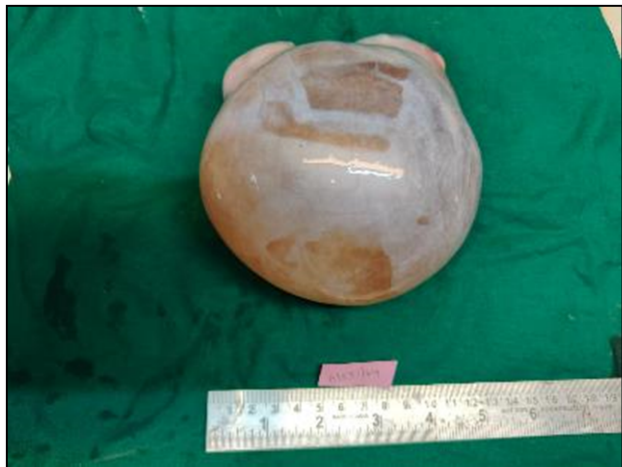**Figure 7:** Microscopy showing cartilage, hair follicle and sebaceous glands in the stroma which is lined by stratified squamous epithelium (H&E 40 x)

mobile and non-tender. Vaginal examination revealed the same mass in the anterior fornix, mobile in all directions and non-tender, with a consistency ranging from cystic to firm.

The uterus appeared anteverted and normal in size, with bilateral vaginal fornices being free. Ultrasonography demonstrated an anechoic cyst in the right adnexa measuring 10.2 cm x 10.0 x 10.7 cm, showing internal echoes and septations, while the left ovary, adnexa, and uterus appeared normal suggestive of seromucinous cystic ovarian lesion. A CT scan was done considering the size of the mass which confirmed a well-defined unilocular cystic lesion measuring 9.7 x 13.5 cm x 15.2 cm, originating from the right adnexa with thick internal septations and an eccentric solid enhancing nodule maintaining fat planes with adjacent bowel loops, with no locoregional lymphadenopathy observed. The right ovary was not separately visualized highly suggestive of mucinous cystadenoma/cystadenocarcinoma. Tumor marker analysis revealed slightly elevated CA 125 levels (70.5 IU/ml), while CEA (2.4 ng/ml), CA 19–9 (2.0 U/ml), LDH (687.4 U/L), beta hCG (0.18 mIU/ml), and AFP (2.04 ng/ml) were within normal ranges. The patient was posted for right salpingo-oophorectomy surgery considering the enlarging size and elevated CA125 levels.

The received specimen from the Left Salpingo-oophorectomy measured 15.5 x 16 x 9.5 cm, with the left fallopian tube measuring 10 cm in length. Macroscopically, the left ovary displayed a smooth surface. Upon cut opening, multiple loculated cysts draining mucinous and serous fluid with focal solid areas were observed (Figure 8). Conversely, the right fallopian tube appeared unremarkable, with the lumen identified. Histopathological examination

revealed histomorphological features consistent with a well-differentiated mucinous cystadenocarcinoma, Grade 1. The patient was discharged uneventfully on post-operative day 9 and referred to higher oncology center where she was started on platinum chemotherapy and has currently undergone 5 cycles with last one in process.



**Figure 8:** Left ovarian cyst having smooth surface, with glistening capsule comprising of serous and mucinous fluid

### 3. Discussion

Our case series sheds light on the diverse spectrum of ovarian neoplasms encountered in clinical practice, highlighting the complexity and heterogeneity within this disease entity.

Ovarian tumors are not uncommon neoplasms in women. The histopathological spectrum of ovarian neoplasms exhibits a wide range of variations.<sup>3</sup> Ovarian neoplasms are considered notorious and are challenging to diagnose early due to their subtle and nonspecific symptoms, often leading to detection at advanced stages. The main risk factors for ovarian

tumours are nulliparity, familial predisposition of diagnosed ovarian cancer, advanced childbearing age and high-income group.<sup>4</sup> Due to lack of effective screening facilities, ovarian cancers are known as the “silent killer”.<sup>5,6</sup> Thoroughly inspecting and sampling during the gross examination is vital. In addition to recording dimensions and weight, it’s essential to note whether the capsule is breached or intact. Ovarian cysts can inadvertently rupture during surgery, potentially leaving pathologists without immediate access to surgical notes. Therefore, documenting the status of the capsule upon receipt is crucial. If a carcinomatous cyst or tumor has experienced a rupture before or during surgery, the disease stage is at least considered stage I C. Ovarian tumors were systematically classified based on the WHO classification

into distinct categories, including Surface Epithelial Tumors (SETs), Sex Cord-Stromal Tumors (SSTs), Germ Cell Tumors (GCTs), and metastatic tumors. Further delineation revealed that SETs encompassed a spectrum of serous, mucinous, endometrioid, clear cell, seromucinous, and Brenner tumors, each categorized into benign, borderline, and malignant subtypes. GCTs included mature cystic teratoma, immature teratoma, dysgerminoma, yolk sac tumor, embryonal carcinoma, choriocarcinoma, mixed germ cell tumors, monodermal teratomas (struma ovarii and strumal carcinoid), and gonadoblastoma. Lastly, SSTs comprised fibroma, thecoma, juvenile granulosa cell tumor, adult granulosa cell tumor, and Sertoli-Leydig cell tumor, representing a diverse array of ovarian neoplasms with unique histological and clinical characteristics.

The histological type of ovarian neoplasm correlates with prognosis as well. Due to the similar clinical and radiological finding, diagnosis of ovarian neoplasm can be difficult. Hence, histopathological examination plays a prime role in diagnosis and for primary optimum treatment management.<sup>7</sup>

In our case series, we found that the overall burden of ovarian cancer was heaviest in the age group 20–45 having asymptomatic presentation, while the increase was the largest in the age group 50+, which was similar to the conclusion of previous studies. It was also concluded that tumour laterality is an independent factor with right adnexa being involved more commonly than left side. Micci et al.<sup>8</sup> and Pejovic et al.<sup>9</sup> were the first to put forward the question to the origin of bilaterality in case of ovarian malignancies. They wanted to investigate whether ovarian malignancies manifest as distinct primary tumors or as secondary deposits originating from other primary ovarian malignancies. Following cytogenetic testing, it was observed that most bilateral tumors exhibited nearly identical karyotyping patterns, suggesting a metastatic origin. However, pinpointing the primary tumor remained challenging. Features indicative of metastatic tumors included peritoneal surface deposits, ascitic fluid positive for malignant cells, and variations in tumor dimensions. Conventionally, larger tumors are deemed primary, while smaller ones are considered secondary deposits due to their shorter development timeframe. Nevertheless, the study’s scope was limited by the absence of monoclonality analysis in cytogenetic testing. Future research endeavors could explore this aspect further.

The majority of tumours were cystic with few being partly solid and cystic with focal solid areas. The size range of ovarian tumours in our study ranged from 3 cm to 24.5 cm with the largest ovarian tumor being mucinous adenocarcinoma. Irrespective of the nature of the ovarian neoplasm, abdominal lump, and pain were the common presenting complaints. Similar findings were seen in other studies by other authors.<sup>10,11</sup> However, weight loss and

ascites were frequently associated with malignant tumors. Similar observations were also observed in other studies.<sup>12</sup>

Tumor markers such as AFP, LDH, and beta hCG serve as supplementary tools in the initial diagnostic process, monitoring treatment response, and post-treatment surveillance. Royal College of Obstetrician and Gynaecology (RCOG) green top guideline and The National Academy of Clinical Biochemistry warrant measurement of AFP, LDH and hCG levels in women presenting with an ovarian mass (Age <40 years)<sup>13</sup> and also in older women with scan suggestive of germ cell tumor.<sup>14</sup> Mazumdar et al.<sup>15</sup> suggest that elevated AFP (>10,000 ng/ml) and  $\beta$ HCG (>50,000 mIU/ml) correlate with advanced-stage disease and reduced survival (5-year survival rate <50%), which is independent of the stage.

Simultaneously, elevated fasting plasma glucose and high body mass index are also emerging as the most significant contributors to the heightened burden of ovarian cancer. Notably, the burden associated with this risk factor exhibited considerable variation. Hence, this research underscores the importance of developing and implementing tailored policies and prevention strategies responsive to local contexts. Proactive measures targeting diverse risk factors are essential for effective prevention and treatment strategies against ovarian cancer.<sup>16</sup>

#### 4. Conclusion

In conclusion, this case series underscores the critical importance of timely diagnosis in ovarian tumors, particularly in young females. Heightened vigilance is warranted given the potential for diverse presentations and the significance of considering laterality and bilateral involvement. Histopathological examination remains the gold standard playing a pivotal role in diagnosis for prognosis and primary optimum treatment management. Conduction of a frozen section followed by histopathological examination plays a crucial role in the surgical management of ovarian carcinomas and should be considered as a definitive protocol it helps in providing rapid pathological information to guide surgical decision-making, ensure optimal tumor removal based on histological subtype and disease stage.

Given the high mortality rates and poor prognosis associated with malignant ovarian tumors, precise categorization into specific histological types is crucial for clinicians to devise timely management strategies for affected patients. While significant advancements have been achieved in comprehending ovarian neoplasms in recent decades, further research is imperative to deepen our understanding of their origins, underlying mechanisms, and the potential impact of cytogenetic analysis. Such insights have the potential to revolutionize early diagnosis and management paradigms, ultimately enhancing the quality of life for all women vulnerable to ovarian neoplasms.

#### 5. Declaration of Patient Consent

The authors confirm that they have obtained appropriate consent from the patient(s) involved. The patient(s) have provided consent for the publication of their images and other clinical information in the journal. The patient(s) understand that their names and initials will not be published, and reasonable efforts will be made to ensure their anonymity. However, it is acknowledged that anonymity cannot be guaranteed.

#### 6. Sources of Funding

None.

#### 7. Conflicts of Interest

Nil.

#### Acknowledgements

Nil.

#### References

- Laloudek C, Silverberg SG. The ovary. In: Pathology in Gynecology and Obstetrics. Philadelphia: Lippincott J.E. Co; 1994. p. 313–413.
- Chakrabarti PR, Chattopadhyay M, Gon S, Banik T. Role of histopathology in diagnosis of ovarian neoplasms: Our experience in a Tertiary Care Hospital of Kolkata, West Bengal, India. *Niger Postgrad Med J.* 2021;28(2):108–11.
- Sen U, Sankarnarayanan R, Mandal S, Roman AV, Parkin DM, Siddique M. Cancer patterns in eastern India: the first report of the Kolkata cancer registry. *Int J Cancer.* 2002;100(1):86–91.
- Nair RV, Sughija G. Histopathological study of ovarian tumors in a tertiary care center. *Obs Gyne Review J Obstet Gynecol.* 2020;6(1):22–7.
- Momenimovahed Z, Tiznobaik A, Taheri S, Salehiniya H. Ovarian cancer in the world: epidemiology and risk factors. *Int J Womens Health.* 2019;11:287–99.
- Yoneda A, Lendorf ME, Couchman JR, Mulhaupt HAB. Breast and ovarian cancers: a survey and possible roles for the cell surface heparan sulfate proteoglycans. *J Histochem Cytochem.* 2012;60(1):9–21.
- Salem FM, Alarabawy RA, El-Ebiary MT, Edorf AA, Abozeid SM. Imaging modalities in the differentiation of various adnexal lesions. *Tanta Med J.* 2016;44:39–52.
- Micci F, Haugom L, Ahlquist T, Abeler VM, Trope CG, Lothe RA, et al. Tumor spreading to the contralateral ovary in bilateral ovarian carcinoma is a late event in clonal evolution. *J Oncol.* 2010;2010:646340. doi:10.1155/2010/646340.
- Pejovic T, Heim S, Mandahl N, Elmfors B, Furgyik S, Flodérus UM, et al. Bilateral ovarian carcinoma: Cytogenetic evidence of unicentric origin. *Int J Cancer.* 1991;47(3):358–61.
- Chandanwale SS, Jadhav R, Rao R, Naragude P, Bhamnikar S, Ansari JN. Clinicopathologic study of malignant ovarian tumors: A study of fifty cases. *Med J DY Patil Univ.* 2017;10:430–7.
- Goff BA, Mandel LS, Melancon CH, Muntz HG. Frequency of symptoms of ovarian cancer in women presenting to primary care clinics. *JAMA.* 2004;291(22):2705–12.
- Pilli GS, Suneeta KP, Dhaded AV, Yenni V. Ovarian tumours: a study of 282 cases. *J Indian Med Assoc.* 2002;100(7):420–47.
- Management of suspected ovarian masses in premenopausal women: Green-top Guideline No. 62. Royal College of Obstetricians and

Gynaecologists; 2011. Available from: [https://www.rcog.org.uk/media/0mebp0mv/gtg\\_62.pdf](https://www.rcog.org.uk/media/0mebp0mv/gtg_62.pdf).

14. Sturgeon CM, Duffy MJ, Stenman UH, Lilja H, Br nner N, Chan DW, et al. National Academy of Clinical Biochemistry laboratory medicine practice guidelines for use of tumor markers in testicular, prostate, colorectal, breast, and ovarian cancers. *Clin Chem*. 2008;54(12):11–79.
15. Mazumdar M, Bajorin DF, Bacik J, Higgins G, Motzer RJ, Bosl GJ. Predicting outcome to chemotherapy in patients with germ cell tumors: the value of the rate of decline of human chorionic gonadotrophin and alpha-fetoprotein during therapy. *J Clin Oncol*. 2001;19(9):2534–41.
16. Mei S, Chelmow D, GeCSI K, Barkley J, Barrows E, Brooks R, et al. Health Disparities in Ovarian Cancer: Report From the Ovarian Cancer Evidence Review Conference. *Obstet Gynecol*. 2023;142(1):196–210.

## Author biography

**Archi Arun Chawla**, Junior Resident

**Priyanka Nimbalkar Jadhav**, Associate Professor

**Shilpi Sahu**, Professor and Head

**Apeksha Suresh Savale**, Senior Resident

**Cite this article:** Chawla AA, Jadhav PN, Sahu S, Savale AS. Histopathological insights into ovarian tumors: A case series perspective. *Indian J Obstet Gynecol Res* 2024;11(3):496-503.