

Content available at: <https://www.ipinnovative.com/open-access-journals>

Indian Journal of Obstetrics and Gynecology Research

Journal homepage: [www.ijogr.org](http://www.ijogr.org)

## Case Report

# Colposcopic features of HPV associated adenocarcinoma usual type

Priyanka Singh <sup>1</sup>\*

<sup>1</sup>Dept. of Gynecological Oncology, Kalyan Singh Super Specialty Cancer Institute, Lucknow, Uttar Pradesh, India



### ARTICLE INFO

#### Article history:

Received 25-12-2023

Accepted 18-06-2024

Available online 20-08-2024

#### Keywords:

Adenocarcinoma

Cervical cancer

Colposcopy

### ABSTRACT

Adenocarcinoma in situ of cervix is less frequently detected, especially when not associated with squamous intraepithelial premalignant lesion. The relative incidence of in-situ or invasive adenocarcinoma is likely to rise with propensity for younger population. Incidence of recurrence is also higher when histopathology is adenocarcinoma in comparison to the squamous histopathology, This necessitates establishment of different risk factors that would guide the modality of treatment to be taken up in adenocarcinoma histopathology. (Yuksel) Diagnosis of glandular lesions on colposcopy is difficult owing to distinct and less common features, difficulty to approach and fewer cases therefore lesser experience with colposcopy plus the coincidence of squamous lesions along with glandular lesions being more common, adds to the conundrum. In the current image-based case study, colposcopy features of glandular abnormalities in adenocarcinoma of cervix have been described.

This is an Open Access (OA) journal, and articles are distributed under the terms of the [Creative Commons Attribution-NonCommercial-ShareAlike 4.0 License](https://creativecommons.org/licenses/by-nc-sa/4.0/), which allows others to remix, tweak, and build upon the work non-commercially, as long as appropriate credit is given and the new creations are licensed under the identical terms.

For reprints contact: [reprint@ipinnovative.com](mailto:reprint@ipinnovative.com)

## 1. Introduction

The early detection and treatment of carcinoma cervix uteri is often the aim of screening programs but most patients in the low middle income countries (LMICs) reach cancer care facilities at an advanced stage in the absence of systematic screening, poor awareness and lack of appropriate diagnostic and treatment facility.<sup>1</sup> The early detection and diagnosis are possible by training doctors in simple yet effective procedures like colposcopy and biopsy which may prove to be very useful in ascertaining type, size and extent of disease on the cervix.<sup>1</sup> Adenocarcinoma in-situ (AIS) of cervix is less frequently detected, especially when not associated with squamous intraepithelial premalignant lesion. The relative incidence of invasive adenocarcinoma is 20-25 percent with higher incidence in younger population while that of atypical glandular cells on cytology is just 0.2 percent. Incidence of

recurrence is also higher in adenocarcinoma in comparison to the squamous histopathology, thereby necessitating establishment of different risk factors that would guide the modality of treatment to be taken up in adenocarcinomas.<sup>2-4</sup> Retrospective studies assessing recurrence and survival in cervical adenocarcinomas, describe tumor size, lymphovascular space invasion (LVSI) and uterine extension as significant prognostic factors in surgically treated patients.<sup>4,5</sup> The WHO classifies premalignant endocervical glandular lesions as endocervical glandular dysplasia (EGD) (also known as atypical hyperplasia) and AIS, while in the UK the term cervical glandular intraepithelial neoplasia (CGIN) is more common and is further subclassified into low grade CGIN and high grade CGIN that correspond to EGD and AIS respectively.<sup>6</sup> Further the usual type adenocarcinomas are categorized as HPV associated and unassociated, with the former having a better prognosis. The Silva pattern of glandular invasion, and its effectiveness in predicting prognosis of the disease has been further studied leading to development of the international

\* Corresponding author.

E-mail address: [dpriyankaci@gmail.com](mailto:dpriyankaci@gmail.com) (P. Singh).

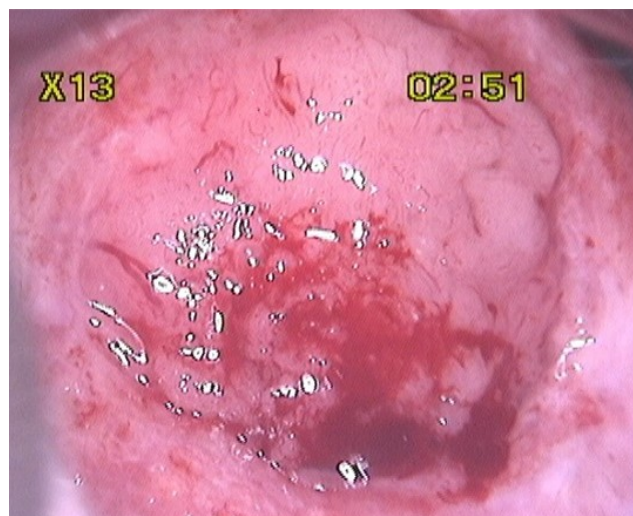
endocervical adenocarcinoma classification criteria (IECC), where the glandular invasion has been classified into three prognostic categories that are the equivalent of depth of invasion for glandular adenocarcinoma in the absence of the typical basement membrane of the squamous epithelium.<sup>7-9</sup> Diagnosis of glandular lesions on colposcopy is difficult owing to distinct and rare features and difficult approach or visualization during colposcopy along with frequently coinciding squamous lesions with adenocarcinoma adding to the conundrum. In the current image-based case study, colposcopy features of glandular abnormalities in adenocarcinoma of cervix have been described to provide pictorial evidence that may be useful in diagnosing similarly presenting cases.

## 2. Case Report

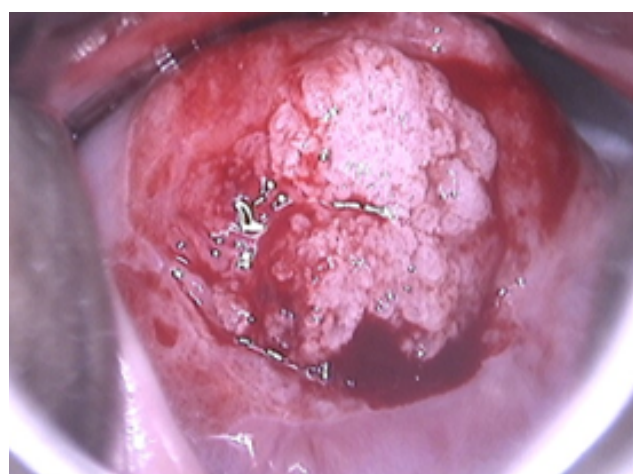
The patient, a 45 years old lady presented with intermenstrual bleeding with HPV 16 positive on screening. The patient underwent clinical assessment by the gynecological oncologist and a colposcopic examination revealed a large ectropion like lesion on the columnar epithelium with clumping of columnar papillae, on the anterior cervix, the squamocolumnar junction was well defined and was type 1 as per the International Federation Cervical Pathology & Colposcopy (IFCPC) classification. Vascular patterns like character writing like vessels with abrupt appearance and disappearance, truncation and fine tendrillar appearance in some places, were seen (Figures 1 and 2). On application of acetic acid there was a dense acetowhite area overlying the columnar epithelium only, with no extension onto the squamous epithelium, it had rapid appearance after application of acetic acid and persisted for more than a minute. (Figures 3 and 4) It was classified as high- grade changes and a Swede score of 8 was assigned. Colposcopy directed biopsy was taken and the histopathology was adenocarcinoma, usual type. The patient underwent type 2 radical hysterectomy and histopathology reported type b Silva pattern of invasion with tumour size of 3.5 cms, with no lymph node involved. Thus, adjuvant radiation was given considering intermediate risk factors. The patient is completely disease free at one year of follow-up and was also given hormone replacement therapy.

## 3. Discussion

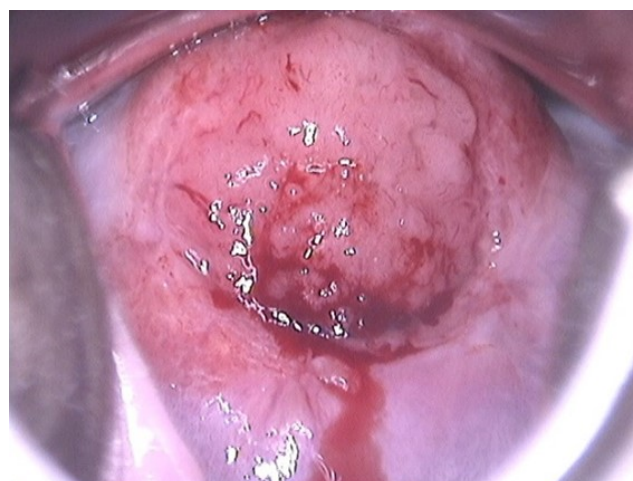
There are three types of colposcopy presentations described for adenocarcinoma in-situ or adenocarcinoma that is, irregular papillary appearance resembling an immature transformation zone, a flat variegated reddish white area resembling an immature transformation zone or the least common, isolated, individual, elevated densely acetowhite area overlying the columnar epithelium with no association with the squamous epithelium, which was demonstrated



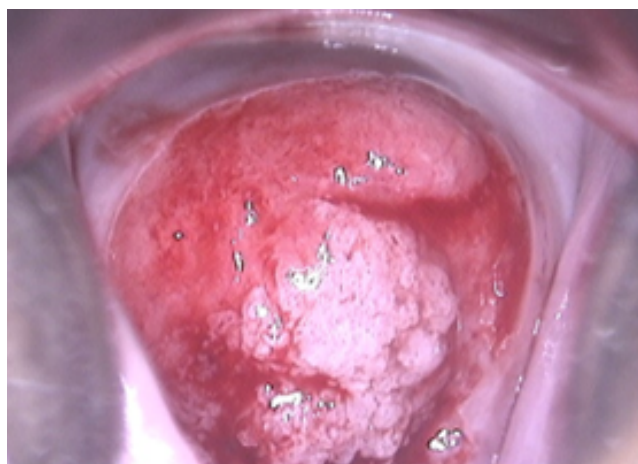
**Figure 1:**



**Figure 2:**



**Figure 3:**



**Figure 4:**

in the present case.<sup>6,9</sup> AIS or adenocarcinoma maybe ectocervical in 53 percent cases, completely endocervical in 5 percent and having both ecto-endocervical components in 38 percent cases, therefore more than 90 percent of the adenocarcinoma in-situ are amenable to visualization and colposcopic assessment.<sup>6</sup> The vascular changes distinct to glandular lesions have been described by specialists like Write VC as ‘waste-thread-like vessels; tendril-like vessels; rootlike vessels; character-writing-like vessels; and single and multiple dotlike formations in tips of papillary excrescences.’ In this case the vascular changes are typically that seen in invasive disease with abruptly appearing and disappearing vessels, loss of branching and truncation, parallel vessels (railroad sign), with thickened caliber, few tendrillar vessels & Chinese characters writing like appearance.

Screening tests like Visual Inspection with Acetic acid (VIA) and cytology are not considered sensitive for detection of glandular neoplasia.<sup>6,9</sup> Therefore, AIS and adenocarcinoma may be detected late as there is a possibility of being missed during routine screening by cytology or VIA. The HPV testing on the other hand would be useful in detecting HPV associated AIS/adenocarcinoma when not suspected on visual examination or cytology. On colposcopy there is possibility of being confused with immature metaplasia or cervical ectopy owing to the location of the lesions which may be close to the squamocolumnar epithelium or red and flat.<sup>10</sup> The spectrum of glandular neoplasia from cervical intraepithelial glandular neoplasia to adenocarcinoma in situ and invasive adenocarcinoma are rare histopathological entities and have distinct epidemiological, clinical and prognostic features.<sup>8,9,11–13</sup> The histopathological criteria and risk classification as per the Silva pattern can be best described in the large operated specimens of conization, large loop excision of transformation zone (LLETZ) or hysterectomy and can predict risk of recurrence and metastasis. The non-HPV

associated adenocarcinomas as classified into glandular, mucinous, clear cell or endometrioid do not have a good prognosis, are often detected late and may have mesonephric origin or are an extension from the uterus or ovaries.<sup>8</sup> These are not amenable to screening and prevention by routine methods while the epidemiology is also different from the HPV associated carcinomas. Early detection is not possible with routine screening and such patients may be treated surgically. The knowledge and practice of colposcopy can improve early diagnosis and treatment decision-making.

#### 4. Conclusion

Colposcopy must be done in patients undergoing screening for cervical cancer as it is a useful diagnostic tool and aid in treatment decision-making. Cervical glandular neoplasia is less common with characteristic features which require careful consideration and practice of colposcopy and guided procedures to diagnosis and treatment.

#### 5. Sources of Funding

None.

#### 6. Conflict of Interest

None.

#### References

1. World Cancer Report: Cancer Research for Cancer Prevention. Lyon, France: International Agency for Research on Cancer; 2020.
2. Roma AA, Mistretta TA, Vivar ADD, Park K, Alvarado-Cabrero I, Rasty G, et al. New pattern-based personalized risk stratification system for endocervical adenocarcinoma with important clinical implications and surgical outcome. *Gynecol Oncol.* 2016;141(1):36–42.
3. Yüksel D, Çakır C, Kılıç F, Ünsal M, Kılıç Ç, Cömert GK, et al. Oncologic outcomes of patients with FIGO 2014 stage IB-IIA cervical adenocarcinoma who underwent radical surgery. *Arch Gynecol Obstet.* 2022;306(5):1657–64.
4. Parazzini F, Vecchia CL. Epidemiology of adenocarcinoma of the cervix. *Gynecol Oncol.* 1990;39(1):40–6.
5. Singh P, Tripcony L, Nicklin J. Analysis of Prognostic Variables, Development of Predictive Models, and Stratification of Risk Groups in Surgically Treated FIGO Early-Stage (IA–IIA) Carcinoma Cervix. *Int J Gynecol Cancer.* 2012;22:115–22.
6. Mccluggage WG. Endocervical glandular lesions: controversial aspects and ancillary techniques. *J Clin Pathol.* 2003;56(3):164–73.
7. Roma AA, Vivar ADD, Park KJ, Alvarado-Cabrero I, Rasty G, Chanona-Vilchis JG, et al. Invasive endocervical adenocarcinoma: a new pattern-based classification system with important clinical significance. *Am J Surg Pathol.* 2015;39(5):667–72.
8. Park KJ. Cervical adenocarcinoma: integration of HPV status, pattern of invasion, morphology and molecular markers into classification. *Histopathology.* 2020;76(1):112–27.
9. Hodgson A, Olkhov-Mitsel E, Howitt BE, Nucci MR, Parra-Herran C. International Endocervical Adenocarcinoma Criteria and Classification (IECC): correlation with adverse clinicopathological features and patient outcome. *J Clin Pathol.* 2019;72(5):347–53.
10. Mcgee AE, Alibegashvili T, Elfegren K, Frey B, Grigore M, Heinonen A, et al. European Federation for Colposcopy and Pathology

of the Lower Genital Tract (EFC) and the European Society of Gynaecological Oncology (ESGO). *Eur J Obstet Gynecol Reprod Biol.* 2023;290:27–37.

11. Wright VC. Cervical squamous and glandular intraepithelial neoplasia: identification and current management approaches. *Salud Publica Mex.* 2003;45(3):417–29.
12. Wright VC, Shier RM. Colposcopy of adenocarcinoma in situ and adenocarcinoma – Differentiation from Other Cervical Lesions. and others, editor. Houston, Texas: Biomedical Communications; 2000.
13. Wright VC. Colposcopic features of cervical adenocarcinoma in situ and adenocarcinoma and management of preinvasive disease. In: Apgar B, Bronztman GL, Spitzer M, editors. *Colposcopy – Principles and practice.* Philadelphia: WB Saunders; 2001. p. 301–20.

### Author biography

**Priyanka Singh**, Associate Professor  <https://orcid.org/0000-0001-8636-8540>

**Cite this article:** Singh P. Colposcopic features of HPV associated adenocarcinoma usual type. *Indian J Obstet Gynecol Res* 2024;11(3):511-514.