

## Bi-directional barbed suture in laparoscopic myomectomy: a clinical study

Nagendra Prasad N<sup>1,\*</sup>, Sarojamma C<sup>2</sup>, Nagarathanamma R<sup>3</sup>, Savitha C<sup>4</sup>

<sup>1,2</sup>Associate Professor, <sup>3</sup>Professor & HOD, <sup>4</sup>Assistant Professor, Dept. of Obstetrics & Gynecology, Rajarajeshwari Medical College & Hospital, Bangalore

**\*Corresponding Author:**

Email: drnnprasad@yahoo.com

### Abstract

**Objective:** To evaluate efficacy and ease of use, of bidirectional barbed suture in laparoscopic myomectomy.

**Methods:** One hundred and twelve cases of laparoscopic myomectomy were performed by a single surgeon over five years period. Most of the cases were for management of infertility. A bidirectional barbed suture was used for myoma bed closure. Assessment was made about the ease of use of barbed suture, time taken to suture hysterotomy wound and intra operative blood loss.

**Results:** The operator found huge difference in the ease of use of bidirectional barbed suture in the closure of hysterotomy incision compared to intermittent suturing with intra corporal knotting, using conventional suture. Operative time as well as intra operative blood loss decreased with the use of barbed suture.

**Conclusion:** Bidirectional barbed suture is a safe and effective material to close the myomectomy incision. It greatly reduces the difficulty in endosuturing and hence allows more people to practice laparoscopic myomectomy. It also reduces the time required for endosuturing.

**Keywords:** Barbed suture, Laparoscopy, Myomectomy, Quill, Infertility

Access this article online	
<b>Quick Response Code:</b> 	<b>Website:</b> www.innovativepublication.com
	<b>DOI:</b> 10.5958/2394-2754.2016.00050.3

### Introduction

Earliest records of wound closure with suture material are found as far back as 5,000-3,000 BC<sup>1</sup>. Natural elements like flax, silk, linen and cotton were used as suture material<sup>2</sup>. Later use of sterilized catgut suture made of sheep intestine in 1907 and introduction of absorbable synthetic suture in 1970s are two major innovations in suture material<sup>3</sup>.

The development of synthetic polymers and fibers, made possible usage of synthetic sutures. These sutures can be engineered by polymer configuration, the type of fiber and its size, and surface lubricant, coating with antiseptic chemicals. Each of these suture types has specific usage, depending on the surgical site, technique and surgeons preference. The surgical sutures available now can be broadly classified as natural and synthetic. Again they can be sub classified as absorbable and non-absorbable.

For practical purposes, the 6 categories of suture classification believed to best assist surgeons in choosing the proper suture material for their surgeries are<sup>4</sup>:

- Suture size
- Tensile strength
- Absorbable versus non absorbable
- Multifilament versus monofilament

- Stiffness and flexibility
- Smooth versus barbed

Though there are considerable advances in suture materials, all of them need to be applied with surgical knot.

Surgical knots have the following drawbacks:


- Reduce tensile strength of the suture material by thinning and stretching it. Weakest point of a suture is the knot and second weakest point is point immediately adjacent to the knot<sup>2</sup>.
- Tying of surgical knot introduces potential human errors.
- Concern of knot slippage and hence over tightening is bad for wound healing, as localized hypoxia causes decreased fibroblast proliferation and leading to a weak scar<sup>5</sup>.
- The volume of surgical knot is directly related to the total amount of inflammatory reaction in surrounding tissue<sup>6</sup>.
- Laparoscopically tied knots are weaker than those tied by hand<sup>7</sup>.

Hence an ideal suture should eliminate the need for knotting. The myomectomy incision repair needs a suture that adequately addresses the need for an optimal wound closure, haemostasis, and minimal tissue reaction. The knot less barbed suture is a relatively new type of suture first used in 1967 by Dr. A.R. McKenzie in animal studies. Quill Medical Inc. (Angiotech Pharmaceuticals Vancouver, Canada) received the US FDA approval for the first bidirectional barbed polydioxanone suture in 2004.

### Barbed Suture

The bidirectional barbed suture created by Quill Medical, Inc. is made of monofilament polydioxanone. This suture then undergoes a process where tiny cuts are made in helical shape around the circumference, with a micro machine. These cuts result in the tiny barbs that change direction at the centre. The barbs are spaced between 0.88 mm to 0.98 mm apart. Two needles are swathed at either end of the thread. (Fig.1)

In unidirectional barbed suture the cuts in the suture are made in one direction hence resulting in the



**Fig. 1: Image of bidirectional barbed suture showing needles at ends, barbs and change of direction at midpoint**

barbs facing in one direction. A needle is swathed at one end and the other end has a tiny loop which is used to secure the suture at the beginning of suturing.

The barbs in the suture anchor the material at every barb approximately every one mm. As it is self-anchoring there is no need to knot the suture at the ends. The tensile strength is effectively distributed through-out the suture and thus eliminating the weak points created the knots and adjacent to the knots. This constant distribution of tension along the suture line allows it to possess greater breaking strength compared to conventional suture<sup>8</sup>. The scar tissue is reduced with the use of barbed suture, due to decreased foreign body reaction, as the knots are not required.

The Quill barbed sutures are rated in size before the barbs are cut, and are rated one size more the actual diameter. Hence a 1-0 barbed suture is equivalent to 2-0 conventional suture in diameter of the material<sup>9</sup>. The V-loc unidirectional barbed suture, the size corresponds to the conventional suture.

Wound approximation using either barbed or conventional smooth suture relies on the same principles, except the elimination of knots in barbed suture. In case of barbed suture the need to tie the knot is eliminated as the tiny barbs in the suture anchor the material in the tissue and resist from recoiling. While using bidirectional barbed suture for single layer closure, surgeon starts from the middle of the wound, pulls the material to its midpoint and runs through to lateral points, with respective direction needles. While closing

in two layers, one starts from one end, pull the suture till the midpoint and close the deeper layer with one needle, reach the other lateral point. Superficial layer is closed with the second needle running in the same direction.

Unidirectional barbed suture comes with a small loop at the free end to secure the suture at the beginning. The surgeon starts at the distal end, secure with the loop and runs through to the nearer end. The suture is continued back towards midline to ensure secure anchoring.

Today barbed sutures are used in almost all surgical fields for various indications. To name a few indications, the suture can be used in dermal tissue approximation, internal wound closure, and tendon repair etc. Use of barbed suture in laparoscopic procedures has increased in the past decade. The present study evaluates the efficacy of barbed suture in closure of myoma bed, in terms of ease of the procedure, time saved and decreased blood loss if any.

### Materials and Methods

It is a prospective observational study involving patients needing myomectomy for various indications mainly infertility. In the study period of January 2012 to June 2016, 112 patients underwent laparoscopic myomectomy. All the patients requiring laparoscopic myomectomy for various indications, mainly infertility were enrolled in the study. Written informed consent was obtained from all the patients included in the study.

Patients were evaluated pre-operatively, relevant investigations were done and surgical fitness was obtained. Ultrasonography was done to note the number and location of the fibroids. Haemoglobin was determined one day prior to surgery and 24 hours after the surgery. The difference between the haemoglobin concentrations in mg/dl was calculated to assess intra-operative blood loss.

Primary author was the surgeon who performed all the procedures. All procedures were completed laparoscopically, none were converted to laparotomy. The degree of surgical difficulty in suturing the hysterotomy incision was assessed by use of visual analog scale ranging from 1 (low difficulty) to 10 (high difficulty) as previously described by Vassiloseetal<sup>10</sup>. Other parameters assessed were the time needed for closure of myoma bed, total surgical time and intra-operative blood loss.

Patients were administered general or regional anaesthesia and placed in low lithotomy position. Pneuoperitoneum was created using Veress needle through the umbilicus and 10mm port was introduced for optics. 10mm 30° scope was used fitted with Karl Storz high definition camera for all the surgeries. Carbon-dioxide was used for insufflation and pressure was set at 12mm of Hg. Two lateral ports of 5mm were introduced on either iliac fosse under laparoscopic vision.

Twenty Units of vasopressin diluted in 200 ml of saline was instilled into the uterus, in the proximity of

fibroid, using an aspiration needle. Uterine incision was made with mono polar hook, appropriate to the location of myoma. Myoma was enucleated using 5mm myoma spiral by traction and counter traction with grasper. In case of multiple myomas tunnelling technique was used where possible. Few patients needed additional incision to remove distantly placed myomas.

Myoma bed was sutured with Quill no. 1 bidirectional barbed suture with 14x14 cms length and 30mm round body needle. Suturing was done mostly in two layers for intramural fibroids, with first needle closing the deeper layer and second needle closing the superficial layer. However after enucleating subserous fibroids incision was closed in single layer, starting from midpoint and each needle running laterally in opposite direction. (Image 2)

Myomas were removed using an electro mechanical morcellator. Haemostasis was confirmed, thorough peritoneal lavage was given. Adhesion barrier was not used in our study. After reducing the pneumo peritoneum the port sites were closed. Time taken from introduction of Veress needle to removal of trochars was noted as total surgical time. Also the time taken to suture the myoma bed was noted separately in all the cases. When there was more than one incision time taken for each individual incision was noted separately.

## Results

Most of the patients were in the age group of 25-30yrs (Table 1). Around 98%(110) of the patients were subjected to myomectomy for infertility. Only two patients in our study group underwent myomectomy of abnormal uterine bleeding. 34 patients were cases of primary infertility and 76 patients had previous conceptions. Most of patients had a single myoma (77) and highest no. of myomas removed in a patient was eight (Table 2).

**Table 1: Age distribution of the patients**

Age in years	No. of patients	Percentage
20 – 25 yrs	20	18%
25yrs 1 day – 30yrs	53	47%
30yrs 1 day – 35yrs	31	28%
35yr1day and above	8	7%

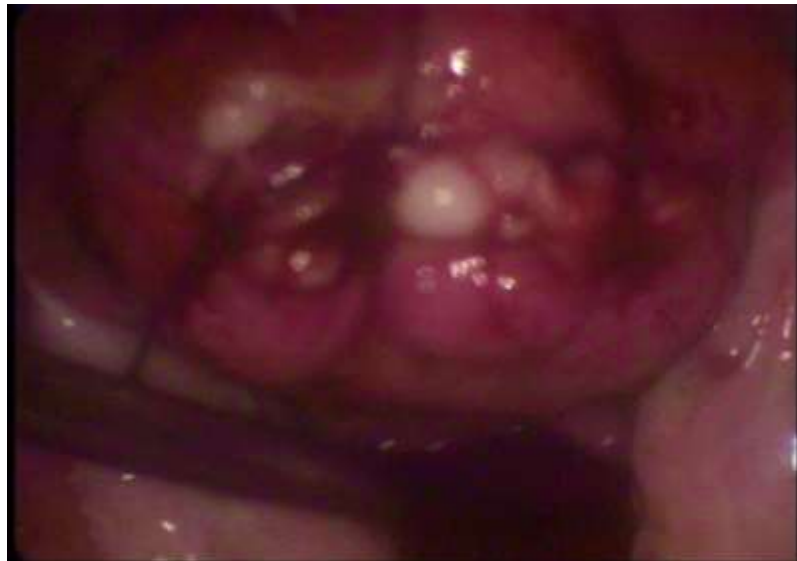**Table 2: Distribution of patients depending on no. of myomas**

No. of Myomas	No. of patients	Percentage
1	77	69.5%
2	16	14.5%
3	13	12%
4	4	3.5%
5 & above	2	1.5%

The operation time varied form 38-92 mins, but most of procedures were completed little above an hour duration. It was markedly quicker when compared to the time taken by the same surgeon before starting to use barbed suture. The time taken to suture the myoma incision varied from eight to sixteen minutes. Intra-operative blood loss was minimal, proven, with only a slight fall in the haemoglobin ranging between 0.28 – 0.48 g/dl. The visual analogue scale used to evaluate the degree of surgical difficulty showed a mean of 6 +/- 3.2 (3-9) (Table 3).

**Table 3: Operative parameters of the study**

Parameter	Mean +/- SD
Duration of surgery	66 +/- 18.4 (38 – 92) mins
Duration of myoma bed suturing	12 +/- 3.5 (8-16) mins
VAS Scale of difficulty in suturing	6 +/- 3.2 (3-9)
Drop of Haemoglobin	0.35 +/- 0.7 (0.28 – 0.48) mg/dl



**Fig. 2: Image showing the suture line after myoma bed closure with barbed suture**

### Discussion

Laparoscopic myomectomy is one of the commonly performed surgeries in gynaecology. Most of the patients in our study underwent myomectomy for infertility. Laparoscopic suturing either with intra corporeal or extra corporeal knotting needs skill and is difficult to master. It has a prolonged learning curve. Hence many techniques of intracorporeal knotting evolved to obtain safe and secure suture during laparoscopic myomectomy. The difficulty in tying of suture using laparoscopic instruments may even prevent some gynaecologist perform laparoscopic surgeries. Greenberg and Einarsson in 2000 were the first to report use of barbed suture in Gynaecologic surgery<sup>9</sup>.

Bidirectional barbed suture is a major technical advancement in the suture material which nullifies the need of knotting and hence makes laparoscopic suturing easy to perform. It also makes sure the tension on suture material is evenly distributed across the length of filament rather than at the knot. In vitro studies have proven barbed suture is superior to conventional suture material, in both tensile strength and wound holding capacity<sup>11</sup>.

In a study conducted by Roberto Angioli et al, significantly lower haemoglobin drop was found with barbed suture<sup>11</sup>. In our study the mean haemoglobin drop was  $0.35 \pm 0.7$  mg/dl. In the same study it was found that suturing time was significantly lower in barbed suture than in the conventional group ( $9.9 \pm 4.3$  vs.  $15.8 \pm 4.7$  mins). In our study the duration of myoma bed suturing  $12 \pm 3.5$  mins.

In our study 112 patients underwent laparoscopic myomectomy. We found bidirectional barbed suture can be safely and effectively used in closure of myoma bed. The wound approximation obtained with barbed suture, either in single layer or double layer was satisfactory. Studies suggest that barbed suture significantly shortens

the suture time in laparoscopic myomectomy as well as other surgeries<sup>13</sup> as observed in our study.

There was no intra op or immediate post-op complications in our study. The patients were discharged on the next day after surgery. The patients were followed up in outpatient department after six weeks and none of them reported any adverse events. In a study reported by Mario Adrovino et al, they found at three months, six months, 12 months and 18 months follow up after surgery there were no wound dehiscence, no bleeding and no other potential major complications. They also found the integrity of the uterine wall closure and fertility outcome after myomectomy with barbed suture were similar to conventional suture material<sup>14</sup>.

When using newer, barbed sutures, many surgeons are initially skeptical with regard to the strength of the knotless, barbed suture lines as compared with traditional knotted, smooth suture lines. The conventional sutures lose tensile strength at and around the knots, the barbed suture, which is knotless, is not subject to this problem<sup>4</sup>. The common indications for bi directional barbed suture in gynaecology today are myomectomy, vaginal cuff closure after total laparoscopic hysterectomy, sacro spinous fixation, tuboplasty and others.

In this study we have not directly compared the barbed suture with conventional suture. However there are published studies which have compared the conventional suture with barbed suture and found to reduce the myoma bed suturing time significantly. (Table 4)

**Table 4: Comparison of time taken to suture myomectomy incision in different studies**

Study	Conventional suture	Barbed suture	p-value
Franco Alessandri et al 2010	17.4 +/- 3.8 mins	11.5 +/- 3.8 mins	< 0.001
Ji Einarsson et al 2011	272.6 seconds	126.5 seconds	< 0.001
Roberto Angioli et al 2012	15.8 +/- 4.7 mins	9.9 +/- 4.3 mins	= 0.0004
Mario Adrovino et al 2013	12.2 +/- 6.8 mins	6.6 +/- 4.7 mins	< 0.001
Present study	NA	12 +/- 3.5 mins	NA

## Conclusion

Bidirectional barbed suture is a safe and effective material to close the myomectomy incision. It achieves better wound approximation compared to conventional interrupted suture. It greatly reduces the difficulty in endosuturing and hence allows more people to practice laparoscopic myomectomy. The integrity of the myomectomy scar and future obstetric outcome can be evaluated in randomised controlled studies to establish the superiority of barbed suture over conventional suture.

## References

1. Kug. M.W. Overview of opportunities within medical textiles. Canadian Textile Journal. 2001 July/August: 118/4:34-36.
2. Chu. C.C, J.A. Von Fraunhof, and H.P. Grieder. Wound Closure Biomaterials and Devices. Boca Raton, FL-CRC Press, 1997:122.
3. Dietz U.A., Kehl F., Hanedman. W., and Weisser. C (2007) on the 100th anniversary of Sterile Catgut: Fauzkuhn (1886 – 1929) and Epistemology of Catgut Sterilization. World J Surg, 31(12),2275–2283.
4. James A. Greenberg, MD: The Use of Barbed Sutures in Obstetrics and Gynecology: Rev Obstet Gynecol. 2010;3(3):82-91.
5. Hashemi L, Hart S, Morseon M. Comparison of Surgery Time and Cost in using Barbed Suture versus the Traditional suture in Robotic Hysterectomy: A retrospective cohort study. J Minim Invasive Gynec. 2012;19 (SUPPL): S6.
6. Miran M.E., Marsh C, Pesrotti M. Bidirectional Barbed Suture Knotless Running Anastomosis Vs Classical Van Velthoven Suturing in a model system. J Endourol. 2007;21:1175-1178.
7. Kadiramanathan SS, Shelton JC, Hepworthe CC et al, A Comparison of Study of Knots Tied by Hand and at Laparoscopy. J Am Coll Surg 1996;182:46-54.
8. Rashid RM, Sartori M, White LE, Villa MT, Yoo SS, Alam M. Breaking strength of polypropylene sutures: rater blinded controlled comparison with non-barbed sutures of various calibers. Arch Dermatol. 2007;143:869-872.
9. Greenberg JA, Einarson JI. The Use of Bidirectional barbed suture in laparoscopic myomectomy and TLH. J Mimin invasive Gynecol.2008;15:621-623.
10. Vassiliose MC, Feldman LS, Andrew CG et al. A Global Assessment Tool for Evaluation of Intra Operative Laparoscopy Skills. Am J Surg 2005;190:107-113.

11. Leung JC. Barbed Suture Technology: Recent Advances in Medical Textiles. 2004 October:2627:62-80.
12. Angioli R, Plotti F, Montera R, Damiani P, Terranova C, Oronzi I, Luvero D, Scaletta G, Muzii L, Panici PB. A new type of absorbable barbed suture for using Laparoscopic Myomectomy. Int J Gynecol Obstet 2012 June;117(3):220-223.
13. Tulandi T, Einarson JI. The use of Barbed Suture for Laparoscopic Hysterectomy and Myomectomy: A Review and Meta-analysis J Mimin invasive Gynecol.2008;21:210-216.
14. Mario Adrovino, Mario Antonietta Cistaldi, Fernando Fraternali, Italoardovino, Nicola Colacora, Giuseppe Signoriello and Lucicobellus. Bidirectional Barbed Sutures in Lap Myomectomy: Clinical Features, J of Laparo Endoscopic and Adv surg Technique. Vol23, 2013:1002-1010.