

## Isolated Congenital Megacystitis (ICM): A rare case report

Ramesh Babu<sup>1</sup>, Mahendra G<sup>2</sup>, Vindhyashree S<sup>3,\*</sup>

<sup>1,2</sup>Associate Professor, <sup>3</sup>PG Student, Adichunchanagiri Institute of Medical Sciences, BG Nagar

**\*Corresponding Author:**

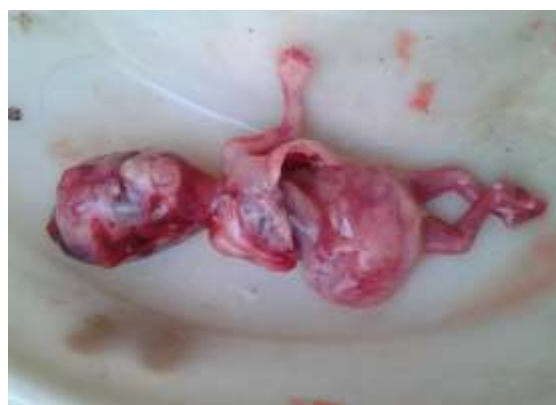Email: vindhya0025@gmail.com

### Abstract

Isolated congenital Megacystitis represents a rare variant of fetal Megacystitis without other associated anomalies. The aetiology is not clear. Various methods of management have been described in literature. We report a case of isolated congenital Megacystitis. Considerations for the evaluation and management of this rare entity are discussed.

**Keywords:** Megacystitis, Congenital, Hydronephrosis, Case report

Access this article online	
Quick Response Code:	Website: www.innovativepublication.com
	DOI: 10.5958/2394-2754.2016.00066.7

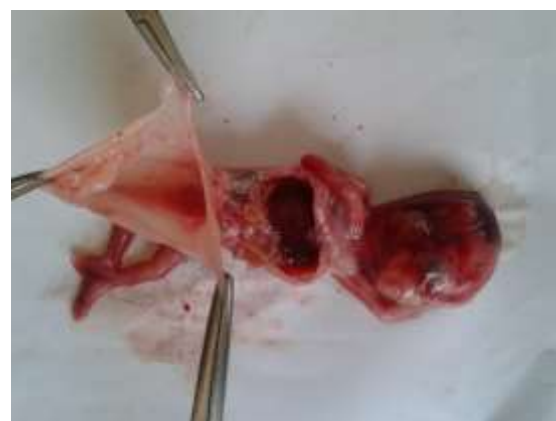

**Fig. 1: Aborted foetus of ICM**

### Introduction

Foetal Megacystitis, incidence being 1:1 500 occurring in the first trimester may already be a sign of congenital malformation. Often, urethral valves are causally responsible in male foetuses far more frequently than urethral atresia. Further the "prune-belly syndrome" needs to be distinguished. Far more difficult to classify prenatally is the rare MMIHS which, in contrast to the diagnosis of urethral valves, is associated with an unfavourable prognosis<sup>(13)</sup>.

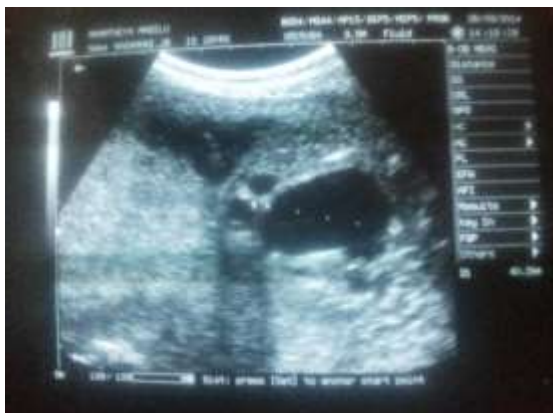Isolated congenital Megacystitis (ICM) is an extremely rare condition of unclear etiology. Postulated pathologic mechanisms include a visceral myopathy<sup>(1)</sup> and a mild variant of Megacystitis-microcolon-intestinal hypoperistalsis syndrome (MMIHS).<sup>(2)</sup> Since the condition is rare the optimal strategy for management is not clear and less, with previous authors reporting reduction cystoplasty<sup>(3)</sup> and clean intermittent catheterization (CIC)<sup>(2,4)</sup> as two options. Here, we report a case of ICM that is terminated after routine anomaly scan.



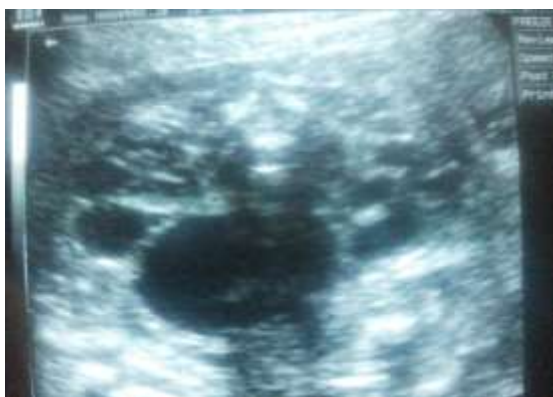
**Fig. 2: Dissected view of ICM**

### Case Report

Primigravida with 20 weeks gestation came for regular Anomaly scan and had been diagnosed to be having isolated congenital megacystitis and patient has been explained about the risk and option for termination. She opted for termination and below are the pictures of ICM.



**Fig. 3: USG of ICM**



**Fig. 4: Showing ICM on USG**

### Discussion

Megacystitis is defined as a fetal bladder larger than 6–8mm in longitudinal diameter, and the prevalence of fetal Megacystitis at 10–14 weeks of gestation is approximately 1:1500 pregnancies.<sup>[5]</sup> If Megacystitis is detected on prenatal ultrasound, important differential diagnoses to consider include PUV, PBS, urethral atresia, and anterior urethral valves. Congenital Megacystitis has also been found in association with MMHIS,<sup>[6,7]</sup> anorectal malformations,<sup>[8]</sup> and transverse sinus thrombosis.<sup>[4]</sup>

When abnormal bladder enlargement is found on fetal ultrasound, prenatal counselling is challenging because it is often difficult to discriminate between ICM and Megacystitis in the context of a related syndrome such as MMHIS based on ultrasound alone. The outcomes of conditions related to Megacystitis such as MMHIS are generally poor.<sup>[6,7,9,10]</sup> In addition, ICM to have a favourable prognosis compared with Megacystitis contained within the context of a larger syndrome.<sup>[2–4]</sup> Parents can thus be presented with the range of possibilities based on the prenatal ultrasound, but exact prognosis is nearly impossible. Increased renal echogenicity has been highly associated with obstructive etiologies of bladder distension,<sup>[11]</sup> so an initial attempt at stratification can be made based on that ultrasonographic parameter.

When Megacystitis is present and other associated conditions have been excluded, patients are classified as having ICM. This abnormality is an extremely rare condition that may actually be a constellation of several divergent etiologies. Previous reports have postulated various underlying mechanisms including spontaneous resolution of a congenital urethral stricture,<sup>[12]</sup> visceral myopathy<sup>[1]</sup> and a variant of MMHIS.<sup>[2]</sup> In some cases no clear etiology can be identified, as was the situation with our patient.

Determining the prognosis and management recommendations for patients with isolated Megacystitis is challenging. Previous reports have discussed the use of reduction cystoplasty<sup>[3]</sup> and CIC<sup>[2,4]</sup> for the management of this condition; both strategies resulted in favourable clinical outcomes. Our report highlights a case where conservative management of Megacystitis with serial imaging and prophylactic antibiotics was a successful alternative strategy.

### Conclusion

ICM is a rare condition that may represent a collection of several divergent etiologies. In most reported cases, this condition does not resolve spontaneously. Prognosis appears to be favourable regardless of management strategy.

### References

1. Perk H, Serel TA, Anafarta K, Kosar A, Uluoglu O, Sari A. Megacystitis secondary to myenteric plexus pathology. Presentation of two cases. *Urol Int.* 2001;67:313–315. [PubMed]
2. Shimizu M, Nishio S, Ueno K, Yokoyama T, Sakai S, Nagaoki S, et al. Isolated congenital Megacystitis without intestinal obstruction: a mild variant of chronic intestinal pseudoobstruction syndrome? *J Pediatr Surg.* 2011;46:e29–e32. [PubMed]
3. Inamdar S, Mallouh C, Ganguly R. Vesical gigantism or congenital Megacystitis. *Urology.* 1984;24:601–603. [PubMed]
4. Cavoretto P, Lesma A, Spagnolo D, Valsecchi L, Negretto A, Candiani M. Prenatal sonographic monitoring of idiopathic Megacystitis. *J Clin Ultrasound.* 2011 [PubMed]
5. Sebire NJ, Von Kaisenberg C, Rubio C, Snijders RJ, Nicolaides KH. Fetal Megacystitis at 10–14 weeks of gestation. *Ultrasound Obstet Gynecol.* 1996;8:387–390. [PubMed]
6. Berdon WE, Baker DH, Blanc WA, Gay B, Santulli TV, Donovan C. Megacystitis-microcolon-intestinal hypoperistalsis syndrome: a new cause of intestinal obstruction in the newborn. Report of radiologic findings in five newborn girls. *AJR Am J Roentgenol.* 1976;126:957–964. [PubMed]
7. Lashley DB, Masliah E, Kaplan GW, McAleer IM. Megacystitis microcolon intestinal hypoperistalsis syndrome: bladder distension and pyelectasis in the fetus without anatomic outflow obstruction. *Urology.* 2000;55:774. [PubMed]
8. Chen CP, Wang W, Lin SP, Sheu JC, Tsai JD. Perinatal findings in a male fetus with congenital Megacystitis and anorectal malformations. *Fetal Diagn Ther.* 1998;13:348–351. [PubMed]

9. Jouannic JM, Hyett JA, Pandya PP, Gulbis B, Rodeck CH, Jauniaux E. Perinatal outcome in fetuses with Megacystitis in the first half of pregnancy. *Prenat Diagn.* 2003;23:340–344. [PubMed]
10. Witters I, Theyskens C, van Hoestenbergh R, Sieprath P, Gyselaers W, Fryns JP. Prenatal diagnosis of non-obstructive Megacystitis as part of the Megacystitis-microcolon-intestinal hypoperistalsis syndrome with favourable postnatal outcome. *Prenat Diagn.* 2001;21:704–706. [PubMed]
11. Kaefer M, Peters CA, Retik AB, Benacerraf BB. Increased renal echogenicity: a sonographic sign for differentiating between obstructive and non-obstructive etiologies of in utero bladder distension. *J Urol.* 1997;158:1026–1029. [PubMed]
12. Alizadeh M, Hamedanchi S, Azar AT, Bukani HM. Megacystitis secondary to congenital urethral stricture. *J Pediatr Urol.* 2011;7:488–490. [PubMed]
13. Hellmeyer et al; Megacystitis-microcolon intestinal hypoperistalsis syndrome (MMIHS) as a rare differential diagnosis of foetal Megacystitis on ultrasonography; *Z Geburtshilfe Neonatol.* 2013 Feb;217(1):35-7. doi: 10.1055/s-0032-1333255. Epub 2013 Feb 25.