

Herlyn- Werner- Wunderlich syndrome: Case report of a rare congenital mullerian anomaly

Rupita Kulshrestha^{1,*}, Pankaj Singh², Krishna Gopal Paul³, Deepti Verma⁴

^{1,4}Assistant Professor, ²Associate Professor, ³Professor, Dept. of Obstetrics & Gynecology, Mayo Institute of Medical Sciences, Barabanki, Lucknow

***Corresponding Author:**

Email: rupita.kulshrestha@gmail.com

Abstract

Herlyn –Wener- Wunderlich Syndrome is a rare congenital mullerian anomaly. It consists of uterus didelphys, obstructed hemivagina, and ipsilateral renal agenesis. It is also called OHVIRA (Obstructed Hemivagina with Ipsilateral Renal Agenesis) Syndrome. Few case reports are mentioned earlier which have conservatively managed the case with the resection of vaginal septum. Failure of this procedure in our case led us to do an extensive abdominal surgery involving resection of uterine septum followed by unification of both uterine horns.

Keywords: HWW syndrome, OHVIRA syndrome, Mullerian anomaly, Hematometocolpos, Hematosalpinx.

Introduction

Approximately 7% of girls will have an anatomic abnormality in their reproductive tract, diagnosed before or after puberty.⁽¹⁾ Incidence of uterus didelphys is estimated to be 5%.⁽²⁾ Herlyn-Werner-Wunderlich (HWW) syndrome is an uncommon variant of Müllerian duct anomalies, consisting of uterus didelphys, obstructed hemivagina, and ipsilateral renal agenesis. It is also called OHVIRA (Obstructed Hemivagina with Ipsilateral Renal Agenesis) Syndrome. It usually presents in a post-pubertal adolescent or adult woman in whom hematometocolpos produces a pronounced mass effect and pain on the side of the obstructed hemivagina.⁽³⁾ The true incidence of this anomaly is unknown, but it has been reported between 0.1% and 3.8%.⁽³⁾ The exact cause and pathogenesis is uncertain; however, the diagnosis and treatment at an early stage can relieve acute symptoms and preserve normal fertility.⁽⁴⁾

Case Report

Patient was a fourteen year's old unmarried girl presenting to Out Patient Department with chief complaints of dysmenorrhoea since menarche. She had menarche 2 years back. She also complained of a lump in lower abdomen becoming more prominent and painful in last 2 months, accompanied with difficulty in micturition and defecation during menses. She is having menses for 6-7 days every 40- 45 days. CA 125 was slightly raised (48.9 mIU/ml). Other haematological investigations were within normal limits.

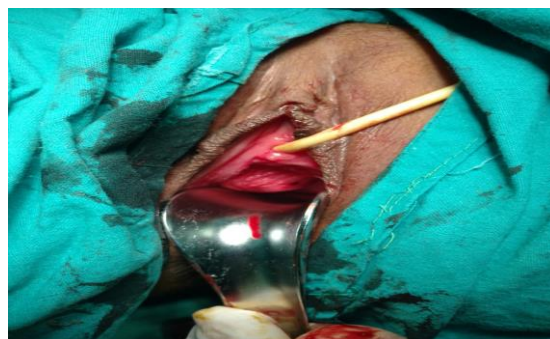


Fig. 1: Examination under anaesthesia showing bulge on right side of vagina

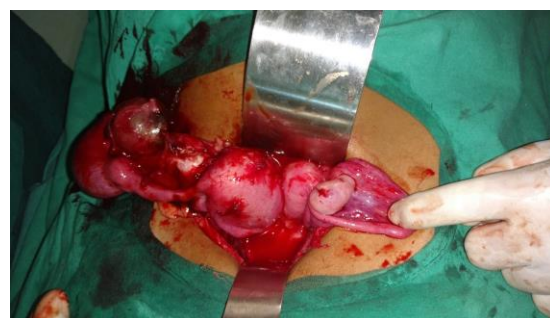

Fig. 2: Intraoperative photograph demonstrating right sided hematosalpinx, right ovary (normal) and distended right uterine horn. The left uterine horn, ovary and fallopian tube are normal

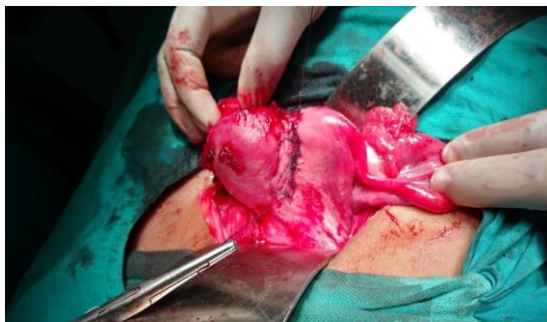

Fig. 3: Right sided salpingectomy followed by unification of both the uterine horns. The left fallopian tube and ovary are seen normal

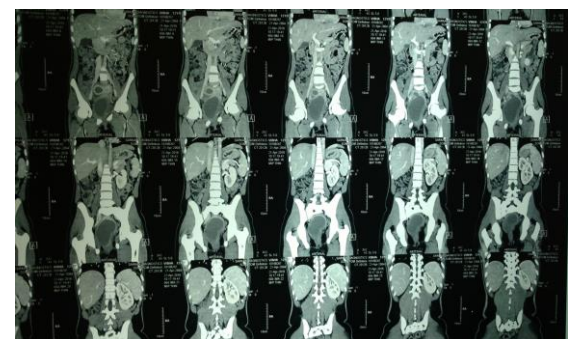
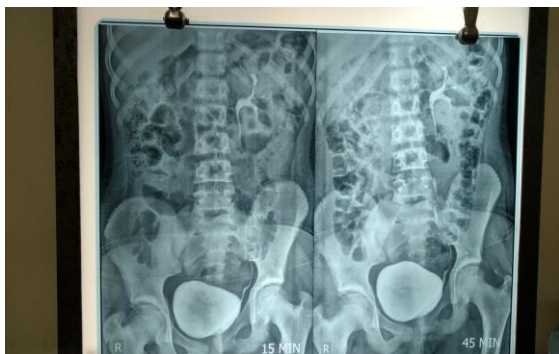

Fig. 4: CT image showing absent right kidney and presence of hematometrocolpos

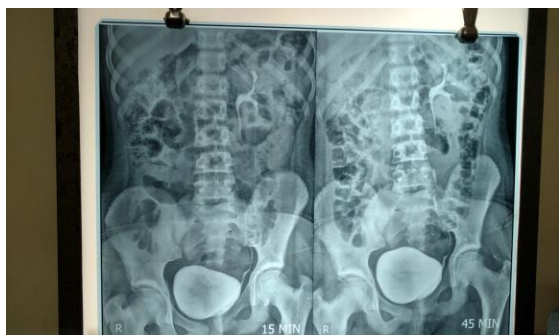

Fig. 5: IVP image showing absence of right kidney and ureter

Investigations

USG -Non visualised right kidney, uterus, cervix and vagina seen having fluid collection hematometra

with hematocolpos with debris measuring 11 cm x 5.7 cm.

CT- uterus didelphys with non-communicating right cervix and haematometra at right cervix and right uterine horn, Agenesis of right kidney.

IVP-Left sided kidney & ureter normal. Non visualisation of contrast on right side even upto 6 hrs.

Examination

1. Per abdomen -Irregular lump in suprapubic region & right iliac fossa, oblong in shape, 12cm x7cm in size, firm in consistency, mobile in transverse direction and not mobile in vertical direction.
2. Local examination- Secondary sexual characters well developed, adrenarche & thelarche - Tanner's stage III.

The patient was planned for examination under general anaesthesia(EUA)

3. Per speculum examination - Right sided vaginal wall had diffuse bulging which was obstructing the view of vault. Left sided vaginal wall was normal.
4. Per vaginam examination -Large diffuse cystic bulge was present on right side. Its margins could not be made out. Consistency of the bulge was firm extending upto vault. The upper limit could not be reached. Rugosity was present on the vaginal mucosa over the bulge. The right fornix could not be felt. Left vaginal wall normal with normal rugosities and absence of any bulge. Cervix was felt with difficulty as a small pit on left side of vault.

5. Double speculum examination- Small sized cervix was seen at vault stretched towards left side. Cervix was held with long allies forceps, sounding was done. Uterine sound could be passed easily through os upto 4 cm.

With wide bore needle (16 G) bulge was punctured at the point of maximum bulge in the right side and approx 40 ml of thick, dark, tarry coloured altered blood was aspirated followed by a resection of septa at the same site. Hematometra drained yielding about 400 ml of dark altered blood. After drainage bulge was reduced significantly.

6. Per rectal examination - A firm bulge was present anteriorly more towards right side, its upper margin could not be reached. No bulge was felt on the left side. Rectal mucosa was free from the mass.

Patient had uneventful postoperative period she was discharged and was called for regular followup after menses. Patient did not comply and came after 3 months in our emergency with acute abdomen. This time patient had one lump in right iliac fossa which was oblong in shape, about 5x5cm in size, soft in consistency, mobile vertically, not mobile in transverse direction. There was no lump in suprapubic region. USG revealed right sided adnexal mass 11cmx 5 cm in size, no evidence of bowel perforation Laparotomy was planned. Uterus was having two horns. Right sided uterine horn was enlarged and there was 13 cm x5 cm

right sided haematosalpinx. The right ovary was normal. On left side uterine horn, fallopian tube & ovary was normal. Right sided salpingectomy was done. Uterine horns were incised near septa, dark, tarry coloured, thick blood measuring 500 ml was aspirated, septa was resected. Thin metallic dilators were passed in the cavities of both the uterine horns. The left sided dilator appeared in the vagina but the right sided dilator did not. It was felt behind the vaginal septum. Resection of vaginal septum was done. After septum resection sounding was done on right side suggesting presence of rudimentary cervix which was excised. Further, unification of both the uterine horns was done. A 10 F Foleys catheter was placed through the resected vaginal septum on right side and it was kept for 14 days. Patient had uneventful postoperative stay and was discharged.

Discussion

Mullerian (paramesonephric) duct anomalies are congenital anomalies of the female genital tract which result from non-development or non-fusion of the mullerian ducts or failed resorption of the uterine septum during the sixth to ninth weeks of fetal life causing a wide-ranging series of reproductive ducts malformations.⁽⁴⁾

The paramesonephric ducts of the genetically female embryo fuse together in the midline and form the uterus, cervix and the upper four-fifths of the vagina. The lower 20% of the vagina are formed from sinovaginal bulbs which are protrusions of the urogenital sinus.⁽⁴⁾ The urinary and genital systems arise from a common ridge of mesoderm arising along the dorsal body wall and rely on normal development of the mesonephric system. Hence, abnormal differentiation of the mesonephric and paramesonephric ducts may also be associated with anomalies of the kidneys.⁽⁴⁾ Renal agenesis is the most common anomaly although horseshoe or pelvic kidney, cystic renal dysplasia, duplication of the collecting system and ectopic ureters have all been described. Renal agenesis is predictive of an ipsilateral obstructive Mullerian anomaly greater than 50% of the time. These anomalies have a right-sided dominance, twice as often as on the left side.⁽⁴⁾

The association of renal agenesis with unilateral blind hemivagina was reported as Herlyn-Werner syndrome in 1971, whereas the association of renal aplasia, bicornuate uterus with isolated hematocervix, and a simple vagina was reported by Wunderlich in 1976. This syndrome is a rare variant within the spectrum of mullerian duct anomalies. It is also known as OHVIRA (obstructed hemivagina with ipsilateral renal anomaly) syndrome. HWW Syndrome may represent a failure of vertical and lateral fusion of mullerian structures.⁽⁵⁾

HWWS be classified according to the complete or incomplete obstruction of the hemivagina as follows⁽⁶⁾

Classification 1, Completely obstructed hemivagina

Classification 1.1, With blind hemivagina

Classification 1.2, Cervicovaginal atresia without communicating uteri

Classification 2, Incompletely obstructed hemivagina

Classification 2.1, Partial reabsorption of the vaginal septum.

Classification 2.2, With communicating uteri

This new classification of HWWS can help to provide clinicians with earlier diagnosis and treatments to prevent secondary pelvic endometriosis and pelvic inflammation.⁽⁶⁾

According to this classification our patient belongs to classification 1.1.

Resection of the vaginal septum is the treatment of choice for obstructive hemivagina.^(4,5,8,9) It can be made by abdominal approach through a Pfannenstiel incision.⁽⁵⁾ or laparoscopy or by trans-hymenal approach.⁽⁵⁾ Patients with this syndrome after treatment can have normal sexual relations and fertility is not compromised, though the spontaneous abortion rate is as high as 40%.⁽⁵⁾

Excision followed by marsupialisation is also mentioned as a management approach⁽⁷⁾ which causes symptomatic relief and preserves reproductive potential.

Resection of vaginal septum is mentioned as the treatment of choice which was done in first sitting in our case also. However, in due course of time the resected vaginal septum got closed spontaneously and the patient presented with acute abdomen (cause hematosalpinx).

As no follow up was mentioned in previous case reports, we planned for an extensive surgery involving uterine and cervical septum removal followed by unification of both the uterine horns. Follow up of the patient was done after 6 months. She had normal menses and was completely asymptomatic till then.

The authors recommend further studies to decide the appropriate management of such rare cases. Based on this case report we recommend resorting to extensive surgery if conservative management by vaginal septum resection fails.

HWW syndrome is a rare condition and should be suspected in any post pubertal girl presenting with acute abdomen with abdominal/suprapubic lump, gradually increasing dysmenorrhoea and/or urinary retention. It may present in young female babies age < 3 years.⁽⁵⁾ Early diagnosis is only possible with awareness and high degree of suspicion for this rare entity. The treatment should be individualised according to the case and patient should be followed up regularly to assess the success of the treatment. Abdominal surgery should be resorted to wherever needed.

Acknowledgement: None

Disclosure: None

References

1. Dietrich JE, Millar DM, Quint EH. Obstructive reproductive tract anomalies. *J Pediatr Adolesc Gynecol*. 2014 Dec;27(6):396-402.
2. Fatum M, Rojansky N, Shushan A. Septate uterus with cervical duplication: rethinking the development of mullerian anomalies. *Gynecol Obstet Invest* 2003;55:186-88.
3. Karaca L, Pirimoglu B, Bayraktutan U, Ogul H, Oral A, Kantarci M. Herlyn-Werner-Wunderlich syndrome: a very rare urogenital anomaly in a teenage girl. *J Emerg Med*. 2015 Mar;48(3):e73-5.
4. Ana Cristina Aveiro, Victor Miranda, António Jorge Cabral, Sidónia Nunes, Filomeno Paulo, and Conceição Freitas Herlyn–Werner–Wunderlich syndrome: a rare cause of pelvic pain in adolescent girls4.*BMJ Case Rep*. 2011;2011:41-47.
5. R. Angotti, F. Molinaro, A.L. Bulotta, E. Bindi, E. Cerchia, M. Sica, M. Messina Case report Herlyn–Werner–Wunderlich syndrome: An “early” onset case report and review of Literature *International Journal of Surgery Case Reports* Volume 11,2015, Pages 59–63.
6. Lan Zhu, Na Chen, Jia-Li Tong, Wei Wang, Lei Zhang, Jing-He Lang. *Chinese Medical Journal*. New Classification of Herlyn-Werner-Wunderlich Syndrome,2015,128(2):222-225.
7. Candiani GB, Fedele L, Candiani M. Double uterus, blind hemivagina, and ipsilateral renal agenesis: 36 cases and long-term follow-up *Obstet Gynecol*. 1997 Jul;90(1):26-32.
8. Ashu Rastogi and Anshu Khamesra. *Indian Journal of Pediatrics*, 2010 Aug 77:917.
9. Gungor Ugurlucan F, Bastu E, Gulsen G, Kurek Eken M, Akhan SE. OHVIRA syndrome presenting with acute abdomen: a case report and review of the literature. 2014 May-Jun;38(3):357-9.
10. Katabathina VS, Katre R, Prasad SR et-al. Wunderlich syndrome: cross-sectional imaging review. *J Comput Assist Tomogr*. 35(4):425-33.